



Analysis of ultrastructural morphometric changes of pigeon kidneys affected by colibacteriosis

Kolomak I.O.¹, Berdnyk V.P.¹, Kyrychko O.B.¹, *Nedosekov V.V.²

¹Department of Normal and Pathological Anatomy and Physiology of Animals, Poltava State Agrarian Academy, Poltava, Ukraine. kolomak-ihor@ukr.net, berdnyk36@gmail.com, kyrychko.elena@ukr.net

²Department of Epizootology and Veterinary Business Organization, National university of life and environmental sciences of Ukraine, Kyiv, Ukraine. nedosekov06@gmail.com

***Corresponding author:**

V.V. Nedosekov, Department of Epizootology and Veterinary Business Organization, National university of life and environmental sciences of Ukraine, Kyiv, Ukraine. nedosekov06@gmail.com

Abstract

The article provides data on the morphometric changes in the kidneys of pigeons with *colibacteriosis*. Patho-morphological examination of the kidneys revealed focal hyperemia of the kidney cortical area and edema of the loose fibrous tissue. The convoluted renal tubule epitheliocytes were enlarged in size. In this case, the tubules

get narrow and become slit-shaped. The convoluted tubules epithelium showed signs of granular dystrophy. In the chronic course of *colibacteriosis*, granuloma formation and signs of chronic interstitial nephritis were observed, in which the loose connective tissue of the cortical area is replaced by fibrous tissue. Morphometric analysis revealed that in the experimental group there was a decrease in the nephrocyte diameter ($p = <0.05$) to $98.06 \pm 0.46 \mu\text{m}$ and the nephrocyte area to $6319.38 \pm 9.62 \mu\text{m}^2$. This results in a significant reduction ($p = <0.05$) of the sub-capsular space to $11.14 \pm 0.16 \mu\text{m}$ compared to the control group. The distal and proximal convoluted tubules diameter also decreased to $127.43 \pm 20.78 \mu\text{m}$ and $39.50 \pm 1.63 \mu\text{m}$, respectively. Accordingly, the area of the distal and proximal convoluted tubules decreased significantly ($p = <0.05$) to $10164.10 \pm 0.43 \mu\text{m}^2$ and $2974.43 \pm 4.01 \mu\text{m}^2$, respectively. The patho-genetic effect of *E. coli* toxins revealed the renal tubular obstruction and slowing of the reabsorption and urinary excretion processes resulting in a reduction of glomerular filtration capacity of the kidney. Due to the prolonged course of salmonellosis occurring during the latent course, the area of renal filtration was also reduced. Accumulation of nitrogen metabolism products that enter the bloodstream caused impaired water-salt metabolism and acid-base equilibrium.

Keywords: morphometry; patho-morphology; renal; kidney; nephrocyte; avian; pigeons; colibacteriosis; histo-morphology.

Introduction and general considerations

In the spectrum of farm animals and poultry infectious pathology, colibacteriosis was observed as the highest degree of damage in birds [1, 2]. The studies started prior to the establishment of the wild birds' microbial status, began in the early 19th century and did not lose their relevance today. Thus, bacterial study of wild pigeons in Austria, Russia and the Czech Republic revealed the presence of *Salmonella*, *E. coli*, *Chlamydia*, *Mycobacterium*, *Cryptococcus*, *Campylobacter* species [3]. Similar studies were carried out in Santiago, and identified *Salmonella* species belonging to sero-groups B and D, *E. coli*, *Haemoproteus columbae*, *Plasmodium* species, *Columbicola columbae* and *Campanulotes bidentatus*, Tetramer species and *Capillaria annulata* [4]. Similar data were also obtained in Brazil, Japan and Malaysia, where *Chlamydia* species, *Salmonella* species and *E. coli* were isolated in pigeons. Studies of colibacteriosis spread

in Ukraine [5,6] and Russia [7] also indicated a significant spread of the disease throughout the territory.

Among infectious diseases, colibacteriosis played a key role, since the *E. coli* bacterium can be acted both as a mono-infection and a poly-infection. There was also a version that *E. coli* played a key role in the immunity breakthrough and in the creation of gates for further development of the infectious process. As a result, the secondary microflora was over-placed. Among infectious diseases of chickens, colibacteriosis was the most common causing death in 80% of cases. Contact with wild synanthropic birds and disturbance of the birds keeping conditions was considered to be the main etiological factor. Literature sources described pathomorphological changes in chickens that differ from the disease course form. Thus, in the acute form, the corpses were of medium fatness with developed catarrhal or haemorrhagic enteritis. It was characterized by spot hemorrhages on the intestinal mucosa. Pathology of the cardiovascular system developed, resulting in blood filling of the internal organs (spleen, liver and kidneys). The respiratory form of the disease was most commonly described. Respiratory tract pathologies developed with aerogenic (contact) type of infection. Colibacteriosis was characterized by the development of aerosacculitis and hemorrhagic tracheitis. Colibacteriosis was more frequently manifested as an intestinal form, manifested by enteritis and hepatitis. However, the latent form was found in 50% of the diseased birds, in which pericarditis, synovitis, osteomyelitis develops. In adult birds salpingitis, ovaritis and yolk peritonitis [7–10] were found. Pathological and anatomical changes in farm animals with colibacteriosis have received extensive coverage in the literature viz., in poultry [11], rabbit [12], donkey [13], broiler chicken [14], human and calves [15]. However, research works focused on the study of synanthropic birds, in particular pigeons, which play a key role in the spread of colibacteriosis in cities, were of a single nature. Patho-morphological studies performed one of the key functions in differential diagnostics [16,17]. Applying modern morphometric measuring instruments, a clear range of patho-morphological changes can be established, which permits to perform statistical analysis [18]. Therefore, in our study, we have focused on the study of patho-morphological

changes, including morphometric measurements to deeply understand the biological processes that occur in the pigeon kidneys under the influence of *E. coli* enterotoxins. The obtained data will provide and update the general studies on differential diagnosis in colibacteriosis, namely during the latent course.

Material and methods

Animals and sample collection: The study was carried out at the scientific laboratory of the Department of Normal and Pathological Anatomy and Animal Physiology of the Poltava State Agrarian Academy. The results were confirmed at the Regional State Veterinary Laboratory in the Poltava region, which was accredited in compliance with the requirements of DSTU ISO / IEC 17025: 2006 (ISO / IEC 17025: 2005). Determination of the nosological profile in the incidence of the pigeon population was carried out by bacteriological studies on wild pigeons (*Columba livia* var. *Domestica*) selected in Poltava (n= 50). Blood from the heart, liver, kidney, spleen, swabs from the gastrointestinal tract were sampled for bacterial inoculation.

Laboratory methodology: Patho-morphological examination was performed to establish pathologic anatomical and histological changes in organs and tissues. Selection of material for histological examination was performed during patho-anatomical incision. The autopsy was performed according to the conventional pattern of poultry dissection (Shore method). Organ and tissue pieces were sizing no more than 1 cm³. Subsequently they were embedded in paraffin. The sections were made by means of MC-2 type sliding microtome and were 5–10 µm thick. Staining was performed with hematoxylin and eosin, stained histological sections were studied with a microscope. The illustration material was depicted using the “MICROmed” microscope and 3 Mpix microscope attachment.

Ethical statement: In the course of the experimental studies on birds, the bioethical requirements for animals complying with the “European Convention for the Protection of Vertebrate Animals Used for Experimental and Scientific Purposes” (Strasbourg, 1986) and the First National Congress on Bioethics (Kyiv, 2001), Law of Ukraine “On Protection of Animals from Cruelty” dated 28.03.2006 were followed.

Results

Pathomorphological examination of the kidneys in pigeons with colibac-teriosis (experimental group) revealed that in all cases of the disease at the macroscopic level, the kidneys were hyperaemic, the renal artery was blood-filled. The section showed the cortical, intermediate and medullar areas, the image was not smoothed, the borders were clearly traced.

Microscopic examination revealed oedema of the loose fibrous tissue in the renal cortical area, in such areas focal hyperaemia was developed. The renal tubules and loose fibrous tissue infiltration by lymphocytic cells was recorded. In some areas, the high density of cell infiltrates did not permit to trace them histologically. This indicated an acute course of the inflammatory process. The convoluted tubules' epitheliocytes were observed as enlarged in size, protruding into the lumen of the tubules. In this case, the tubules got narrow and become slit-like (Figures 1–2). In large areas of the organ, the epithelium of the convoluted tubules has shown signs of granular dystrophy (Figure 1). Separate sites specifically attributed to nephrocytes necrosis were recorded. In this case, the contours of the nephrocytes' apical portion were not traced, the cells were enlarged in size, and look as shapeless mass. In such areas, the intercellular walls of nephrocytes and their nuclei were difficult to differentiate, paranecrosis and necrosis were occasionally reported.

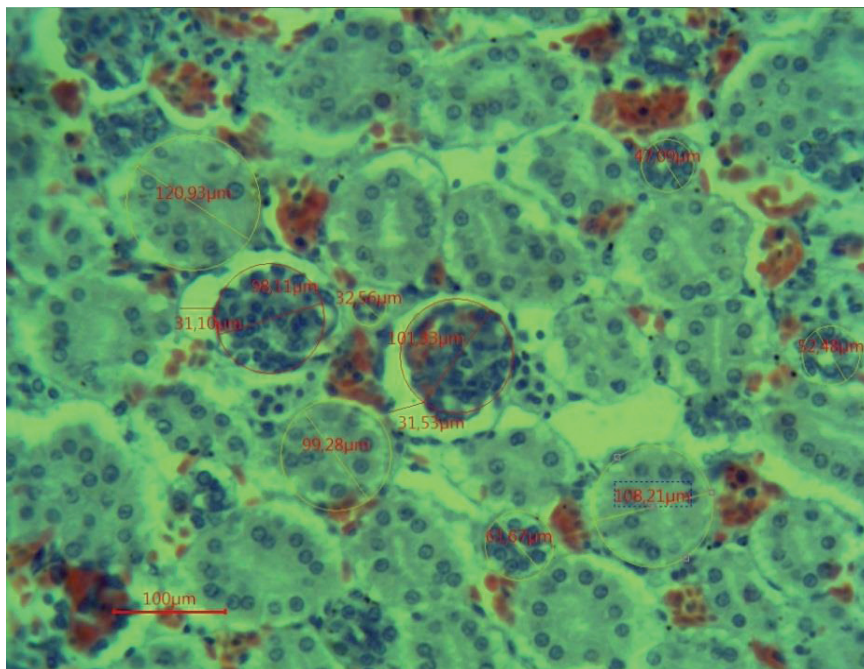


Figure 1. The figure presents histomorphological changes of pigeon kidneys in colibacteriosis. Morphological changes occurring in the kidney medulla nephrons and in the proximal convoluted tubules are shown. Hematoxylin-eosin staining, $\times 640$

In the chronic course of colibacteriosis, granulomas with a size exceeding the size of the vascular glomerulus were reported. In addition, signs of chronic interstitial nephritis were reported in which the loose connective tissue of the cortical area was replaced by fibrous tissue. In cases of granuloma formation, the vascular response was less pronounced. Hemosiderin formation was registered in blood vessels with pronounced blood filling (Figure 2), which indicated a longer hemodynamic disorder in such areas of the organ. Such areas were characterized by an increased volume of nephrocytes, which was due to an increase in the area of the cytoplasm and nucleus. The nucleus was located in the center of the cell, the karyoplasm was light-coloured.

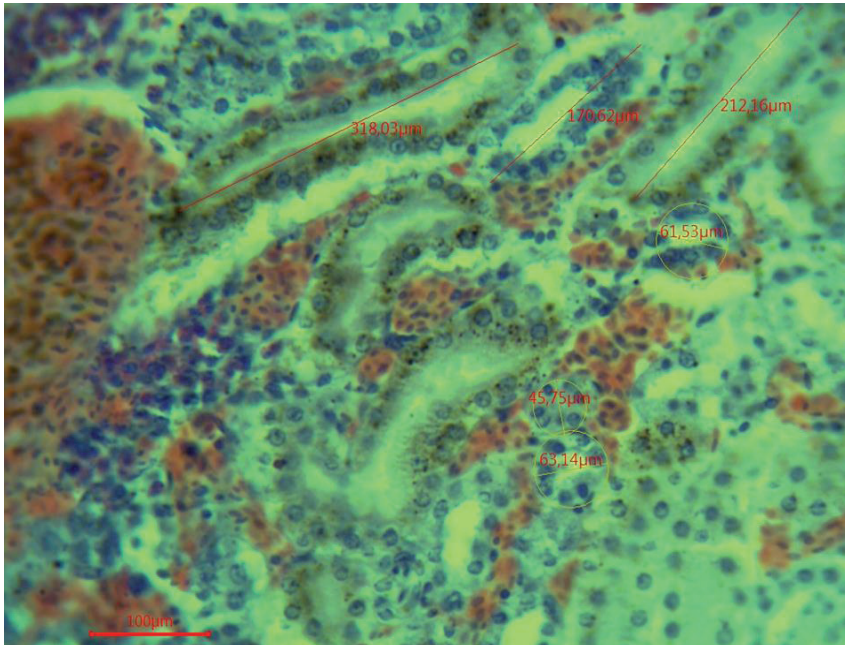


Figure 2. The figure presents histomorphological changes of pigeon kidneys in colibacteriosis. The blood filling of the kidney's cortical layer vessels is shown; in these areas increased vessels cutting and lymphocytic infiltration occur. In such areas, an increase in distal convoluted tubules was noted. Hematoxylin-eosin staining, $\times 640$

In the epithelium cytoplasm of the convoluted tubules located on the periphery of the above sites, hemosiderin granules were registered, having in some cases a diffuse location, and in others occurring in the form of conglomerates. Due to the uneven concentration of the pigment in the nephrocytes' cytoplasm, the colour of such conglomerates varies from light red to dark brown. In cases of cell destruction, hemosiderin granules were located around the tubule perimeter. In the sites of infiltration and the vessels blood-filling, the organ stroma's oedema was definitive. In addition, the formation of hemosiderin occurred in the lumen of the blood vessels. It should be noted that formation of hemosiderin in blood vessels was not in all cases accompanied by formation of cell infiltrates and

reabsorption by hemosiderin nephrocytes. The areas where hemosiderin deposition occurred in the cytoplasm of nephrocytes located in the sites of the vessels focal blood filling in the peritubular capillary network were traced.

Table 1. Morphometric parameters of ultrastructural changes of pigeon kidneys in colibacteriosis

Name	Experimental group	Control group
Nephrocyte diameter, μm	98.06 \pm 0.46	103.39 \pm 0.86
Distal convoluted tubule's diameter, μm	127.43 \pm 20.78	98.06 \pm 0.46
Proximal convoluted tubule's diameter, μm	39.50 \pm 1.63	64.87 \pm 0.71
Nephrocyte's area, μm^2	6319.38 \pm 9.62	6240.72 \pm 3.46
Distal convoluted tubule's area, μm^2	10164.10 \pm 0.43	12952.54 \pm 0.55
Proximal convoluted tubule's area, μm^2	2974.43 \pm 4.01	6093.18 \pm 0.30
Subcapsular distance, μm	37.62 \pm 1.82	11.14 \pm 0.16

Morphometric analysis revealed that in the experimental group the diameter of the nephrocytes were significantly ($p = <0.05$) reduced to $98.06 \pm 0.46 \mu\text{m}$ compared to the control group – $103.39 \pm 0.86 \mu\text{m}$. The area of the nephrocytes and the distal and proximal convoluted tubules were significantly reduced ($p = <0.05$) $6319.38 \pm 9.62, \mu\text{m}^2$ compared to the control group – $6240.72 \pm 3.46, \mu\text{m}^2$. Due to this, there was a reliable reduction ($p = <0.05$) of the subcapsular space to $11.14 \pm 0.16, \mu\text{m}$ compared to the control – $37.62 \pm 1.82, \mu\text{m}$.

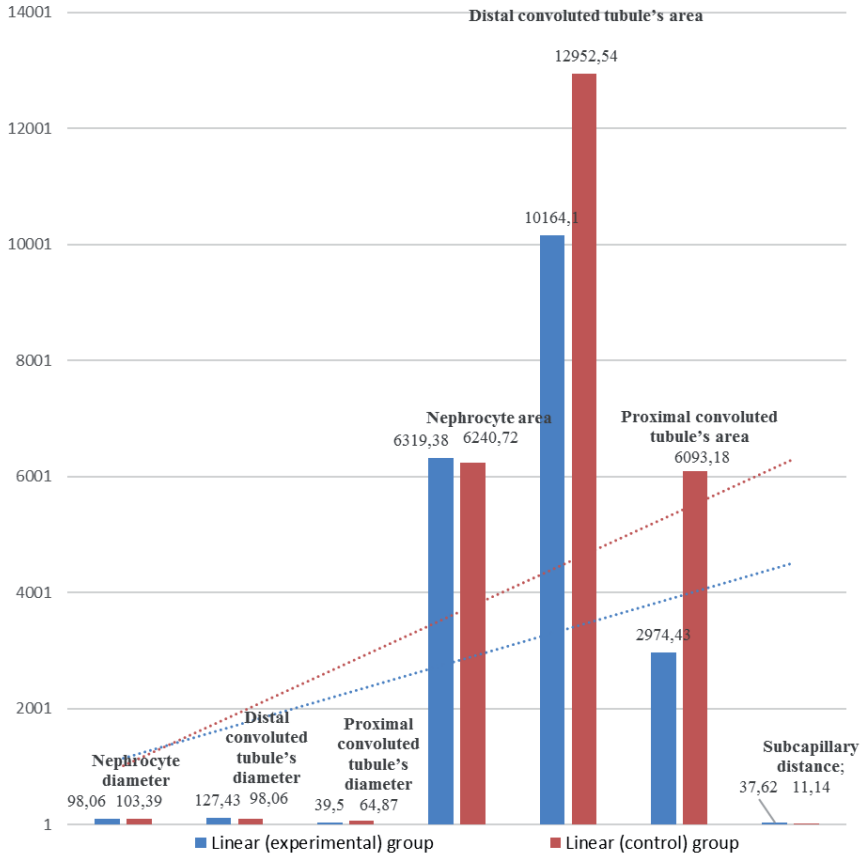


Figure 3. The diagram presents the results of morphometric changes in the kidney's structural elements. The two groups of experimental pigeons were compared: pigeons with colibacteriosis and the controls

Changes also occur in the system of convoluted tubules. The diameters of the distal convoluted tubule and the proximal convoluted tubule were also reduced significantly ($p < 0.05$) to 127.43 ± 20.78 , 39.50 ± 1.63 , respectively, as compared to the control group having 98.06 ± 0.46 and 64.87 ± 0.71 , respectively. Accordingly, the areas of the distal convoluted tubule and the proximal convoluted tubule were reliably reduced

($p = <0.05$) to 10164.10 ± 0.43 and 2974.43 ± 4.01 , respectively. The pathogenic effect of *E. coli* resulted in reduction of glomerular filtration volume (Figure 3), obturator of a large number of tubules, inhibition of secretion, excretion and reabsorption processes. Since the filtration area in the kidneys got reduced, the products of nitrogen metabolism were retained and accumulated in the blood and, because of this, hyperazotemia, impairments of water-salt metabolism and acid-alkaline balance were developed.

Discussions

Information on the colibacteriosis study is constantly being deepened and supplemented with new data. Thus, it is known from the literature that the intestinal form of the disease with an acute course and lesions in the gastrointestinal tract is the most common in birds [19]. However, lately, articular, nervous and latent forms were increasingly reported, and differential diagnosis was becoming more complicated. Therefore, researchers were actively studying all organs and systems for the differential diagnosis of colibacteriosis.

In addition to pigeons, the study of renal pathologies in colibacteriosis was also performed on birds [19]. The main pathomorphological data correspond to those in the acute course during which blood filling of organs and necrotic processes in the kidneys and the liver occur.

The obtained general pathomorphological data in our studies were similar to the results obtained by other authors [5,16,18,19], however, information about the morphometric analysis in pigeons with colibacteriosis was new and not studied before. In addition, the pigeons under study were found to have a chronic course, during which coli granulomatous formations were formed at different stages of development. This indicates a long course of pathological process that occurs in the latent form. Most researchers [4,5] studying the pathogenesis of colibacteriosis maintain that it was in the latent form of the disease course that wild birds pose a particular danger to sinantropic animals, because they acted as a reservoir host. Therefore, by performing morphometric diagnostics

and comparing it to the obtained data, it might be possible to perform differential diagnosis of colibacteriosis in pigeons.

Conclusions

In pigeons diseased with colibacteriosis, regardless of the course form, the kidney damage occurred. In pigeons with a chronic course, formation of coli granulomas, replacement of interstitial tissue with fibrous tissue and deposition of hemosiderin were observed. Morphometric studies have shown that pigeon diseased with colibacteriosis have a reduction in the nephrocyte diameter ($p < 0.05$) to $98.06 \pm 0.46 \mu\text{m}$ and in the nephrocyte area to $6319.38 \pm 9.62 \mu\text{m}$. This results in a significant reduction ($p < 0.05$) of the subcapsular space to $11.14 \pm 0.16 \mu\text{m}$ compared to the control group. The distal and proximal convoluted tubules diameter also reduced to $127.43 \pm 20.78 \mu\text{m}$ and $39.50 \pm 1.63 \mu\text{m}$, respectively. Accordingly, the area of the distal and proximal convoluted tubules has reduced significantly ($p < 0.05$) to $10164.10 \pm 0.43 \mu\text{m}$ and $2974.43 \pm 4.01 \mu\text{m}$, respectively. Reduction of the kidney ultrastructural components under the effect of toxins causes development of hyperazotemia, impaired water-salt metabolism and acid-alkaline balance.

Acknowledgment. The work is a fragment of the PSAA research project “Pathomorphological manifestation features of pigeon bacteriosis in urbanized cities”, state registration No. 0116U008727.

References

- [1] Nedosekov V. Infectious animal pathology: problems and prospects. Earth Bioresources and Life Quality. 2012;1. <http://gchera-ejournal.nubip.edu.ua/index.php/ebql/article/view/14>.
- [2] Nedosekov V., Gomzykov O. Biological properties of salmonella isolated from chickens in Ukraine farms. Earth Bioresources and Life Quality. 2013;3. <http://gchera-ejournal.nubip.edu.ua/index.php/ebql/article/view/108/pdf>.

- [3] Konicek C., Vodrážka P., Barták P., Knotek Z., Hess C., Račka K., Hess M., Troxler S. Detection of zoonotic pathogens in wild birds in the cross-border region Austria, Czech Republic. *J Wild Dis.* 2016;52:850–861.
- [4] Toro H., Saucedo C., Borie C., Gough R. E. and Alcaino H. Health status of free-living pigeons in the city of Santiago. *Avian Pathol.* 1999;28:619–623.
- [5] Muzyka D., Pantin-Jackwood M., Stegnyy B., Rula O., Bolotin V., Stegnyy A., Gerilovych A., Shutchenko P., Stegnyy M., Koshelev V., Maiorova K., Tkachenko S., Muzyka N., Usova L., Afonso C.L. Wild bird surveillance for avian paramyxoviruses in the Azov-black sea region of Ukraine (2006 to 2011) reveals epidemiological connections with Europe and Africa. *Appl Environ Microbiol.* 2014;80:5427–5438.
- [6] Gargiulo A., Fioretti A., Russo T.P., Varriale L., Rampa L., Paone S., De Luca Bossa L.M., Raia P., Dipineto L. Occurrence of enteropathogenic bacteria in birds of prey in Italy. *Lett Appl Microbiol.* 2018;66:202–206.
- [7] Belozherov E., Kiseleva L., Midlenko V., Kuzmina A., Romanenko S., Reznikova E. Infectious diseases and biological safety problems. *Ulyanovsk Medical Biological Journal.* 2016;3:8–15.
- [8] Carver S., Kilpatrick M., Kuenzi A., Douglass R., Ostfeld R., Weinsteine P. Environmental monitoring to enhance comprehension and control of infectious diseases. *The Royal Society of Chemistry.* 2010;12:2048–2055.
- [9] Kumar A., Bhalerao D., Gupta R.P., Kumari M. Pathological studies on natural cases of avian colibacillosis in Haryana state. *Haryana Vet.* 2013;52:118–120.
- [10] Rahman M.A., Samad M.A., Rahman M.B., Kabir S.M.L. Bacterio-pathological Studies on Salmonellosis, Colibacillosis and Pasteurellosis in Natural and Experimental Infections in Chickens. *Avian Medicine.* 2004;1:1–8.
- [11] Wernicki A., Nowaczek A., Urban-Chmiel R. Bacteriophage therapy to combat bacterial infections in poultry. *Virol J.* 2017;14:179.
- [12] Kupczyński R., Szumny A., Bednarski M., Piasecki T., Śpitalniak-Bajerska K., Roman A. Application of Pontentilla Anserine, Polygonum aviculare and Rumex Crispus Mixture Extracts in A Rabbit Model with Experimentally Induced E. coli Infection. *Animals (Basel)* 2019; 9:774.
- [13] Zakari O.F., Ayo J.O., Rekwot P.I., Kawu M.U. Effect of age, sex, physical activity and meteorological factors on haematological parameters of donkeys (*Equus asinus*). *Comp Clin Path.* 2016;25:1265–1272.

- [14] Sharma V., Jakhar K.K., Nehra V., Kumar S. Biochemical studies in experimentally *Escherichia coli* infected broiler chicken supplemented with neem (*Azadirachta indica*) leaf extract. *Vet World*. 2015; 8:1340–1345.
- [15] Kolenda R., Burdukiewicz M., Schierack P. A systematic review and meta-analysis of the epidemiology of pathogenic *Escherichia coli* of calves and the role of calves as reservoirs for human pathogenic *E. coli*. *Front Cell Infect Microbiol*. 2015;5: 23.
- [16] Abalaka S.E., Sani N.A., Idoko I.S., Tenuche O.Z., Oyelowo F.O., Ejeh S.A., Enem S.I. Pathological changes associated with an outbreak of colibacillosis in a commercial broiler flock. *Sokoto Journal of Veterinary Sciences*. 2017;15:95–102.
- [17] Mitsyk A.V. Using ImageJ for automatic morphometry in histological examinations. *Omsk Scientific Journal of Information Technologies*. 2011;100:187–189.
- [18] Malish N.G., Chemich M.D., Kovalenko O.I. Modern features of the epidemic process of salmonellosis. *Infectious diseases*. 2013;4:30–35.
- [19] Shestakov V.A., Lysko S.B. Histostructural changes in the liver and kidneys are induced by esherihiosis. *Veterinary Journal*. 2015;73:19–22.