

ZDZIEBŁO, Katarzyna, ŁAPIŃSKA, Urszula, MACHAŁA-ĆWIKŁA, Ewelina, ZDZIEBŁO, Piotr, ĆWIKŁA, Piotr, ZDZIEBŁO, Anna, BIENIASZ, Anna, MACHAŁA, Dominika and MACHAŁA, Kamila. Fatigue fracture of the second rib in a professional athlete. *Quality in Sport*. 2024;17:52924. eISSN 2450-3118.
<https://dx.doi.org/10.12775/QS.2024.17.52924>
<https://apcz.umk.pl/QS/article/view/52924>

The journal has been 20 points in the Ministry of Higher Education and Science of Poland parametric evaluation. Annex to the announcement of the Minister of Higher Education and Science of 05.01.2024. No. 32553.

Has a Journal's Unique Identifier: 201398. Scientific disciplines assigned: Economics and finance (Field of social sciences); Management and Quality Sciences (Field of social sciences).

Punkty Ministerialne z 2019 - aktualny rok 20 punktów. Załącznik do komunikatu Ministra Szkolnictwa Wyższego i Nauki z dnia 05.01.2024 r. Lp. 32553. Posiada Unikatowy Identyfikator Czasopisma: 201398.

Przypisane dyscypliny naukowe: Ekonomia i finanse (Dziedzina nauk społecznych); Nauki o zarządzaniu i jakości (Dziedzina nauk społecznych).

© The Authors 2024;

This article is published with open access at Licensee Open Journal Systems of Nicolaus Copernicus University in Torun, Poland

Open Access. This article is distributed under the terms of the Creative Commons Attribution Noncommercial License which permits any noncommercial use, distribution, and reproduction in any medium, provided the original author (s) and source are credited. This is an open access article licensed under the terms of the Creative Commons Attribution Non commercial license Share alike. (<http://creativecommons.org/licenses/by-nc-sa/4.0/>) which permits unrestricted, non commercial use, distribution and reproduction in any medium, provided the work is properly cited.

The authors declare that there is no conflict of interests regarding the publication of this paper.

Received: 28.06.2024. Revised: 16.07.2024. Accepted: 16.07.2024. Published: 17.07.2024.

Fatigue fracture of the second rib in a professional athlete

Katarzyna Zdziebło¹, Urszula Łapińska², Ewelina Machała-Ćwikła³, Piotr Zdziebło⁴,
Piotr Ćwikła⁵, Anna Zdziebło⁶, Anna Bieniasz⁷, Dominika Machała⁸, Kamila Machała⁹

¹ Medical Doctor, Specialist Hospital of Edmund Biernacki in Mielec, Żeromskiego 22, 39-300 Mielec, Poland.

<https://orcid.org/0009-0005-7070-2491>; kasiadzdz@op.pl

² Medical Dentistry Doctor, Wrocław Medical University, Faculty of dentistry, wyb. Ludwika Pasteura 1, 50-367 Wrocław, Poland.

<https://orcid.org/0009-0000-5363-5112>; drurszulalapinska@gmail.com

³ Medical Doctor, University of Rzeszów, College of Medical Sciences, al. Rejtana 16c, 35-959 Rzeszów, Poland.

<https://orcid.org/0009-0005-1678-3534>; ew.machala@gmail.com

⁴ Medical Dentistry Doctor, Medical University of Lublin, Faculty of dentistry, al. Raławickie, 120-059 Lublin, Poland.

<https://orcid.org/0009-0000-9291-8406>; piotrzdzieblo@op.pl

⁵ Medical Doctor, Independent Public Healthcare Centre in Leżajsk, Psychiatric Ward, ul. Leśna 22, 37-300 Leżajsk, Poland.

<https://orcid.org/0009-0000-9854-1574>; ptr.cwikla@gmail.com

⁶ Student, University of Rzeszów, College of Medical Sciences, al. Rejtana 16c, 35-959 Rzeszów, Poland.

<https://orcid.org/0009-0008-8018-8993>; ania.zdzieblo@onet.pl

⁷ Student, Jagiellonian University Medical College, ul. Świętej Anny 12, 31-008 Kraków, Poland.

<https://orcid.org/0009-0005-9680-4015>; aabieniasz@gmail.com

⁸ Student, University of Rzeszów, College of Medical Sciences, al. Rejtana 16c, 35-959 Rzeszów, Poland.

<https://orcid.org/0009-0007-2064-1293>; dmachala1999@gmail.com

⁹ Student, University of Rzeszów, College of Medical Sciences, al. Rejtana 16c, 35-959 Rzeszów, Poland.

<https://orcid.org/0009-0003-7908-0831>; kamilamachala@gmail.com

Abstract:

A fatigue fracture, also known as stress fracture or overuse fracture, is caused by the summation of micro-injuries resulting from a chronic state of bone overload. It affects 1.4 %-4.4 % of professional athletes. The most common site of fatigue fractures are the lower limbs. This is related to the heavy load caused by body weight and performing dynamic activities like jumping, running. Typical fractures are fractures of the fifth metatarsal bone, fibula and tibia, and less common fractures of the femur. Fractures involving the bones of the upper limbs and thorax are less commonly reported in the literature. It affect athletes in strength sports and athletes who perform dynamic and repetitive movements with their upper limbs, most often boxers, weightlifters, wrestlers, judokas, swimmers, golfers, rowers. Fractures in the thorax most often involve the first rib. Fractures of ribs II through XII are extremely rarely described.

We present an unusual case of a second rib fracture in a professional athlete. A 26-year-old athlete training in racewalking reported increasing pain in the left scapula area 7 days before competing in the European Championships. Immediately after the competition, the pain changed location to the anterior thorax area, making movement of the upper limb and breathing much more difficult. A chest tomography was performed and it revealed a fatigue fracture of the second rib on the left side.

The case report presents an atypical fracture in a female racewalking athlete and presents the uncharacteristic symptoms accompanying this fracture. Incorrect initial diagnosis and application of physiotherapy procedures without performing basic diagnostic tests, delay the diagnosis and initiation of proper treatment, and thus the athlete's recovery.

Keywords: fatigue fracture, micro-injuries, rib

Introduction:

The mechanism of fatigue fracture formation involves an imbalance between bone formation and osteolysis resulting from bone micro-injuries. They are the result of bones being pulled at the point of attachment of muscle tendons doing excessive work. [1- 2]

Typically, thoracic fractures involve the first rib. In the group of shot-putters studied, 75 % of cases localize at the attachment site of the medial oblique muscle, 12 % at the subclavian artery groove, while 12 % localize at the rib-vertebral joint. There is a hypothesis explaining the mechanism of fracture formation as a result of the opposing action of the medial oblique and anterior dentate muscles on the first rib. [3] The mechanism of fractures in the lower ribs, most commonly VII- IX, is due to the opposing action of the external oblique and anterior dentate muscles. [4- 5]

Non-modifiable risk factors for fatigue fractures include family history, previous fractures, genetic predisposition, and Caucasian race. [6-7] Modifiable factors include the type of sport practiced, disturbances in the kinetic chain and energy transfer in the chain (lower limbs- core- upper limbs) and increased training intensity.

Deficiencies in iron, vitamin C, potassium, calcium and low levels of vitamin D3 and estrogen increase the risk of fatigue fractures. [8- 9]

Relative energy deficiency in sports (RED-S) is the medical term for an insufficient supply of energy relative to its expenditure and it is an important risk factor for fatigue fractures. An incorrect energy balance contributes to immune disorders, slower recovery and hormonal disorders. Among women, it often manifests itself in the absence of menstruation due to low

estrogen levels, with a consequent decrease in IGF-1 levels and bone formation markers. [9-11]

Treatment of fatigue fractures requires cessation of physical activity for about 6-8 weeks. [12]

CASE REPORT

Patient information

The 26-year-old patient is the medalist at the World Championships in the 25 km and 35 km racewalking.

During the onset of pain symptoms, she was preparing for her next start this season at the European Championships.

At 7 days before the competition, she did her last interval training. She did not do strength training. The next day, she complained of a stabbing, hard-to-locate pain in the area of her left shoulder blade, radiating along her upper limb. The pain worsened during physical effort. The critical moment turned out to be the start of a 20- kilometer racewalking competition. The athlete, after crossing the finish line, could not move the upper limb and make twisting movements of the torso. She had difficulty with speaking and breathing and complained of significant pain when she tried to cough. A few hours after the start, the pain changed in character to a more dull, diffuse, and stronger, and was localized to the left side of the thorax and shoulder girdle. The patient reported that the nature and location of the initially occurring, stabbing pain in the left shoulder region has been familiar to her. Six months earlier, she experienced similar ailments that disappeared after a few days without implementing medical intervention.

Medical History

She is a sportswoman with no history of fractures and no treatment for other diseases. There is a family history of osteoporosis suffered by her grandmother. There was secondary absence of menstruation for about 4 months.

Serum free calcium, iron, vitamin D levels are normal. There occur reduced estrogen levels. She weighs 50 kg with a height of 162 cm. There was no change in diet. For about three weeks before the injury, she had noted a decline in her desire to train, related to the prolonged start period. Physiological parameters including HRV and resting heart rate remained unchanged.

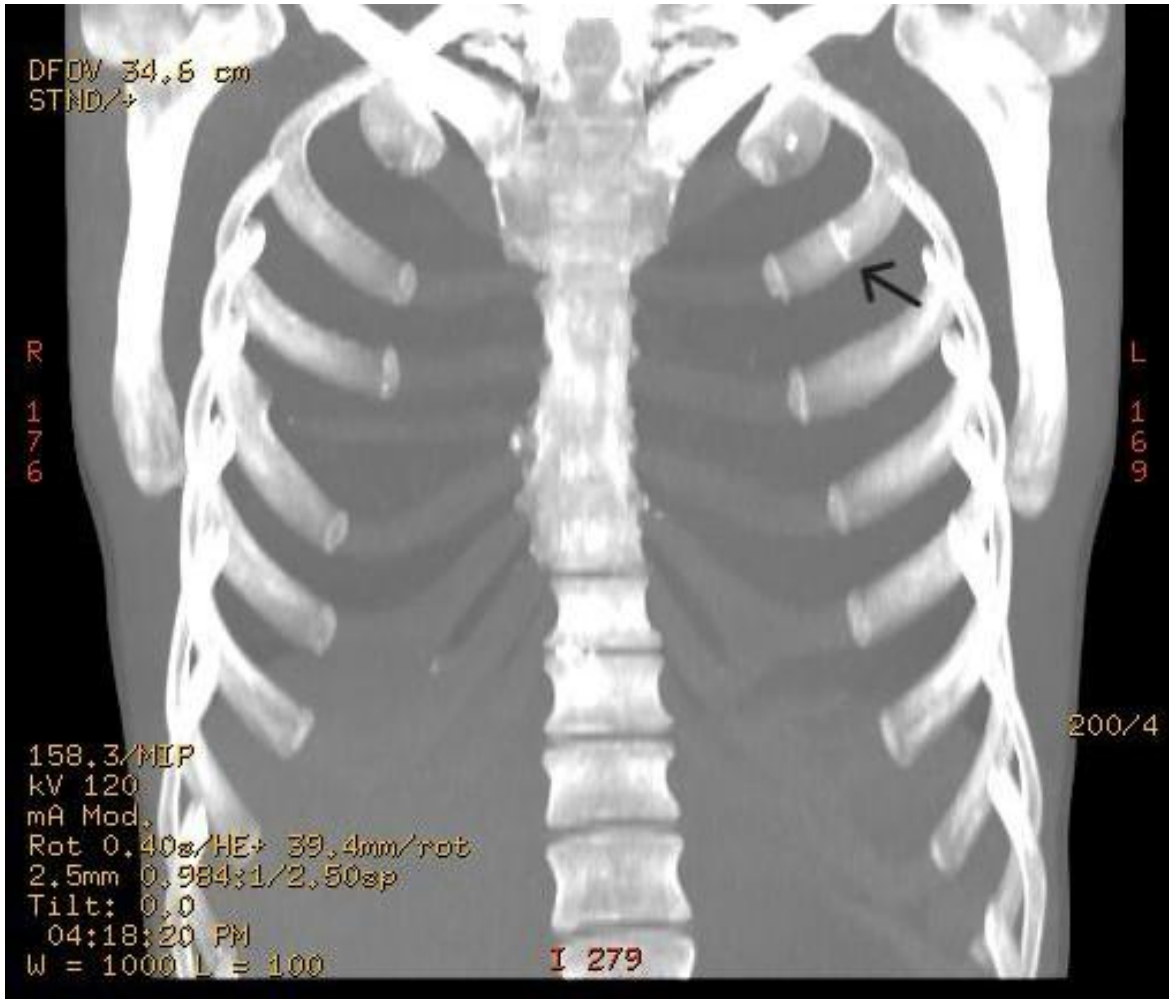
Clinical findings

During a physical examination performed by an orthopedic doctor five days before the athlete's start, the pain was classified as neurogenic due to pressure on the nerve roots. A visit to a physiotherapist was recommended, who performed manipulation of the thoracic spine.

Diagnosis

After returning from the competition, the athlete again had an orthopedic consultation. A thorax tomography was ordered, which showed a fatigue fracture of the second rib in the mid-clavicular line on the left side. (Figure 1)

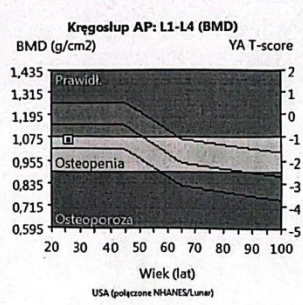
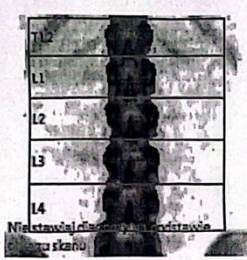
Figure 1. The black arrow indicates the location of the fracture



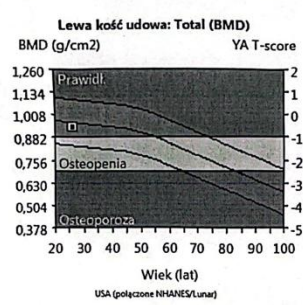
Bone densitometry was ordered. (Figure 2).

Figure 2. Gender- and age-appropriate results.

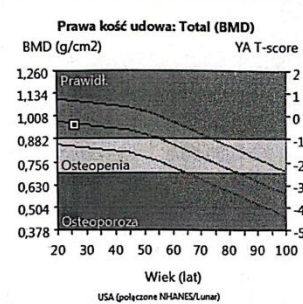
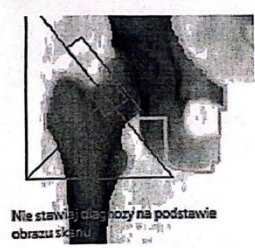Pacjent:
Data urodzenia: [redacted] **Wiek:** 25,9 lat(a)
Wzrost: 162,0 cm **Waga:** 51,7 kg
Płeć: Kobieta **Rasa:** Biała **Leżykujący:** (nie określono)
PESEL: [redacted]
Zmierzone: 14/11/2022 17:19:30 (17 [SP 4])
Analizowane: 14/11/2022 17:22:24 (17 [SP 4])



Region	BMD (g/cm ²)	YA (%)	YA T-score	AM (%)	AM Z-score
L1	0,995	87	-1,2	92	-0,7
L2	1,117	92	-0,8	97	-0,3
L3	1,107	91	-0,9	95	-0,4
L4	1,040	86	-1,4	90	-0,9
L1-L2	1,055	90	-1,0	94	-0,5
L1-L3	1,074	91	-0,9	95	-0,4
L1-L4	1,064	89	-1,1	94	-0,6
L2-L3	1,111	92	-0,8	96	-0,4
L2-L4	1,085	89	-1,1	94	-0,6
L3-L4	1,071	88	-1,2	92	-0,7



Region	BMD (g/cm ²)	YA (%)	YA T-score	AM (%)	AM Z-score
Szyjka Lewa	0,988	95	-0,4	99	0,0
Obszar Ward'a Lewa	0,921	101	0,1	104	0,3
Krętarz Lewa	0,756	89	-0,8	93	-0,5
Trzon Lewa	1,092	-	-	-	-
Total Lewa	0,946	94	-0,5	98	-0,2



Region	BMD (g/cm ²)	YA (%)	YA T-score	AM (%)	AM Z-score
Szyjka Prawa	1,028	99	-0,1	103	0,2
Obszar Ward'a Prawa	1,006	111	0,7	113	0,9
Krętarz Prawa	0,785	92	-0,6	97	-0,2
Trzon Prawa	1,064	-	-	-	-
Total Prawa	0,961	95	-0,4	99	0,0

Statystycznie 68% powtórnych skanowań mieści się w przedziale 1SD ($\pm 0,010$ g/cm² dla Kregosłup AP L1-L4); ($\pm 0,012$ g/cm² dla Lewa kość udowa Total); T-score: USA (połączone NHANES (20-30 lat) / Lunar (20-40 lat)) Kregosłup AP; Kobieta; Biała Populacja referencyjna (v113); T-score: USA (połączone NHANES (20-30 lat) / Lunar (20-40 lat)) Kość udowa; Kobieta; Biała Populacja referencyjna (v113); Z-score: Kregosłup AP Dopasowane dla wieku, Płeć, wagi (kobiety 25-100 kg), pochodzenia etnicznego; Z-score: Lewa kość udowa Dopasowane dla wieku, Płeć, wagi (kobiety 25-100 kg), pochodzenia etnicznego; Światowa Organizacja Zdrowia - Definicja osteoporozy i Osteopenia dla kobiet rasy kaukaskiej; Stan normalny = wskaźnik T-score równy lub wyższy niż -1,0 SD; Osteopenia = T-score między -1,0 a -2,5 SD; Osteoporoza = T-score równy lub niższy -2,5 SD; (definicje WHO obowiązują tylko wówczas, gdy wartość T-score jest określana na podstawie referencyjnej bazy danych dla młodych zdrowych kobiet rasy kaukaskiej)

Data utworzona: 15/11/2022 07:08:34 17 (SP 4); Nazwa pliku: 8jclrcvdx.nax; Kregosłup AP: 76,1,00:60,00:10,0 0,00:9,50 0,60x1,36 17,64,9 % Tkanka tłuszczowa; 0,00:0,00 0,00:0,00; Tryb skanowania: Standard; OneScan: 22,0 µSy; Lewa kość udowa: 76,1,00:60,00:10,0 0,00:10,70 0,60x1,36 14,8,9,2 % Tkanka tłuszczowa; 0,00:0,00 0,00:0,00; Kąt szyjki (stopnie)= 49; Tryb skanowania: Standard 22,0 µGy; Prawa kość udowa: 76,1,00:60,00:10,0 0,00:10,70 0,60x1,36 15,0,9,5 % Tkanka tłuszczowa; 0,00:0,00 0,00:0,00; Kąt szyjki (stopnie)= 52; Tryb skanowania: Standard 22,0 µGy

Treatment

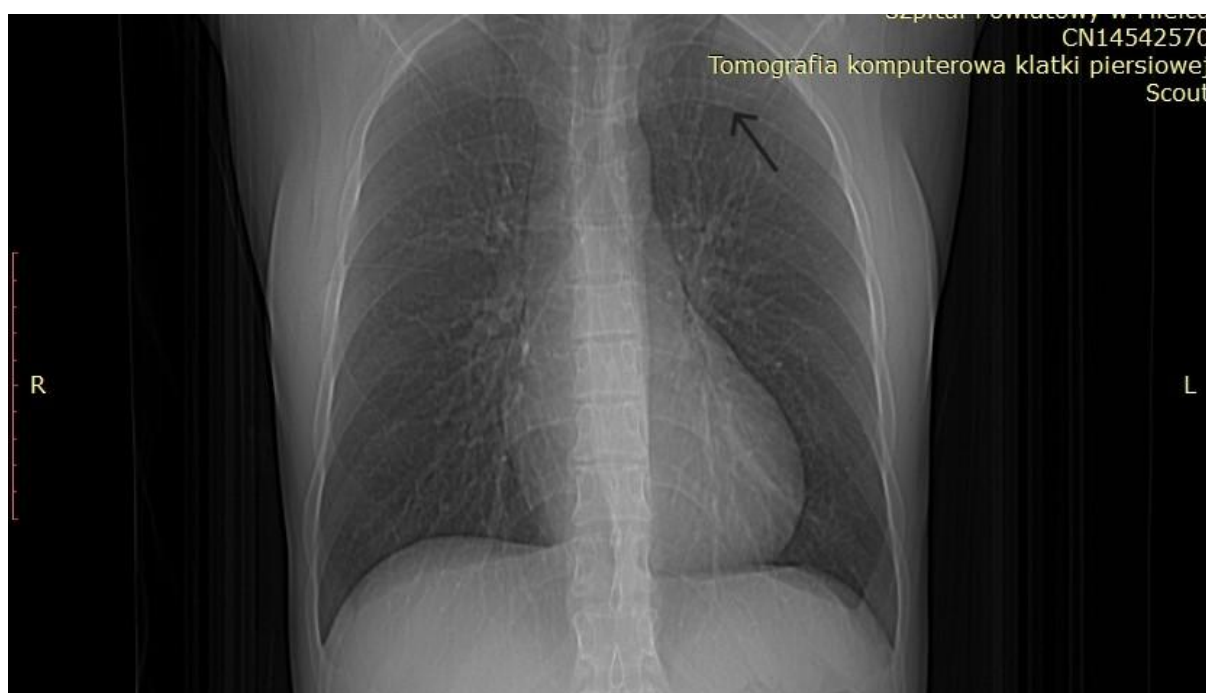A break in physical activity for six weeks was recommended. PRF was administered under USG guidance to the fracture site one week after diagnosis. Ultrasound therapy with the

Exogen device was applied, as well as TECAR therapy to accelerate recovery processes. After 6 weeks, exercises to strengthen the rotator cone muscles, chest muscles and breathing exercises were implemented. Manual therapy for shoulder girdle muscles was implemented from week 6.

Follow-up and outcomes

The patient responded well to treatment, during which there were no side effects. Six weeks after the diagnosis, a follow-up chest tomography was performed, which showed bony superstructure at the fracture site. (Figure 3). The patient reported no pain symptoms. The return to racewalking training occurred after 10 weeks.

Figure 3. The arrow indicates a bone scar formed at the site of a fracture that has fused



Discussion

The presented case of a fatigue fracture of a rib in a professional walker represents a very rare injury occurring in a group of athletes. Risk factors and possible causes of fracture should be considered. Undoubtedly, the training loads to which the athlete was subjected, menstrual disorders associated with low estrogen levels and inadequate recovery (numerous competitions in a short period of time and numerous trips involving a change of time zone and the resulting sleep deficiency) may have had an impact. [8- 10,13]

The high number of repetitions of movement of the upper limbs during exercise associated with asymmetry of their work, a muscular imbalance resulting from the current lumbar scoliosis, may also have an impact. [16]

The pathogenesis of the fracture may be similar in nature to the described fractures of the first rib. [1,16]

The opposing action of the muscles attaching to the surface of the second rib, i.e. the posterior oblique and anterior dentate muscles, may have caused micro-injuries. [17]

The escalating nature of the pain may have initially suggested a fracture of the bone structure. In this case, physiotherapy management involving mechanical manipulation of the thoracic spine and additional pressure on the thoracic spine may have further increased the number of micro-injuries. It is therefore important to take this type of injury into account when making a diagnosis, so as not to aggravate the patient's condition.

The sudden exacerbation of pain symptoms may have been related to the complete disruption of the bone during the competition, that is, during submaximal physical effort, when the intensely working muscles generated suprathreshold forces on the bone structure.

Conclusions

Fatigue rib fracture among athletes is a very rare injury that can produce very nonspecific symptoms. The absence of menstruation, which can be the result of REDS syndrome, can be an important alarm signal that should not be ignored. Strengthening the muscular apparatus improves the distribution of loads, reducing the pressure of forces acting on the long axis of the bone and reduces the risk of fracture. Adequate dietary energy supply with special emphasis on calcium prevents low bone density, which occurs especially in women.

Disclosure

Author's contribution

Conceptualization, Katarzyna Zdziebło, and Urszula Łapińska; methodology, Piotr Zdziebło; software, Ewelina Machała-Ćwikła; check, Anna Bieniasz, Anna Zdziebło and Piotr Ćwikła; formal analysis, Dominika Machała and Kamila Machała; investigation, Piotr Zdziebło; resources, Katarzyna Zdziebło; data curation, Anna Bieniasz; writing - rough preparation,

Dominika Machała; writing – Kamila Machała and editing, Urszula Łapińska; visualization, Anna Zdziebło; supervision, Piotr Ćwikła; project administration, Ewelina Machała-Ćwikła; receiving funding- not applicable

All authors have read and agreed with the published version of the manuscript.

Ethical Statement & Informed Consent

The study was conducted according to the WMA Declaration of Helsinki - Ethical Principal for Medical Research Involving Human Subjects. The patient gave informed consent.

Financing statement

This research received no external funding.

Institutional Review Board Statement

Not applicable.

Informed Consent Statement

Not applicable.

Data Availability Statement

All data generated or analyzed during this study are included in this article. Further enquiries can be directed to the corresponding author.

Acknowledgements

Not applicable.

Conflict of interest

The authors deny any conflict of interest

References

1. Schaffler MB, Radin EL, Burr DB. Mechanical and morphologic effects of strain rate on fatigue of compact bone. *Bone*. 1989;10(3):207–214. doi:10.1016/8756-3282(89)90055-0.

2. Sweet DE, Allman RM. RPC of the month from the AFIP. *Radiology*. 1971;99(3):687–693. doi:10.1148/99.3.687.
3. Funakoshi T, Furushima K, Kusano H, Itoh Y, Miyamoto A, Horiuchi Y, et al. First-Rib Stress Fracture in Overhead Throwing Athletes. *J Bone Joint Surg Am*. 2019 May 15;101(10):896-903. doi: 10.2106/JBJS.18.01375.
4. Noonan TJ, Sakryd G, Espinoza LM, Packer D. Posteriorribstressfracture in professional baseball pitchers. *Am J Sports Med*. 2007;35(4):654–658. doi:10.1177/0363546506296834.
5. Tullos HS, Erwin WD, Woods GW, Wukasch DC, Cooley DA, King JW. Unusuallesions of the pitchingarm. *ClinOrthopRelat Res*. 1972;88:169–182. doi:10.1097/00003086-197210000-00029.
6. Tenforde AS, Sayres LC, McCurdy ML, Sainani KL, Fredericson M. Identifying sex-specificriskfactors for stressfractures in adolescent runners. *MedSci Sports Exerc*. 2013;45(10):1843–1851. doi:10.1249/MSS.0B013E3182963D75.
7. Bulathsinhala L, Hughes JM, McKinnon CJ, Joseph R Kardouni, Katelyn I Guerriere, Kristin L Popp et al. Risk of stressfracturevaries by Race/Ethnicorigin in a cohortstudy of 1.3 million US armysoldiers. *J Bone Miner Res*. 2017;32(7):1546–1553. doi:10.1002/JBMR.3131.
8. Kale NN, Wang CX, Wu VJ, Miskimin C, Mulcahey MK. Age and Female Sex Are Important Risk Factors for Stress Fractures: A Nationwide Database Analysis. *Sports Health*. 2022 Nov-Dec;14(6):805-811. doi: 10.1177/19417381221080440.
9. Bulger EM, Arneson MA, Mock CN, Jurkovich GJ. Ribfractures in the elderly. *J Trauma*. 2000 Jun;48(6):1040-6; discussion 1046-7. [PubMed] doi: 10.1097/00005373-200006000-00007.
10. Tenforde AS, Sayres LC, McCurdy ML, Sainani KL, Fredericson M. Identifying sex-specificriskfactors for stressfractures in adolescent runners. *MedSci Sports Exerc*. 2013;45(10):1843–1851. doi:10.1249/MSS.0B013E3182963D75.
11. Lambrinouadaki I, Papadimitriou D. Pathophysiology of bone loss in the female athlete. *Ann N Y Acad Sci*. 2010 Sep;1205:45-50. doi: 10.1111/j.1749-6632.2010.05681.x.
12. Gerrie BJ, Harris JD, Lintner DM, McCulloch PC. Lower thoracic rib stress fractures in baseball pitchers. *Phys Sportsmed*. 2016;44(1):93-6. doi: 10.1080/00913847.2015.1116363.
13. Ribfractures in athletes. Miles JW, BarrettGR. *Sports Med*. 1991 Jul;12 doi: 10.2165/00007256-199112010-00005.

14. Monteleone GP. Stressfractures in the athlete. *OrthopClinNorth Am.* 1995;26(3):423–432. doi:10.2165/00007256-199214050-00005.
15. Iwamoto J, Takeda T. Stressfractures in athletes: review of 196 cases. *J OrthopSci.* : 10.1007/s10776-002-0632-5 doi: 10.1007/s10776-002-0632-5.
16. Sinha AK, Kaeding CC, Wadley GM. Upper extremitystressfractures in athletes: clinicaldoifeatures of 44 cases. *Clin J Sport Med.* 1999;9(4):199–202. doi:10.1097/00042752-199910000-00003.
17. Graeber GM, Nazim M. The anatomy of the ribs and the sternum and theirrelationship to chestwallstructure and function. *ThoracSurgClin.* 2007 Nov;17(4):473-89, vi. [PubMed] doi: 10.1016/j.thorsurg.2006.12.010.