

DOI: 10.15225/PNN.2018.7.3.5

**Selected Problems of the Patient
after the Peak-occipital Decompression Surgery Treatment
in the Course of the Chiari type I Malformation**

**Wybrane problemy pacjenta po zabiegu odbarczenia szczytowo-potylicznego
w przebiegu zespołu Chiariego typ I**

**Beata Haor¹, Robert Ślusarz¹, Agnieszka Królikowska¹, Renata Jabłońska¹,
Mariola Głowacka², Anita Królikowska³**

¹Neurological and Neurosurgical Nursing Department, Faculty of Health Sciences, Collegium Medicum,
Nicolaus Copernicus University, Toruń, Poland

²Department of Nursing, Chair of Integrated Medical Care, Faculty of Health Sciences,
The State University of Applied Sciences in Płock, Poland

³Faculty of Health Sciences, The State University of Applied Sciences in Płock, Poland

Abstract

Introduction. The Chiari type I Malformation is a malformation of the hindbrain and skull. It refers to moving down the tonsils of the cerebellum through a large opening to the upper part of the spinal canal.

Case Report. The patient aged 27 was subjected to a peak-occipital decompression procedure in the course of the Chiari type I Malformation due to the results of imaging examinations and reported complaints.

Discussion. The neurosurgical treatment for both the patient and his family is a source of stress and fear of further functioning in the environment. During hospitalization, the patient should be surrounded by the care and interest of the therapeutic team members.

Conclusions. Symptoms of Chiari Malformation type I may affect patients of different ages despite the fact that it is an inborn defect. Nursing care of the patient after the peak-occipital decompression treatment in the course of the Chiari type I Malformation aims at preventing typical complications of the postoperative period and minimizing the risk of neurological deficits. (JNNS 2018;7(3):124–129)

Key Words: Chiari type I Malformation, neurosurgical operation, nursing process

Streszczenie

Wstęp. Zespół Chiariego typ I to malformacja tyłomózgowia i czaszki. Odnosi się do przesunięcia w dół migdałków mózdzku przez otwór wielki do górnej części kanału kręgowego.

Opis przypadku. Pacjent lat 27 został poddany zabiegowi odbarczenia szczytowo-potylicznego w przebiegu zespołu Chiariego typ I z uwagi na wyniki badań obrazowych oraz zgłaszane dolegliwości.

Dyskusja. Zabieg neurochirurgiczny zarówno dla pacjenta jak i dla jego rodziny jest źródłem stresu i lęku przed dalszym funkcjonowaniem w środowisku. W okresie hospitalizacji pacjent powinien być otoczony opieką i zainteresowaniem członków zespołu terapeutycznego.

Wnioski. Objawy zespołu Chiariego typ I mogą dotyczyć pacjentów w różnym wieku pomimo, że jest to wada wrodzona. Opieka pielęgniarska nad pacjentem po zabiegu odbarczenia szczytowo-potylicznego w przebiegu zespołu Chiariego typ I zmierza do profilaktyki typowych powikłań okresu pooperacyjnego i minimalizowania ryzyka deficytów neurologicznych. (PNN 2018;7(3):124–129)

Słowa kluczowe: Zespół Chiariego typ I, operacja neurochirurgiczna, proces pielęgnowania

Introduction

The Arnold-Chiari Syndrome (called Arnold-Chiari Malformation — ACM, Chiari Malformation — CM) is the malformation of the hindbrain and skull. It refers to moving downwards the tonsils of the cerebellum through a large opening to the upper part of the spinal canal [1,2]. There are no unequivocal explanations for the etiology of this primary disorder during development, hence congenital malformation. H.B. Sarnat has suggested that the cause of this situation are primary defects in the genetic programming of hindbrain and the growth of related bones as well as of cranial structures [2]. Another theory indicates that this is the result of progressive hydrocephalus of the fetus. Some researchers point to a faulty closing of the neural tube during early fetal development, which affects the leakage of cerebrospinal fluid [2]. According to another theory the development of the volume of the posterior cranial fossa does not correspond to the increase in the size of the brain, which leads to anatomical anomalies of the cerebellum, brain stem with displacement down towards the cerebellum into the spinal canal [2].

The Chiari Malformation is most often diagnosed in the first months of the child's life or during adolescence. In adulthood, however, it is diagnosed accidentally. There are four distinguished types of this syndrome depending on the degree of cerebellum displacement, complications resulting from this malformation and the period of life in which it is recognized. However, impaired cerebrospinal fluid (CSF) flow is a common feature of all four types of this malformation [3].

The most common form is type I (CM I) malformation [3]. It was first identified in 1883 by Cleland and described and classified in four types in 1891 by Hans von Chiari [3,4].

In the case of Chiari type I Malformation, the tonsils of the cerebellum are located at least 3–5 mm below the level of the foramen magnum (FM) [1]. Due to impaired CSF flow, approximately 70–80% of CM I cases spinal cord syringomyelia develops. In addition, hydrocephalus, scoliosis, kyphosis might occur [1,3,5]. CM I manifests various neurological symptoms that may be visible in the second or third decade of life or even when collecting information from older people it turns out that they have been present since birth or childhood and have intensified [6].

Clinical symptoms often occur in young people, and the standard of CM I diagnosis is different in people under 15 years of age than in those aged over 15. In the group of patients under 15 years, type I malformation is defined as the extension of the cerebellar tonsil by more than 5 mm, whereas in patients over 15 years as greater than 6 mm [2]. The most frequently reported symptoms include:

- severe headaches in the occiput, radiating to the top of the head, ear, the area between the eyes, neck, shoulder,
- headaches intensify, for example during coughing, sneezing,
- ringing and tinnitus,
- generalized fatigue,
- nystagmus,
- loss of feeling of pain, temperature,
- in most patients there occurs a degree of ataxia after reaching the age of walking,
- motor weakness, particularly in the upper limbs,
- cranial nerve deficits manifested by hoarseness, cough, dysphagia,
- sleep apnea,
- nausea and vomiting [3,4,7].

Magnetic resonance imaging (MRI) is the gold standard for diagnosing CM. It is necessary to perform this test in relation to the head, cervical and thoracic spine, also with the use of contrast. It allows to illustrate skeletal bone defects, to what extent the tonsils of the cerebellum are moved towards the spinal canal, determine spinal cord cavity and determine the effect of CM on CSF [3]. Computed Tomography (CT) or X-ray (radioisotope thermoelectric generator) of the neck and head can reveal common, related bone defects, significant for surgical planning. In contrast, EEG (electroencephalogram) is of limited value because CM has no effect on the cortex except for hydrocephalus [3,8]. Differential diagnosis is also performed to rule out, for example, spinal discopathy, polyneuropathy, post-traumatic brain injury, central nervous system tumors, multiple sclerosis. A properly collected interview and neurological physical examination are also important [8].

The basis of CA therapy is neurosurgical treatment. It aims at restoring the flow of cerebrospinal fluid, relaxing the nerve elements, providing more space at the base of the skull and upper cervical spine. Surgical treatment provides only stabilization of symptoms or moderate improvement. Nevertheless, early surgical intervention gives a chance for a better quality of life in connection with the reduction of headache, neurological symptoms [6]. Pharmacological treatment is also implemented (particularly due to severe pain) and so is rehabilitation [5].

The work presents the description of selected problems of the patient after the peak-occipital decompression surgery treatment in the course of the Chiari type I Malformation.

Case Report

The XY patient, aged 27, for a long time had complained of numbness in the left upper limb, burning and pain around the neck, shoulder and tinnitus. He was lethargic, constantly tired. After long-term diagnostics, the patient was diagnosed with Arnold-Chiari Malformation type I and spinal cavity in 2016.

The patient is professionally active — performs an 8-hour work sitting in front of the computer. He prefers an active lifestyle; three times a week he conducts break dance classes. However, he remains cautious during exercise because their intense performing intensifies the symptoms of the disease. In 2010 he suffered an injury, as a result of which it was necessary to carry out surgical intervention under general anesthesia (reconstruction of the crimson-collarbone ligaments using the MINAR method). XY is single, he rents a two-bedroom flat with a flatmate. He maintains positive relationships with parents and with his adult sister.

The patient was qualified for top-occipital decompression surgery due to the results of imaging examinations. The magnetic resonance of the head with contrast confirmed the Arnold-Chari Malformation type I, the abnormal position and morphology of the tonsils of the cerebellum, which were extended and displaced downwards, towards the back of the medulla and cervical cord. Their lower poles were located about 17 mm below the occipital aperture of the occipital bone. The nervous tissue of the brain, cerebellum and brainstem, brain ventricle system, fcerebral fluid spaces — correct. In turn, magnetic resonance of the cervical spine confirmed the hydrosyroid cavity image in the course of malformation, Arnold-Chiari type I Malformation, the elimination of the physiological curvature of the spine, widening of the cervical spinal cord as well as of the thoracic spine examined (Figure).

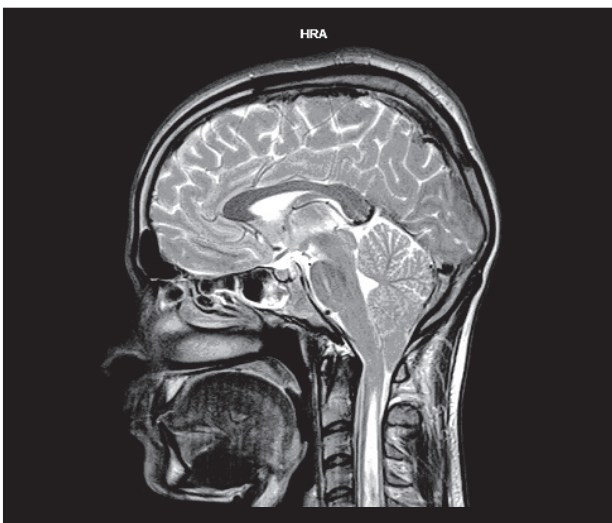


Figure. Lowering the cerebellar tonsils.
From: Author's own material

The patient on the first day after the peak-occipital decompression surgery, conscious, with logical verbal contact, without neurological deficits. Generally good condition; life parameters stay within the normal range. The patient reports pain in the area operated on, on the occiput (7 points on the VAS scale). Due to that the patient limits head movements to a minimum. Post-operative wound without exudation, without redness, there is slight swelling in the place of sutures. Dressing on the wound — dry. The patient experiences discomfort caused by a deficit of independence in the field of movement, performing self-care activities. He requires assistance and safeguarding from another person in the aforementioned activities. The patient and his family are afraid of complications of the disease, further, independent functioning in the home environment. They do not have sufficient knowledge in this area.

Below, there is presented a proposal of nursing activities aimed at solving selected problems of the patient after peak-occipital decompression surgery in the course of CM 1 [9,10].

Problem 1: Bad Mood Caused by Pain Within the Post-operative Wound

Nursing interventions:

1. Pain assessment — reasons, factors affecting its severity/reduction, intensity according to the VAS scale (Visual Analogue Scale), nature of ailments, duration, type, location.
2. Administration of painkillers according to doctor's prescription.
3. Ensuring silence, peace, conditions for rest, comfortable position in bed.
4. Efficient performance of ordered treatments and care activities.
5. Monitoring patient's pain and well-being.
6. Monitoring basic vital parameters.

Expected result: Pain reduction, improvement of the patient's mood.

Problem 2: The Risk of Post-operative Complications, Neurological Deficits and the Life Threatening Condition Associated with Them

Nursing interventions:

1. Placing the patient in a room of intensive neurosurgical supervision, in a multi-functional bed with the head and trunk raised at an angle of 10–30 degrees.
2. Ensuring a stable head position.
3. Monitoring patient's state of consciousness according to the Glasgow scale.

4. Monitoring of vital signs.
5. Monitoring patient's well-being, reported complaints.
6. Maintaining verbal and visual contact with the patient.
7. Observing the patient for convulsions.
8. Assessment of the width, symmetry and size of the pupils.
9. Assessment of speech, surface sensation disorders, muscle strength and muscle tension.
10. Controlling water balance and diuresis.
11. Maintaining an unobstructed access to the peripheral vein.
12. Administration of medicines and fluids compliant with the medical order.
13. Avoiding laying the patient in positions that impede venous outflow from the brain and affecting the increase of intracranial pressure.
14. Drawing patient's attention to eliminating factors with an effect similar to the Valsalva sample leading to an increase in the pressure of the abdominal press (e.g. sneezing, inappropriate technique of changing the position of the posture).

Expected result: Without postoperative complications, neurological deficits and the life threatening conditions associated with them.

Problem 3: The Risk of Post-operative Wound Infection

Nursing interventions:

1. Observation of the wound for signs of inflammation.
2. Evaluation of the wound dressing, possible blood, cerebrospinal fluid seepage.
3. Monitoring of vital signs.
4. Monitoring patient's well-being, reported ailments.
5. Performing a dressing change according to the principles of asepsis and antisepsis.
6. Regular change of bed linen.
7. Explaining to the patient the directions of self-observation and principles of wound care.

Expected result: No signs of post-operative wound infection.

Problem 4: Discomfort Resulting from the Self-care Deficit Following Surgery and/or Neurological Deficit

Nursing interventions:

1. Assessment of patient's ability and independence in self-care with the use of clinimetric scales.
2. Encouraging the patient to get involved in the self-care activities.

3. Assisting and supporting the patient during the performance of self-care activities, including movement.
4. Providing access to medical devices (balcony, stroller) while securing the patient.
5. Mobilizing the patient to active participation in the rehabilitation.
6. Encouraging the family to assist the patient in self-care activities.
7. Talking to the patient about the acceptance of his current situation and self-care deficits.

Expected result: Improvement of patient's well-being, active participation in activities related to self-care.

Problem 5: Lack of Knowledge About Modifying Current Lifestyle

Nursing interventions:

1. Assessment of patient's knowledge and skills regarding self-care in the post-operative period.
2. Establishing a plan of educational activities with the patient and family.
3. Providing contact with a physician and physiotherapist in order to obtain guidelines on health control and systematically conducted rehabilitation, possibilities of continuing work and physical activity in leisure time.
4. Providing guidelines on the directions of self-observation, post-operative wound care, prevention of constipation and elimination of activities affecting the increase of abdominal pressure and intracranial pressure.
5. Including the family to support the patient in adherence to lifestyle recommendations after the surgery.

Expected result: Patient's knowledge and readiness to changes in the current lifestyle.

Discussion

The analysis of reports from world literature indicates an increase in interest in the effectiveness of neurosurgical treatment results of the Chiari type I unit by means of apical-occipital decompression [5,6].

The surgical procedure for both the patient as well as for his family is a source of great stress, contributes to a sense of insecurity and fear of further functioning in the environment. During hospitalization period, the patient should be surrounded by the care and interest of the therapeutic team members [11].

Nursing care is significant in the perioperative period. The nurse accompanies the patient during the preparation for surgery. She carries out the process of

self care education in the period before and following surgery, assists in self-service activities, conducts accurate observation for the occurrence of postoperative complications, neurological deficits, and emotionally supports the patient and patient's family [9–11].

Mental preparation is an important element of patient preparation for surgery. The nurse should determine patient's knowledge about the perioperative period and aim at completing the deficits in this area. The purpose of education also includes learning and teaching exercises which help the patient to effectively cope with the period of convalescence and reduce the risk of complications. Providing support to the patient and facilitating contact with relatives and the therapeutic team allows to decrease the stress associated with hospitalization [11].

After the peak-occipital decompression surgery in the course of the Chiari type I Malformation, the nurse must conduct an assessment of patient's general and neurological condition. Monitoring concerns vital parameters, fluid balance and diuresis. It is necessary to control patient's state of consciousness, the condition of the surgical wound and of the dressing applied, as well as to observe for convulsions. It is necessary to assess the width, symmetry and size of the pupils, analyse possible speech disorders, surface sensation, muscle strength and tension. The nurse ought to implement effective actions to assess and minimize pain within the post-operative wound. An important aspect of care in the post-operative period is to avoid placing the patient in positions that impede venous outflow from the brain and contribute to the increase in intracranial pressure. It should be noted that the patient ought to avoid behaviors leading to an increase in the pressure of the abdominal press and as a result of an increase in intracranial pressure, e.g. sneezing without compressing the abdominal cavity, inappropriate technique of changing the position of the posture [5,9–11].

After the peak-occipital decompression surgery, it is necessary to remember about patient's gradual start-up. Under the supervision of a physiotherapist, the stability of the neck should be improved in the initial postoperative period. Initially, passive exercises are recommended (bending upper and lower limbs, lifting the head with the help of the palm). The first element of gradual start-up is the patient's implementation to the rules and techniques of position changing from lying to sitting one. It is important to do it slowly, without making quick, sudden and unnecessary movements. The patient should first lie on their side and gradually move to a sitting position, supporting themselves with hands, and then move the legs off the bed. The first steps after the surgery should be made with the assistance of a nurse/physiotherapist. They should observe patient's condition, paying attention to how they manage to maintain their balance, how they move [5,11].

The nurse should implement patient's education about the daily activity of the patient in the home environment. In the postoperative period, the patient should avoid:

- activities connected with the threat of injuries, in particular such sports, as football, boxing, basketball,
- activities leading to an increase in pressure in the abdominal cavity and leading to an increase in intracranial pressure, e.g. effort to defecate in the case of constipation, sneezing and cough without compressing the abdominal cavity,
- carrying heavy loads,
- diving [5].

Overall post-operative outcomes are assessed on the basis of the following criteria: excellent results — improvement of neurological deficit; good result — stopping the progression of neurological deficit and poor result — deterioration of neurological functions. Further treatment of the patient is based on the results of magnetic resonance imaging, which allow to assess whether the tonsils of the cerebellum have not been further lowered and on a neurological examination performed by a specialist physician [2].

The patient should undergo systematic rehabilitation. Physiotherapy aims at relieving pain and preserve the range of motion within the cervical spine and shoulders. It is supported by pharmacotherapy. The aim of physiotherapy is to implement the patient to the recommendations concerning the optimization of joint movements in order to reduce the overload of the upper and lower limbs, as well as to enable the continuation of daily life activities and work [5].

Conclusions

1. Symptoms of Chiari type I Malformation may affect patients of different ages despite being a congenital defect.
2. Nursing care of the patient after the peak-occipital decompression treatment in the course of the Chiari type I Malformation aims at preventing typical complications of the postoperative period as well as at minimizing the risk of neurological deficits.

References

- [1] Støverud K.H., Langtangen H.P., Ringstad G.A., Eide P.K., Mardal K.A. Computational Investigation of Cerebrospinal Fluid Dynamics in the Posterior Cranial Fossa and Cervical Subarachnoid Space in Patients with Chiari I Malformation. *PLoS One*. 2016;11(10):e0162938.

- [2] Chen J., Li Y., Wang T. et al. Comparison of posterior fossa decompression with and without duraplasty for the surgical treatment of Chiari malformation type I in adult patients: A retrospective analysis of 103 patients. *Medicine*. 2017;96(4):e5945.
- [3] Ghaly R.F., Tverdohle T., Candido K.D., Knezevic N.N. Management of parturients in active labor with Arnold Chiari malformation, tonsillar herniation, and syringomyelia. *Surg Neurol Int*. 2017;8:10.
- [4] Fukuoka T., Nishimura Y., Hara M. et al. Chiari Type 1 Malformation-induced Intracranial Hypertension with Diffuse Brain Edema Treated with Foramen Magnum Decompression: A Case Report. *NMC Case Rep J*. 2017; 4(4):115–120.
- [5] Zderkiewicz E. Jamistość rdzenia kręgowego; patogeneza, diagnostyka, leczenie, rehabilitacja. *Zeszyty Naukowe WSSP*. 2013;17:191–207.
- [6] Gilmer H.S., Xi M., Young S.H. Surgical Decompression for Chiari Malformation Type I: An Age-Based Outcomes Study Based on the Chicago Chiari Outcome Scale. *World Neurosurg*. 2017;107:285–290.
- [7] Jayamanne C., Fernando L., Mettananda S. Chiari malformation type I presenting as unilateral progressive foot drop: a case report and review of literature. *BMC Pediatr*. 2018;18(1):34.
- [8] Bogucki P. Opis przypadku 51-letniej kobiety z zespołem Arnoldda-Chiari. *Aktual Neurol*. 2007;7(1):59–62.
- [9] Jabłońska R., Rosińczuk-Tonderys J. Problemy pielęgnacyjne pacjentów z niedomogą kręgosłupa. W: Jabłońska R., Ślusarz R. (Red.), *Wybrane problemy pielęgnacyjne pacjentów w schorzeniach układu nerwowego*. Wyd. Continuo, Wrocław 2012;218–230.
- [10] Snarska K.K. Problemy pielęgnacyjne pacjentów z wodogłowiem. W: Jabłońska R., Ślusarz R. (Red.), *Wybrane problemy pielęgnacyjne pacjentów w schorzeniach układu nerwowego*. Wyd. Continuo, Wrocław 2012;231–244.
- [11] Walewska E. Przygotowanie chorego do zabiegu operacyjnego. W: Walewska E., Ścisło L. (Red.), *Procedury pielęgnacyjne w chirurgii. Podręcznik dla studiów medycznych*. Wyd. Lekarskie PZWL, Warszawa 2012;1–36.

Corresponding Author:

Beata Haor

Department of Neurological and Neurosurgical Nursing,
Faculty of Health Science,
The Ludwik Rydygier Collegium Medicum in Bydgoszcz,
The Nicolaus Copernicus University Toruń, Poland
ul. Łukasiewicza 1, 85-821 Bydgoszcz, Poland
e-mail: zpielnin@cm.umk.pl

Conflict of Interest: None**Funding:** None

Author Contributions: Beata Haor^{C, E, F, H}, Robert Ślusarz^{C, G, H},
Agnieszka Królikowska^{C, G, H}, Renata Jabłońska^{C, G, H}, Mariola Głowacka^{B, C, F–H}, Anita Królikowska^{B, C, F}

(B — Collection and/or compilation of data, C — Analysis and interpretation of data, E — Writing an article, F — Search of the literature, G — Critical article analysis, H — Approval of the final version of the article)

Received: 29.03.2018**Accepted:** 16.05.2018