

DOI: 10.15225/PNN.2019.8.1.4

## Early Therapeutic Intervention in a Child with Beckwith–Wiedemann Syndrome in Inpatient and Outpatient Conditions — Case Report

### Wczesna interwencja terapeutyczna w przypadku dziecka z Zespołem Beckwitha–Wiedemanna na oddziale szpitalnym i w warunkach ambulatoryjnych — opis przypadku

Teresa Kaczan<sup>1</sup>, Robert Śmigiel<sup>2</sup>, Magdalena Kazimierska-Zajac<sup>1</sup>,  
Robert Dymarek<sup>1</sup>, Joanna Rosińczuk<sup>1</sup>

<sup>1</sup>Department of Nervous System Diseases, Faculty of Health Sciences, Wrocław Medical University, Poland

<sup>2</sup>Department of Propaedeutics of Paediatrics Rare Disorders, Faculty of Health Sciences, Wrocław Medical University, Poland

#### Abstract

**Introduction.** The Beckwith–Wiedemann syndrome (BWS) is a rare disorder characterized by a wide spectrum of symptoms i.a. umbilical hernia or omphalocele, macroglossia and above-average pre/postnatal growth (macrosomia).  
**Aim.** To present a case report of a child with BWS who underwent an early logopedic intervention and rehabilitation procedures including Bobath neuro-developmental treatment (NDT) and orofacial stimulation based on the Castillo-Morales concept (CMC).

**Case Report.** The paper presents a case of a girl with BWS and the course of her psychomotor development during the 24 months of her life. The child has numerous defects typical for this syndrome, i.e. facial dysmorphism, macrosomia, and significant hypertrophy of the tongue as well as embryonal carcinomas such as hepatoblastoma and neuroblastoma. Psychomotor development was assessed at the age of 12 months using the Munich Functional Developmental Diagnostics (MFDD). At the age of 2, development of fine and gross motor skills and independence level do not differ significantly from the norm. The biggest problem concerns verbalization of needs due to the enlarged tongue. The girl still remains under multidisciplinary team care and is intensively rehabilitated.

**Discussion.** There is no doubt that the care of children with BWS requires an interdisciplinary team of specialists. The child needs not only proper physical development, but also correct interpersonal relationships built on verbal communication. Therapy should be started as early as possible before bad habits develop.

**Conclusions.** The knowledge of clinical features characteristic for the syndrome allows for rapid diagnosis and providing interdisciplinary care since the moment of birth. Children with BWS develop in individual ways depending on the type of genetic cause and additional defects. The care of BWS children must involve permanent and interdisciplinary co-operation with many specialists. (JNPN 2019;8(1):23–29)

**Key Words:** Beckwith–Wiedemann syndrome, child health, rare genetic diseases, early intervention, speech therapy, developmental rehabilitation

#### Streszczenie

**Wstęp.** Zespół Beckwitha–Wiedemanna (BWS) jest rzadkim zaburzeniem charakteryzującym się szerokim spektrum objawów, tj. przepukliną pępowinową, makroglosją i ponadprzeciętną masą ciała przed/po urodzeniu (makrosomia).

**Cel.** Przedstawienie opis przypadku dziecka z BWS, u którego zastosowano wczesną interwencję logopedyczną oraz procedury rehabilitacji, w tym postępowanie według metody Bobath (NDT) i stymulację orofacialną w oparciu o koncepcję Castillo-Moralesa (CMC).

**Opis przypadku.** W pracy przedstawiono przypadek dziewczynki z BWS oraz przebieg jej rozwoju psychoruchowego w ciągu 24 miesięcy jej życia. Dziecko ma wiele wad charakterystycznych dla omawianego zespołu, tj. dysmorfizm twarzy, makrosomię i znaczną hipertrofię języka, jak również nowotwory zarodkowe, takie jak hepatoblastomę i neuroblastomę.

Rozwój psychoruchowy oceniano w wieku 12 miesięcy za pomocą Munich Functional Developmental Diagnostics (MFDD). W wieku 2 lat rozwój małej i dużej motoryki oraz samodzielności nie odbiega znacząco od normy. Największy problem dotyczy werbalizacji potrzeb z powodu powiększonego języka. Dziewczynka nadal pozostaje pod opieką interdyscyplinarnego zespołu i jest intensywnie rehabilitowana.

**Dyskusja.** Nie ulega wątpliwości, że opieka nad dziećmi z BWS wymaga interdyscyplinarnego zespołu specjalistów. Dziecko potrzebuje nie tylko prawidłowego rozwoju fizycznego, ale także poprawnych relacji interpersonalnych, budowanych na komunikacji werbalnej. Terapię należy rozpocząć jak najwcześniej, zanim zaczną się rozwijać złe nawyki.

**Wnioski.** Znajomość cech klinicznych charakterystycznych dla tego zespołu pozwala na szybką diagnozę i zapewnienie interdyscyplinarnej opieki od momentu narodzin. Dzieci z BWS rozwijają się w sposób indywidualny w zależności od podłoża genetycznego i od występowania dodatkowych wad. Opieka nad dziećmi BWS musi obejmować stałą i interdyscyplinarną współpracę z wieloma specjalistami. (PNN 2019;8(1):23–29)

**Słowa kluczowe:** Zespół Beckwitha–Wiedemanna, zdrowie dziecka, rzadkie choroby genetyczne, wczesna interwencja, terapia mowy, rehabilitacja zaburzeń wieku rozwojowego

## Introduction

Beckwith–Wiedemann syndrome (BWS) is a rare genetic syndrome described by Beckwith [1] and Wiedemann [2]. The incidence is estimated to occur in 1 in 10.000–15.000 new-borns [3]. Diagnostic criteria of BWS were described by Elliott et al. [4], Rump et al. [5], as well as Ibrahim et al. [6] who also listed three leading symptoms: umbilical hernia or omphalocele (exomphalalos), enlarged tongue (macroglossia), and above-average pre/postnatal growth. Formerly, the name EMG was used, which is the acronym of the listed symptoms.

Children with BWS are characterized by hypoglycaemia in infancy period, asymmetric regional body overgrowth, specific facial dysmorphic features, and predisposition to embryonic malignancies, particularly to Wilms tumour or hepatoblastoma [3,7–9].

Increased growth in children is manifested by high body weight of both the foetus and the new-born and the enlargement of the visceral organs [10]. The growth rate of a baby slows down around, and the final height of an adult is in the higher part of genetic target, not within normal range. Death can occur as a result of complications of prematurity, hypoglycaemia, cardiomyopathy, macroglossia, or cancer [11]. It is very important to know the clinical phenotype of the syndrome in order to make a proper diagnosis and quickly refer a child to multi-specialist medical care centre [12].

BWS aetiology is complex. The syndrome is caused by mutations and epigenetic changes affecting the expression of growth regulators that are located on the short arm of chromosome 11 (11p15). Phenotypic variability reflects the genetic heterogeneity of the syndrome. Chromosome 11p15.5 region contains imprinted genes involved in the regulation of fetal growth [13,14]. This region is organized in two domains (IGF2/H19 and KCNQ1OT1/CDKN1C), each of them under control of its own imprinting control region: ICR1 and ICR2, respectively. Genetic abnormalities in BWS include

loss of methylation at ICR2 (50% of patients), paternal UPD of 11p15.5 (20%), gain of methylation at ICR1 (5–10%) and mutations in CDKN1C gene (5%) (14–17) LOI of KCNQ1OT1 (LIT1). In addition, 2–8% of patients carry copy number variations (CNVs) in the chromosome 11p15.5 region [14–18].

The work presents a case report of a child with BWS who underwent an early logopedic intervention and rehabilitation procedures including Bobath neurodevelopmental treatment (NDT) and orofacial stimulation based on the Castillo-Morales concept (CMC).

## Case Report

The girl was born in 35 weeks of gestational age with 5/6/8/8 points of Apgar score in 1/3/5/ and 10 minute, body weight 2220 g and 10–50 percentile. She was ventilated with Neo-Puff after suctioning the fluid and mucous out. Having achieved the improvement of general condition of the baby, she was transferred to a neonatal intensive care unit.

The examination revealed facial dimorphic features, large tongue and enlarged abdominal circumference. In the ward, the condition of the child was stable. For 7 days the new-born required respiratory support in a nasal continuous positive airway pressure (nCPAP) mode. On the 11th day of life, the condition of the child deteriorated — the skin was pale and mottled, apnoea and decrease of saturation appeared.

Blood test results showed indicators of ongoing inflammatory process. No abnormalities were found in a chest X-ray. Cefuroxime and adjunct medications were administered. Bacteriological tests were normal. The child was in the incubator for 16 days. Hypoglycaemia was observed periodically, and was managed with 10% glucose infusion.

A number of specialist consultations were conducted: cardiological, genetic, orthodontic and speech therapy.

During hospitalization period, the child was rehabilitated holistically including stimulating coordination of suction, breathing and swallowing. After 36 days the girl was discharged home.

### *Cytogenetic and Molecular Tests*

The result of the cytogenetic test: mosaicism 47, XXX/46, XX is a confirmation of two cell lines. In one abnormal line, three X chromosomes (80%) were found, while in the other normal one two X chromosomes (20%). Cytogenetic test revealed a mosaic form of trisomy of the X chromosome and a molecular test was carried out — Methylation Specific Multiplex Ligation-dependent Probe Amplification test (MS-MLPA), which assessed the methylation pattern in BWS-related regions. Paternal uniparental disomy of chromosome 11p15.5 was reported. The test demonstrated an abnormal, elevated methylation level in the differentially methylated region (DMR) of the H19 gene in ICR1 region. Furthermore, reduced methylation level in the DMR gene in ICR2 region was also demonstrated. The results of the molecular examination and clinical signs of the baby unambiguously confirmed a diagnosis of BWS.

### *Specialized Medical Tests*

The conducted tests showed a heart defect as atrial septal defect II (ASD), pulmonary stenosis (PS) with dysplastic pulmonary valve and ultrasonography also showed renal enlargement. The girl was also monitored in the department of endocrinology and diabetology for hyperinsulinemia hypoglycaemia, and after diagnosing the disorder, subjected to further tests.

Additional tests performed at 4 months of age helped to diagnose anaemia and decreased glucose levels with inadequately high insulin levels. Diazoxide therapy was started. The abdominal ultrasound revealed a hypoechogenic focus in the liver measuring 1.7×1.2 cm in size. Due to the elevated alpha fetoprotein levels, oncological consultation was planned.

### **Early Logopaedic Intervention**

As a part of interventional speech therapy, it was recommended to feed the girl with the Haberman bottle in addition to intraoral and orofacial stimulation based on the Castillo-Morales concept (CMC) which was applied due to macroglossia and to prepare facial and oral muscles for surgical reduction of the tongue. The mother was instructed how to position a baby for feeding, laying it down as well as for daily care.

Based on the Integrated Scale of Development (ISD) for ages 0–3 months, it was assessed that the girl was very responsive to sounds. The acoustic-palpebral reflex was correct. The girl recognized her mother's voice, and at the end of the third month she smiled when she saw her caregivers, turning her head towards the source of the sound and reacting to the faces of the speakers. She could recognize familiar and strange sounds. In terms of communication, there appeared crying vocal sounds and occasional vocal response to the sounds of speech. The child most often focused eyes on her mother (Figure 1).

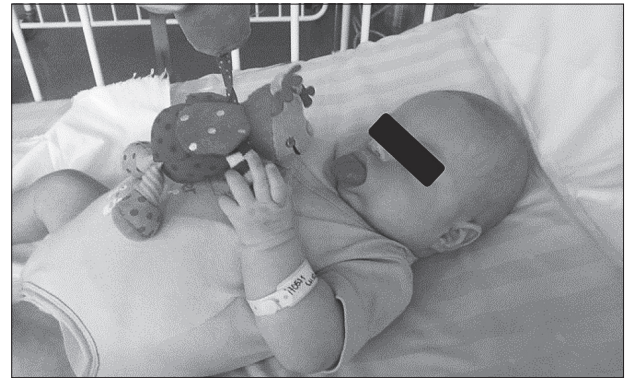


Figure 1. The girl at the age of three months

At the age of 4.5 months, abdominal computed tomography was performed, followed by open abdominal biopsy a week later and a port (long-term intravenous access) was placed and hepatoblastoma was diagnosed. The Bobath neuro-developmental treatment (NDT) and CMC rehabilitation had to be suspended.

At the age of 5 months, due to the high values of the alpha fetoprotein (AFP) marker, the child received the first dose of chemotherapy. The next three doses were administered every two weeks. After 3 months of treatment, hepatoblastoma was operated at the age of 7 months. Two weeks after surgery, the child received next

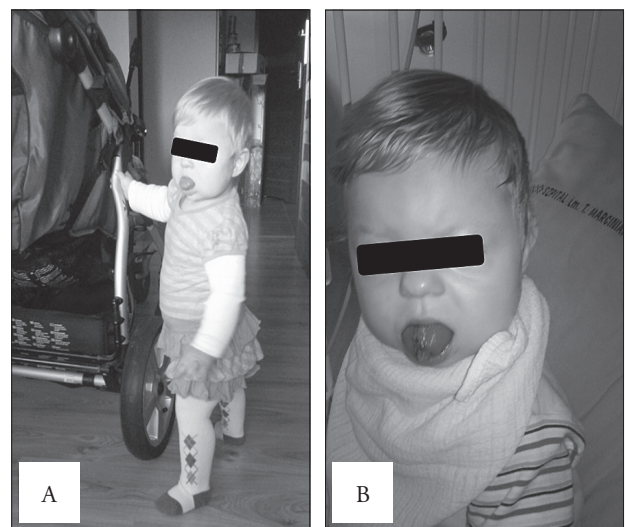


Figure 2. The girl at the age of thirteen months: before (A) and after tongue surgery (B)

two doses of chemotherapy. Computed tomography was performed, and due to the high value of AFP, magnetic resonance imaging.

AFP levels decreased in the ninth month. At the age of 13 months the girl was operated to reduce her tongue. On the tenth day after surgery, she was operated again due to dehiscence (Figure 2).

#### *Continuing the Procedure at the Age of 11 and 12 Months of Life*

Initially, the girl was very distrustful, fretful, requiring a very gentle approach and touch, but after a very short time became active and willing to cooperate. The CMC therapy was continued because of enlarged tongue. Psychomotor development was assessed at the age of 12 months using the Munich Functional Developmental Diagnostics (MFDD).

In terms of gross motor skills, the child tried to stand up and control the balance. She smoothly changed the position of the body and ways of moving. The girl crawled and then stood up and with some support made her first steps. She bent over for toys with assistance. She overcame obstacles when crawling in a familiar room.

In terms of fine motor skills and lateralization, she touched the toy buttons with her fingers, grabbed the beads on the string with her whole hand, was very curious about the tasks, however cautious about their performance.

In terms of speech development, the girl showed very good understanding, she followed the commands: insert, pull out, give, take, give it to your mommy, show

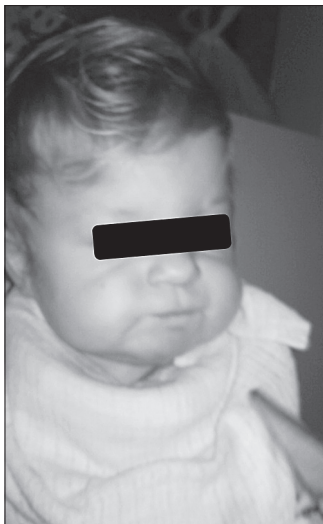

Figure 3. The girl at the age of fourteen months with improved jaw control

a dog, cat, boy, mug etc., she named things pointing with her finger, but verbally showed very little activity. She tried to eat with her hands, but she was very careful.

She drank and ate from the bottle and was fed with a spoon. The girl showed better control of movement and maintenance of the jaw position (Figure 3).

#### *Continuing the Procedure Between the Age of 14 and 24 Months of Life*

Physical rehabilitation and speech therapy were conducted in the second year of life on a regular basis. The girl was very active in her physical activity. At first, during speech therapy sessions she was not willing to allow us to teach eating and drinking or do any treatments connected with her face. Numerous attempts were made to teach self-feeding. Initially, after the operation, she was fed with ready-to-eat jars, after some time enriched the menu with cooked vegetables, quail eggs, steamed apples, mashed apples, rabbit meat, broccoli and carrots and sweet potatoes with a small amount of olive oil. The food was mashed with a spoon or crushed with a fork. After a few months of practice, it became a very good element to improve the tongue activity and self-feeding. During chewing the tongue and oral cavity presented very good patterns of eating, the tongue was sporadically protruded (Figure 4).

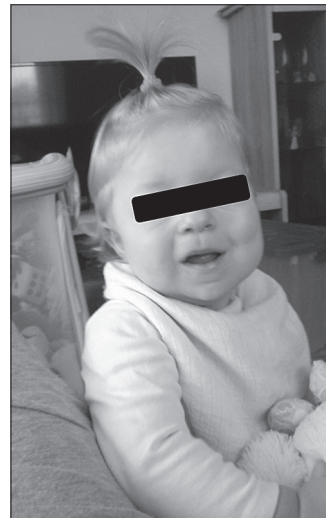

Figure 4. The girl at the age of fifteen months

At the age of 20 months, the child was able to eat regular meals from a plate with hands. Drinking from a cup posed a bigger problem. At first the girl drank from a bottle, but due to the habitual sucking and tendency to a greater tongue protrusion, first she was introduced to drinking thickened beverage from a teaspoon and then from a container with a silicone tube. The use of this container proved to be an effective way of learning to drink and gradually start bottle weaning. At the same time, attempts were made to continue drinking from a teaspoon and a cup. At present, the girl eats without assistance and drinks from a bottle and

tries to drink more often from a cup. She has difficulties in tightening the upper lip and sucking during drinking. The tongue, despite the operation, is still too big, which is a major difficulty in drinking but also in the development of verbal communication. As a part of speech therapy, alternative elements of communication were used, namely, pictograms, pictures, gestures, phonogestures, paediatric ergotherapy and music therapy. Music therapy specifically turned out to be apt and allowed for more verbal activity.

Currently (24 months) the child is very active, curious about the world and new experiences. As far as gross motor skills are concerned, she runs, overcomes the obstacles, tries to ride a four-wheel bike pedalling, walks up and down the stairs with little assistance from her parents, climbs onto a chair, sits on it by herself.

In terms of manual dexterity, the girl can screw and unscrew a bottle cap and draw lines in both directions, string buttons with a large opening and can match different figures to appropriate places. On the other hand, when it comes to perception, the child finds objects hidden in certain places, stacks cups one into another, places a square, a triangle, and a large circle in the right place of the puzzle.

As for the age of speech and understanding of speech, she expresses wishes using specific sounds, when asked indicates objects, but does not name them verbally. She uses simple syllables. She can refuse to perform a task, more often by shouting than verbally. Points at actions on text images. Performs a command e.g. pick up a doll and put it on the table, bring it, leave it, she shows the selected item from among several pictures with items or activities.

Considering the development of the child in terms of social age, it can be observed that the child rolls the ball to her mother, helps to clean up, throws rubbish to the bin, performs simple commands in daily situations. She does not feel safe away from her mother. She tries to take care of physiological needs, takes off a cap, tries to put on socks. She can hold a cup and drink two sips without spilling, she stacks food on the fork, eats with a spoon some part of food from a plate.

At present, the procedure of another tongue operation is being considered, however, as the AFP levels increased again, the child must undergo check-up tests first.

## Discussion

The described girl met the diagnostic criteria proposed by Elliott et al. [4], Rump et al. [5], as well as Ibrahim et al. [6]. To diagnose BWS according to the above authors it is necessary to identify 3 major findings (macrosomia, macroglossia, omphalocele or umbilical hernia), or two major plus three minor findings (neonatal hypoglycaemia,

ear creases or ear pits, haemangioma, hemihyperplasia, renal abnormalities).

In terms of early logopedic intervention, the leading problem is the large tongue. BWS syndrome is commonly characterized by macroglossia [19–21]. The enlarged tongue causes functional, psychological and feeding problems [22]. Improper respiratory tract, dental protrusion, open bite, difficulty in swallowing, or jaw overgrowth are just some of the consequences of macroglossia. The major problem in the case of the studied child is weight and size of the tongue [23]. Despite surgery, the tongue reduction was insufficient. Another tongue surgery is being considered, but the changing levels of AFP delay the decision of another surgery.

One of the most useful appliances in the CMC speech therapy are the palatal plates which can stimulate the tongue, lip and masseter muscles. They facilitate closing the mouth and correct the wrong tongue and lips position. The purpose of their use is to improve nasal breathing and acquire physiological swallowing and sucking ability [24,25]. In the case of the described girl, the CMC method was used without the possibility of using palatal plates. The volume of the tongue completely prevented the use of the plate.

In Poland, orthodontic treatment methods do not provide palatal plates for children with BWS before surgery. Instead, appropriate feeding bottles or probe feeding are used until the surgery of the tongue [26]. Another consequence of the enlarged tongue is also the increased incidence of diseases and respiratory infections [22]. In the case of reported girl, it is difficult to teach social activities in a peer group because the child is often ill.

It is normal that the enlarged tongue affects the use of verbal communication. Surgical interventions is recommended as soon as possible only in the situation of apnoea and severe feeding problems [9,22,27]. However, tongue surgery is dependent on the child's health condition, body weight, and life threat which is assessed individually for each patient. It is also essential to include personalized speech therapy as soon as possible. Studies confirm that both children with BWS and trisomy of chromosome 21 which are characterized by macroglossia, improve the practiced functions during the speech therapy [28].

The described girl is currently before the second surgery of the enlarged tongue. After the first operation, no changes were observed in the perception of taste and phonation in the child, as opposed to the findings reported by Matsune et al. [22]. Also in this respect it will be necessary to observe the child after the next surgery.

The described child is currently characterized by retarded speech development, so it is impossible to

identify articular disorders. However, children with BWS who have the competence to verbalize thoughts usually have articulation disorders. A phonetic speech analysis of the children with syndrome conducted by Borsel et al. [29] showed that articulation disorder is mainly about consonants with a front articulation site, which resulted in dislocation of the lips and tongue.

The results of the study also show that after a surgery, comprehension of the speech improves, phonological skills develop, however training the correct position of the articulation organs is still necessary as the habit of the interdental tongue placement is persistent [30].

There is no doubt that the care of children with BWS requires an interdisciplinary team of specialists [31]. However, it should be stressed how important in the whole process is the role of speech therapist and early speech logopedic intervention in this team. The child needs not only proper physical development, but also correct interpersonal relationships built on verbal communication. Therapy should be started as early as possible before bad habits develop [28,32].

## Conclusions

Children with BWS develop in individual ways depending on the type of genetic cause and additional defects. The described case of the girl proves that the child, in spite of many defects, has a very good prognosis for psychomotor development. It is important to work continuously on verbal communication, which is retarded. The care of BWS children must involve permanent and interdisciplinary co-operation with many specialists.

## References

- [1] Beckwith J.B. Macroglossia, omphalocele, adrenal cytomegaly, gigantism, and hyperplastic visceromegaly. *Birth Defects Orig Artic Ser.* 1969;5(2):188–196.
- [2] Wiedemann H.R. Complexe malformatif familial avec hernie ombilicale et macroglossie — un ‘syndrome nouveau’? *J Hum Genet.* 1964;13:223–232.
- [3] Weksberg R., Shuman C., Beckwith J.B. Beckwith–Wiedemann syndrome. *Eur J Hum Genet.* 2010;18(1):8–14.
- [4] Elliott M., Bayly R., Cole T., Temple I.K., Maher E.R. Clinical features and natural history of Beckwith–Wiedemann syndrome: presentation of 74 new cases. *Clin Genet.* 1994;46(2):168–174.
- [5] Rump P., Zeegers M.P., van Essen A.J. Tumor risk in Beckwith–Wiedemann syndrome: A review and meta-analysis. *Am J Med Genet A.* 2005;136(1):95–104.
- [6] Ibrahim A., Kirby G., Hardy C. et al. Methylation analysis and diagnostics of Beckwith–Wiedemann syndrome in 1,000 subjects. *Clin Epigenetics.* 2014;6(1):11.
- [7] Kalish J.M., Biesecker L.G., Brioude F. et al. Nomenclature and definition in asymmetric regional body overgrowth. *Am J Med Genet A.* 2017.
- [8] Maas S.M., Vansenne F., Kadouch D.J. et al. Phenotype, cancer risk, and surveillance in Beckwith–Wiedemann syndrome depending on molecular genetic subgroups. *Am J Med Genet A.* 2016;170(9):2248–2260.
- [9] Mussa A., Russo S., de Crescenzo A. et al. Fetal growth patterns in Beckwith–Wiedemann syndrome. *Clin Genet.* 2016;90(1):21–27.
- [10] Śmigiel R., Misiak B., Szaśniadek M. Zespoły genetyczne charakteryzujące się nadmiernym wzrostem — aspekty kliniczne i poradnictwo genetyczne. *Prz Pediatr.* 2008;38(2):121–129.
- [11] Shuman C., Beckwith J.B., Weksberg R. Beckwith–Wiedemann Syndrome. In: Adam M.P., Ardinger H.H., Pagon R.A. et al. (Ed.), *GeneReviews*® [Internet]. Seattle (WA): University of Washington, Seattle 1993–2019.
- [12] Lebidzińska A., Midro A.T. Genetic counseling in Beckwith–Wiedemann syndrome. Part II. Assessment of probability rate of recurrence of BWS and genetic prognosis. *Pediatr Pol.* 2008;83(5):535–543.
- [13] Reik W., Walter J. Genomic imprinting: parental influence on the genome. *Nat Rev Genet.* 2001;2(1):21–32.
- [14] Jurkiewicz D., Kugauo M., Skórka A. et al. A novel IGF2/H19 domain triplication in the 11p15.5 imprinting region causing either Beckwith–Wiedemann or Silver–Russell syndrome in a single family. *Am J Med Genet A.* 2017;173(1):72–78.
- [15] Cooper W.N., Luharia A., Evans G.A. et al. Molecular subtypes and phenotypic expression of Beckwith–Wiedemann syndrome. *Eur J Hum Genet.* 2005;13(9):1025–1032.
- [16] Choufani S., Shuman C., Weksberg R. Beckwith–Wiedemann syndrome. *Am J Med Genet C Semin Med Genet.* 2010;154C(3):343–354.
- [17] Brioude F., Netchine I., Praz F. et al. Mutations of the Imprinted CDKN1C Gene as a Cause of the Overgrowth Beckwith–Wiedemann Syndrome: Clinical Spectrum and Functional Characterization. *Hum Mutat.* 2015;36(9):894–902.
- [18] Demars J., Rossignol S., Netchine I. et al. New insights into the pathogenesis of Beckwith–Wiedemann and Silver–Russell syndromes: contribution of small copy number variations to 11p15 imprinting defects. *Hum Mutat.* 2011;32(10):1171–1182.
- [19] Reish O., Lerer I., Amiel A. et al. Wiedemann–Beckwith syndrome: further prenatal characterization of the condition. *Am J Med Genet.* 2002;107(3):209–213.
- [20] Clauser L., Tieghi R., Polito J. Treatment of macroglossia in Beckwith–Wiedemann syndrome. *J Craniofac Surg.* 2006;17(2):369–372.
- [21] Kittur M.A., Padgett J., Drake D. Management of macroglossia in Beckwith–Wiedemann syndrome. *Br J Oral Maxillofac Surg.* 2013;51(1):e6–8.
- [22] Matsune K., Miyoshi K., Kosaki R., Ohashi H., Maeda T. Taste after reduction of the tongue in Beckwith–Wiedemann syndrome. *Br J Oral Maxillofac Surg.* 2006;44(1):49–51.

- [23] Wang J., Goodger N.M., Pogrel M.A. The role of tongue reduction. *Oral Surg Oral Med Oral Pathol Oral Radiol Endod.* 2003;95(3):269–273.
- [24] Limbrock G.J., Hoyer H., Scheying H. Regulation therapy by Castillo-Morales in children with Down syndrome: primary and secondary orofacial pathology. *ASDC J Dent Child.* 1990;57(6):437–441.
- [25] Castillo-Morales R., Brondo J., Hoyer H., Limbrock G.J. Treatment of chewing, swallowing and speech defects in handicapped children with Castillo-Morales orofacial regulator therapy: advice for pediatricians and dentists. *Zahnärztl Mitt.* 1985;75(9):935–942, 947–951.
- [26] Matthews-Brzozowska T., Kawala B. (Red.), *Wpływ wad wrodzonych i nabytych części twarzowej czaszki na mowę.* Uniwersytet Medyczny we Wrocławiu, Wrocław 2012.
- [27] Boku A., Tachibana K., Shinjo T., Hanamoto H., Takeuchi M., Kinouchi K. Perioperative management of tongue reduction surgery for macroglossia associated with Beckwith–Wiedemann syndrome — A retrospective evaluation of 14 patients. *Masui.* 2013;62(4):416–420.
- [28] Anichini C., Lotti F., Cencini A., Caruso G., Stortini G., Spinelli M. Macroglossia as a Cause of Atypical Swallowing: Comparison of Evaluation and Logopedic Treatment between Beckwith–Wiedemann and Down Patients. *J Siena Acad Sci.* 2013;5(1):75–79.
- [29] Van Borsel J., Morlion B., Van Snick K., Leroy J.S. Articulation in Beckwith–Wiedemann Syndrome: Two Case Studies. *Am J Speech Lang Pathol.* 2000;9(3):202–213.
- [30] Van Lierde K., Galiwango G., Hodges A., Bettens K., Luyten A., Vermeersch H. Impact of tongue reduction on overall speech intelligibility, articulation and oromyofunctional behavior in 4 children with Beckwith–Wiedemann syndrome. *Folia Phoniatr Logop.* 2012;64(2): 55–63.
- [31] Narea Matamala G., Fernández Toro Mde L., Villalabeitia Ugarte E., Landaeta Mendoza M. Beckwith Wiedemann syndrome: presentation of a case report. *Med Oral Patol Oral Cir Bucal.* 2008;13(10):E640–643.
- [32] de Lavra-Pinto B., Luz M.J., Motta L., Gomes E. Beckwith–Wiedemann syndrome: case report of speech therapy intervention. *Rev CEFAC.* 2011;13(2):369–376.

---

**Corresponding Author:**

Robert Dymarek  
 Department of Nervous System Diseases  
 The Faculty of Health Sciences  
 Wrocław Medical University,  
 Bartla Street 5, 51-618 Wrocław, Poland  
 e-mail: r.dymarek@gmail.com

**Conflict of Interest:** None

**Funding:** None

**Author Contributions:** Teresa Kaczan<sup>A-I</sup>, Robert Śmigiel<sup>A-I</sup>, Magdalena Kazimierska-Zajac<sup>A-H</sup>, Robert Dymarek<sup>F-H</sup>, Joanna Rosińczuk<sup>A-I</sup>

(A — Concept and design of research, B — Collection and/or compilation of data, C — Analysis and interpretation of data, D — Statistical analysis, E — Writing an article, F — Search of the literature, G — Critical article analysis, H — Approval of the final version of the article, I — Acquisition of assets [eg financial])

**Received:** 29.11.2018

**Accepted:** 21.12.2018