

REVIEW / PRACA POGLĄDOWA

Małgorzata Frankowska-Rutkowska, Joanna Górską, Marek Jedwabiński, Dariusz Mańkowski, Marcin Maciejewski

**FRACTURE OF THE HUMERUS DURING ARM WRESTLING:  
REPORT ON 9 CASES AND REVIEW  
OF THE LITERATURE.****ZŁAMANIA KOŚCI RAMIENNEJ PODCZAS SIŁOWANIA SIĘ NA RĘKĘ:  
ANALIZA 10 PRZYPADKÓW KLINICZNYCH  
I PRZEGLĄD PIŚMIENNICTWA.**Department of Orthopedics and Traumatology,  
Ludwik Rydygier College of Medicine in Bydgoszcz, Nicolaus Copernicus University in Torun.  
Acting Head: Marek Jedwabiński, Phd**S u m m a r y**

Arm wrestling has become a popular sport practiced by both professionals and amateurs. Its popularity comes from the fact that the rules are simple; it is spectacular and does not require use of complicated equipment. In the years 2001 to 2013 ten cases of humeral bone fractures resulting from arm wrestling were admitted to the Department of Orthopaedics and Traumatology of the dr Jurasz University Hospital in Bydgoszcz. The assessment of the limb condition included the examination of the fractured extremity and an interview. All

the patients underwent surgical treatment, using the method of open reduction and internal fixation. The aim of this work was to perform a biomechanical analysis of forces which act during arm wrestling, as well as explain the mechanism of occurrence of humeral bone fractures of similar topology as observed on X-rays.

**S t r e s z c z e n i e**

Siłowanie się na rękę jest popularnym sportem uprawianym na całym świecie zarówno przez amatorów jak i przez profesjonalistów. O popularności dyscypliny decyduje: prostota zasad, minimalne wymagania sprzętowe oraz widowiskowość. W latach 2001 - 2013 w Katedrze i Klinice Ortopedii Szpitala Uniwersyteckiego CM UMK w Bydgoszczy leczono 10 - ciu chorych z powodu złamania kości ramiennej, które nastąpiło podczas siłowania się na rękę. Ocena stanu kończyny przed leczeniem operacyjnym obejmowała badanie podmiotowe i przedmiotowe. Wszyscy chorzy leczeni byli operacyjnie,

metodą otwartej repozycji i stabilnym zespoleniem złamania. Celem pracy było wyjaśnienie mechanizmu powstawania złamań kości ramiennej podczas siłowania się na rękę o powtarzającej się topografii.

**Key words:** Arm wrestling, humeral fractures, radiological analysis.

**Słowa kluczowe:** Siłowanie się na rękę, złamania kości ramiennej, analiza radiologiczna, zespolenie wewnętrzne.

## INTRODUCTION

Arm wrestling has become a popular sport practiced by both professionals and amateurs. Its popularity comes from the fact that the rules are simple; it is spectacular and does not require use of complicated equipment [1,2,3]. In the literature there have been reported several cases of humeral bone fractures and soft tissue damages [1,4,5,6,7,8,9,10]. In 1.8-18% of such cases, apart from the fracture, a radial nerve injury has also been observed [2,11,12,13,14].

The aim of this study was to explain the mechanism of humeral bone fractures of similar topology as observed on X-rays occurring during arm wrestling.

## MATERIAL AND METHODS

In the years 2001 to 2013 ten patients with humeral bone fractures resulting from arm wrestling were admitted to the Department of Orthopaedics and Traumatology of the dr Jurasz University Hospital in Bydgoszcz with purpose of the surgical treatment. Among them there were nine men and one woman. Their average age was 25.1 years and range 19 -41. In this group there were 9 men and 1 woman. Only one person, the woman, was a professional competitor. The other persons sustained injuries during 'home' challenges.

The assessment of the limb condition included an interview and the examination of the fractured extremity. X-rays of the antero-posterior and lateral projection were made in order to determine the type of fractures and the course of healing. AO Classification to determine the type of fractures was used.

In order to compare and analyze the types and locations of fractures, computer programs were used (Adobe Photoshop and Paint Microsoft Office) to make schemes of the fracture line course.

## RESULTS

### CLINICAL RESULTS

Upon being admitted all patients reported pain in the upper extremity, movement impairment of shoulder and elbow joints. Clinical examination revealed local swelling and bruising of the shoulder, a slightly asymmetric contour, severe pain during palpation, pathology of mobility, hematoma. In three cases radial nerve palsy was observed. Only one person during the fight had gained advantage over her opponent in the moment of injury. The other persons were in the defence while wrestling, when the fracture occurred.

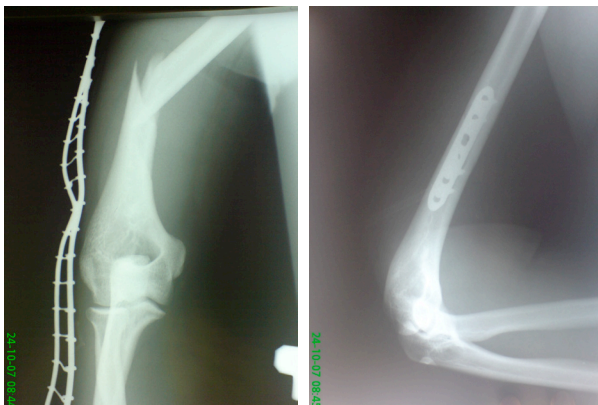

Fig.1 19 years old patient with spiral 1/3 distal humerus bone fracture.

Ryc.1 19-letni chory ze złamaniem spiralnym 1/3 dalszej kości ramiennej prawej.

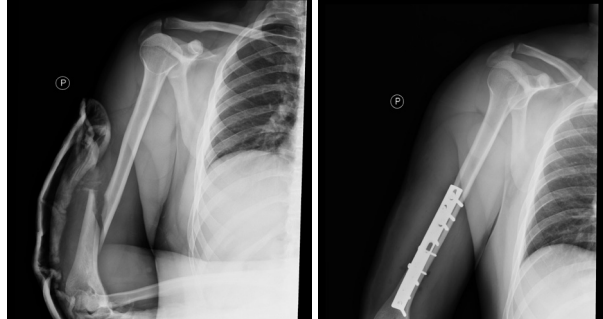


Fig 2 28-years old patient with spiral humerus fracture

Ryc.2 Chory 28-letni ze złamaniem spiralnym kości ramiennej

## RADIOLOGICAL RESULTS

Radiological assessment showed that in five patients a displaced spiral fracture of the distal third of the humerus were with large free, butterfly fragment. [Fig. 1] However in other 5 patients x-ray examination showed only a simple spiral fracture at the junction between the middle and distal one third of the humerus. [Fig. 2]. The exact computer analysis of fracture lines showed that in five cases with butterfly fragment the fractures were classified to 12-B1 type fracture according to AO classification and other five cases were classified to 12-A1 type [Fig. 3].

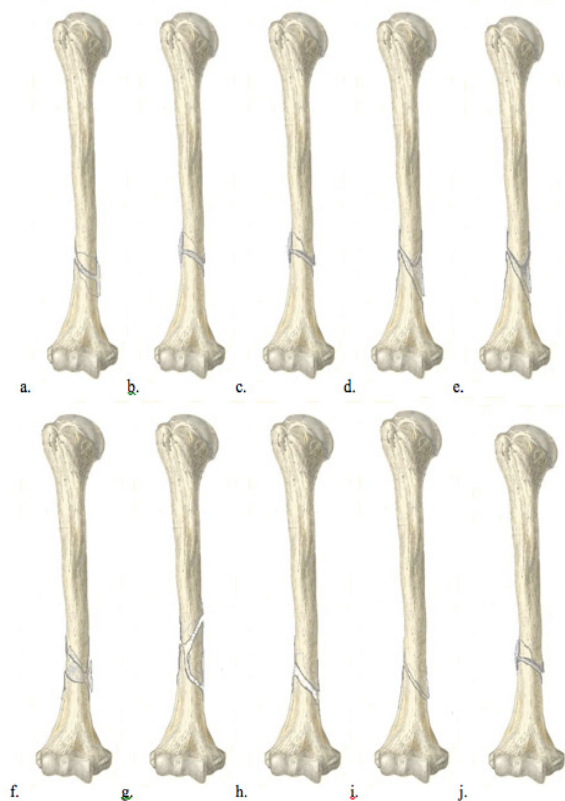


Figure 3. *The computer scheme of the fracture line courses in the analysed cases*

## SURGICAL MANAGEMENT

All the patients underwent surgical treatment, using the method of open reduction and internal fixation. One of the fractures was fixed with the traditional AO plate and screws; six were fixed with LCP plate and screws. The fixation with used only three cortical screws and additional external immobilization was applied in 1 patient. Also one of the spiral fractures without displacement was stabilized with ZESPOL device and the last of the patients was treated with ESIN wires. Three fractures were accompanied by the radial nerve impairment. The average time of hospital stay was 6 days and range from 2 to 17 days. There were no surgical complications with wound healing and the stability of fixation.

## DISCUSSION

Arm wrestling is a very simple and popular sport. Unfortunately, it can be the cause of serious fractures within the upper limb which has often been reported in literature. Ahcan et al. have discussed one case [1], Heilbronner et al. 2 cases [18], Moon et al. have described 7 cases [19] and Ogawa 30 cases [13]. Only in the material presented by Ogawa we have found an analysis of the shape and location of fractures. Our observations made on the base of 10 cases were similar to his conclusion according to type and location of fracture.

The humeral bone fracture mechanism during wrestling has been described by Brismar and Spangen [11] and supplemented by Ogawa [7,13]. They emphasize the humeral shaft occurs when moments of torsional forces are transmitted onto it. The effect of the indirect injury causes occurrence of fracture beyond the place of force application. Moments of these forces are the resultant of forces acting in the direction of external rotation (the opponent's force), and the resultant of forces acting in the direction of internal rotation (the competitor's force). In both cases the resultants of opposite directions occur thanks to work of internal rotator shoulder muscles (pectoralis major, m. latissimus dorsi, m. teres major and m. subscapularis). When the dominant competitor is in an attack, internal rotator muscles of the attacked person undergo rapid stress, from their maximum concentric contraction to eccentric passive compensatory relaxation, causing increase of the humeral bone rotational force. This results in transmission of the stress through the distal part of the arm and elbow resulting in shifting the maximum force on the humeral bone and its fracture. Rotating forces cause rotation around the long axis and slight push within the transverse plane and combination of compression and tension maximum within the plane of 45 degrees from the long axis. In the mechanism described and accepted for analysis we used forces with values and action courses characteristic for the following muscles: m. deltoideus, biceps brachii, brachialis, subscapularis, pectoralis major. It was assumed that during wrestling these muscles undergo maximum contraction.

Only in Ogawa's series (13) we have found an analysis of competitors' strength advantage. Among the 30 competitors with humeral fractures, their opponents were

weaker in 4 cases, in 17 cases opponents were of similar power and in 7 cases opponents were bigger and stronger. A moment before the fracture occurrence 17 persons were in the phase of indirect fight, 9 were losing, and 4 were winning. In the earlier reports it was stated that the advantage, as well as the fight phase do not have an influence on the occurrence of the competitor's humeral bone fracture [7,13,14,20]. In our group of patients only one of the competitors had significant advantage over the opponent and was winning the fight when the fracture took place. The other persons were in the defence. Despite the advantage of losers' in our material it isn't possible to draw unambiguous conclusions referring to dependence between the fracture moment and the phase of struggle and the opponent advantage because of the relatively small group of patients.

## CONCLUSIONS

1. Typical injury of the humeral bone in the consequence of arm wrestling is a spiral fracture of 1/3 distal shaft with or without the free, butterfly fragment.
2. 30% of lesion of the radial nerve in our material was higher about 12 to 28% to describe in earlier papers.
3. With consideration of the unstable character of fracture method of the open reduction with stable internal fixation was fulfilling requirements of modern trauma surgery and anticipating needs of young, active patients.

## REFERENCES:

1. Ahcan U, Ales A, Zavrsnik J. Spiral humeral fracture from arm wrestling. *European Journal of Trauma* 2000; 26: 308 - 311.
2. Chao SL, Molier M, Teg SW, A mechanism of spiral fracture of the humerus. Report of 129 cases following the throwing of-hand-grenades. *European Journal of Trauma* 1971; 11: 602 .
3. Ahcan U, Ales A, Spiral Fractures of the humerus caused by armwrestling. *European Journal of Trauma* 2000; 6: 308 - 311.
4. Biondi J, Bear TF, Isolated rupture of the subscapularis tendon in an arm wrestler. *Orthopedics* 1988; 11:647 - 649.
5. Khashaba A. Broken arm wrestler. *Br J Sports Med* 2000; 34: 461 - 462.
6. Nyska M, Peiser J, Lukiec F, et al, Avulsion fracture of the medial epicondyle caused by arm wrestling. *Am J Sports Med* 1992; 20: 347 - 350.
7. Ogawa K, UM, Fracture-separation of the medial humeral epicondyle caused by arm wrestling. *Journal of Trauma* 1996; 41: 494 - 497.
8. Pasquina PF, O'Connor FG. Olecranon fracture sustained in arm wrestling. *The Physician and Sports Medicine* 1999; 27: 81 - 83.
9. Whitaker JH, Arm wrestling fractures: a humeral twist. *Am J Sports Med* 1977; 5: 67 - 77.
10. Yavouz Y, Yurumez Y, Levent A, Spiral fracture of the humerus during arm wrestling. *The Medical Journal of Kocatepe* 2006; 7: 75 - 77.
11. Brismar B, Spangen L, Fracture of the humerus from arm-wrestling. *Acta Orthop. Scand* 1975; 46: 707 - 708.

12. De Barros JW, Oliviera DJ, Fractures of the humerus in arm wrestling. *Int Orthop*, 1995; 19: 390 - 391.
13. Ogawa K, UM, Humeral shaft fracture sustained during arm wrestling: report on 30 cases and review of the literature. *Journal of Trauma* 1997; 42: 243 - 246.
14. Owen TD, Humeral fractures in "arm wrestlers". *Br J Clin Pract* 1992; 46: 98 - 99.
15. Pennestri, Stefanelli R, Virtual musculo-skeletal model for the biomechanics analysis of the upper limb. *Journal of Biomechanics* 2007; 40: 1350 - 1361.
16. Taylor R, Zheng C, The phenomenon of twisted growth: Humeral torsion in dominant arms of high performance tennis players. *Computer Methods in Biomechanics and Biomedical Engineering* 2007; 6: 1–14.
17. Holzbaur KR, Murray W, Delp SL, Model of the upper extremity for simulating musculoskeletal surgery and analyzing neuromuscular control. *Annals of biomedical engineering* 2005; 6: 829–840.
18. Heilbronner DM, Manoli A, Morawa LG, Fractures of the humerus in arm wrestlers. *Clin Orthop* 1980; 149: 169-171.
19. Moon MS, Kim HH, Suh KH, Armwrestlers' injury, report of seven cases. *Clin Orthop* 1980; 146: 219 – 221.
20. Kruczyński J., Jaszczur Nowicki J., Topoliński T, Srokowski G, Mańko G, Chantsoulis M., Frankowska M., Frankowski P. Radiological and biomechanical analysis of humeral fractures occurring during arm wrestling. *Med Sci Monit*, 2012; 18(5): CR303-307

Address for correspondence:

Szpital Uniwersytecki Nr 1  
Klinika Ortopedii i Traumatologii Narządu Ruchu  
ul. M. Skłodowskiej-Curie 9, 85-094 Bydgoszcz  
Lek. med. Małgorzata Frankowska-Rutkowska

Received: 10.06.2013

Accepted for publication: 26.08.2013