

REVIEW / PRACA POGLĄDOWA

Joanna Górská, Marek Jedwabiński, Małgorzata Frankowska-Rutkowska, Marcin Maciejewski, Marian Grygiel

**RESULTS OF SURGICAL TREATMENT OF CARPAL TUNNEL  
SYNDROME BY MEAN OF AN OPEN  
AND SEMI - OPEN METHOD**

**WYNIKI LECZENIA OPERACYJNEGO ZESPOŁU  
CIEŚNI NADGARSTKA METODĄ OTWARTĄ  
ORAZ METODĄ PÓLOTWARTĄ**

Department of Orthopedics and Traumatology,  
Ludwik Rydygier College of Medicine in Bydgoszcz, Nicolaus Copernicus University in Torun.  
Acting Head: Marek Jedwabiński, Phd

**S u m m a r y**

The aim of this study was to compare outcome obtained using the two methods of surgical treatment of carpal tunnel syndrome (CTS) – the open method with the method of two incisions called ‘semi-open’. The material included 478 patients, with clinically diagnosed CTS, who were surgically treated in the Department of Orthopaedics and Traumatology CM in Bydgoszcz in years from 2001 to 2010. The minimum duration of the follow up was 6 months. We prepared for the study an observation card, which includes all data relating to the treatment and follow up. Analysis of the results of treatment

was based on pre and postoperative assessment of pain, touch resolution, static hand grip, strength, postoperative subjective assessment of treatment as well as EMG.

Results obtained were mostly good or very good comparable in both groups operating. In the subjective assessment, significantly better outcomes were obtained when using semi-open method. The surgical treatment of carpal tunnel syndrome confirmed by EMG test should be the method of choice.

**S t r e s z c z e n i e**

Celem pracy jest porównanie wyników leczenia, uzyskanych przy pomocy dwóch metod operacyjnego leczenia zespołu cieśni nadgarstka: metody otwartej z metodą dwóch cięć („półotwartą”). Materiał obejmuje 478 chorych, z rozpoznaniem klinicznie ZCN, operowanych w Klinice Ortopedii i Traumatologii Narządu Ruchu CM w Bydgoszczy w latach 2001-2010. Okres obserwacji wynosił minimum 6 miesięcy. Dla potrzeb badania przygotowano kartę obserwacji chorego, zawierająca wszystkie niezbędne dane dotyczące leczenia i obserwacji. Analizy wyników leczenia dokonano na podstawie przed- i pooperacyjnej oceny bólu, dotyku, statycznej rozdzielczości, siły chwytu ręki, pooperacyjnej

subiektywnej ocenie leczenia jak również badania EMG. Wnioski: 1. Uzyskane wyniki w zakresie danych obiektywnych w większości przypadków były dobre i bardzo dobre porównywalne w obu grupach operacyjnych. 2. W ocenie subiektywnej znacznie lepsze wyniki leczenia występowały w metodzie półotwartej. 3. Leczenie zespołu kanału nadgarstka potwierdzonego badaniem EMG powinno być z wyboru operacyjne

Ze względu na złożony problem, ZCN i jego następstwa oraz częste trudności stojące przed chirurgiem w czasie wyboru metody leczenia, wyniki badań powinny być pomocne w wyborze metody otwartej lub „półotwartej”.

**Key words:** carpal tunnel syndrome, the hand’s function, numbness, surgical treatment, EMG.

**Słowa kluczowe:** zespół cieśni nadgarstka, funkcja ręki, zaburzenia czucia, metoda otwarta leczenia operacyjnego, metoda „półotwarta”(dwóch cięć)

## INTRODUCTION

The diagnosis of carpal tunnel syndrome (CTS) along with an assessment of its severity and the effects of treatment is still very difficult despite development of diagnostic methods.

Since the time when Paget in 1865 described the chronic lesion of the median nerve within the carpal region as a consequence of long-lasting pressure, it has not yet developed the proper standard of management [1, 2, 3, 4]. The carpal tunnel syndrome is one of the most frequent reasons of the limitation of hand function [1, 4, 5, 6, 7]. If the pressure within the wrist is improperly diagnosed and treated, it is the reason for irreversible neuropathic changes in median nerve [7, 8]. However, the appropriate diagnosis and early surgical treatment is determining about reversing degenerative changes within this nerve [1, 4, 5, 6, 9, 10].

The aim of this study was to compare the outcome obtained using the two methods of surgical treatment of CTS – the open method with the method of two incisions call ‘semi-open’.

## MATERIAL AND A METHOD

In years from 2001 to 2010 in the Department of Orthopaedics and Traumatology CM in Bydgoszcz 478 patients were surgically treated with CTS. There were unilateral symptoms in 317 patients and bilateral in 161. In the study group there were 403 women and 75 men, in ages ranged from 18 to 85 years (~57+/-1.8).

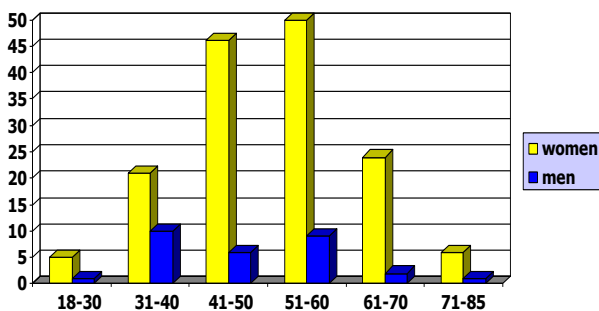


Figure 1. *The age and sex distribution of surgically treated patients.*

### Rycina 1. *Przedział wiekowy operowanych pacjentów.*

The duration of the observation was from 6 months to 6 years. Every patient admitted to the surgical treatment was registered by means of the patient medical study history elaborated in the clinic, which was also being led within a period of ambulatory care post-operative in the outpatient ambulatory.

Department of Orthopaedics and  
Traumatology CM in Bydgoszcz

Ward of Hand Surgery –

Name and surname: XXXXXXXXXXXXX

Hand ..... Right.....

Date of acceptance 01.09.2002r

Number of history of the disease: 123231/02

Age:55 years dominant hand P.(right)

P: abuse -> Cigarettes (about 10 daily)

Family history – irrelevant

Additional diseases-> diabetes, hypertension

Physical examination -> hand grip strength weakness, numbness especially at night time, limit of precision movements.

Examination-> hand grip strength weakness, superficial sensory disturbances within the median nerve provocation tests positive, positive test Weber.

The ulnar nerve innervations the median nerve

Pressed blood supply

Previous treatment – physiotherapy, topical steroids.

Clinical diagnosis – CTS right hand

Date of surgery – 4.09.2002y.

The type of surgery- decompression semi-open term follow-up-2 years

Objective assessment of outcome – satisfactorily

Subjective assessment of outcome- satisfactorily

Complications – not found

Figure 2. *The study patient medical history.*

### Rycina 2. *Karta pacjenta*

Evaluation of results of treatment was based on the criteria:  
-pain (Specifying its intensity with a 10 – point VAS scale:

0 w VAS – 5 points

1-2 w VAS – 4 points

3-4 w VAS – 3 points

5-6 w VAS – 2 points

7-8 w VAS – 1 point

9-10 w VAS – 0 points

- touch (in fairness feel so thick and soft touch investigated separately)

0 - bad result (without touch)

5 - very good result (connect perception)

- static resolution – (feeling separate points at a distance 3-6 mm – very good result,

7-9 mm – good result

10-12 mm – satisfactorily

13-15 mm – not satisfactory

>15mm – without effect.

- hand grip strength – (when making an objective assessment using the dynamometer and the results compared with the values in the tables laid out for the age, sex

0 - without effect

5 - very good result)

- Subjective assessment which was conducted according to the school grading scale

1 - without effect

5 - very good result, except for the targeted evaluation.

A comparative analysis of the course record EMG was performed. Each direction a nerve – conduction study was performed before and after surgery in a typical four –leads.

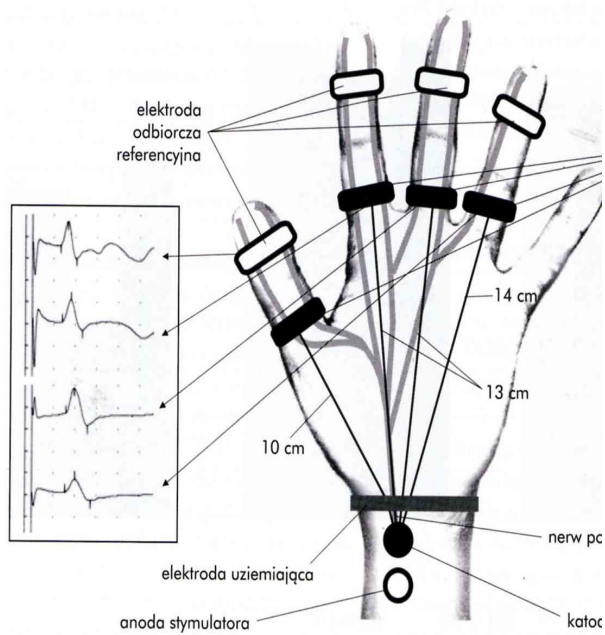


Figure 3. Four – taper scheme values obtained documented graphical record EMG.

Rycina 3. Schemat odprowadzeń czterobiegunowych [4,14]

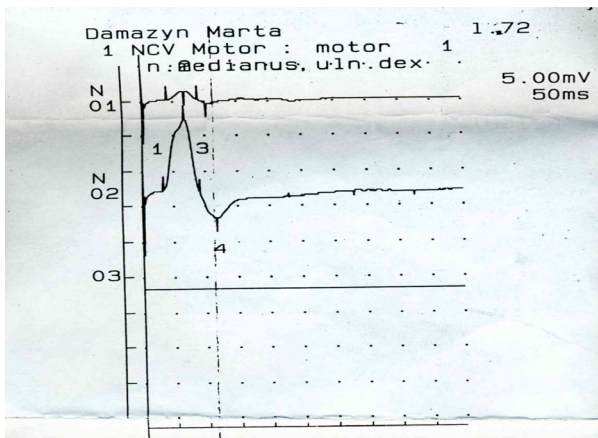


Figure 4. Example of preoperative result of EMG test.

Rycina 4. Przykład zapisu przed zabiegiem.

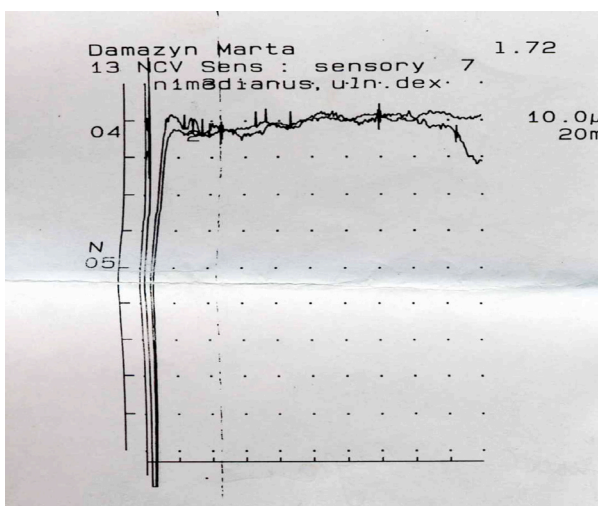


Figure 5. Example of postoperative result of EMG test.

Rycina 5. Przykład zapisu kontrolnego po zabiegu operacyjnym.

The open method in the surgical treatment was used in 285 patients with CLS, whereas semi-open method was used in 193. In the first type of method, the typical palmar approach was applied with the incision of transverse ligament of the wrist and the release of the compression of the median nerve within carpal tunnel. If there were clear coexisting symptoms of the nerve entrapment within the carpal tunnel the neurosis with saline was performed. (Fig. 6)

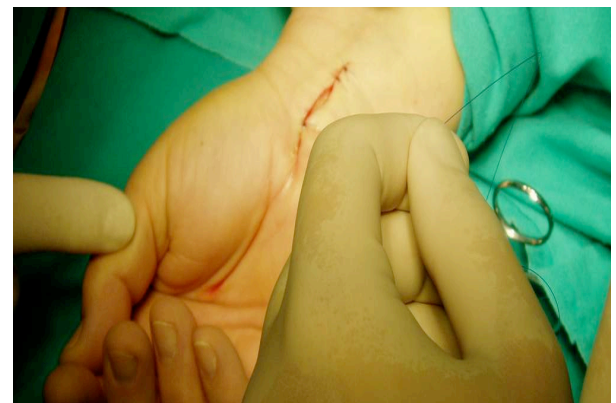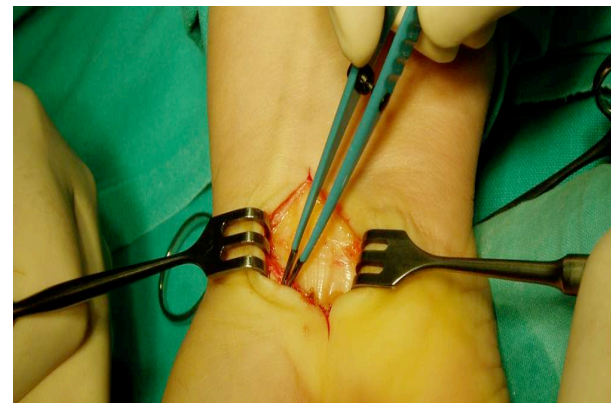
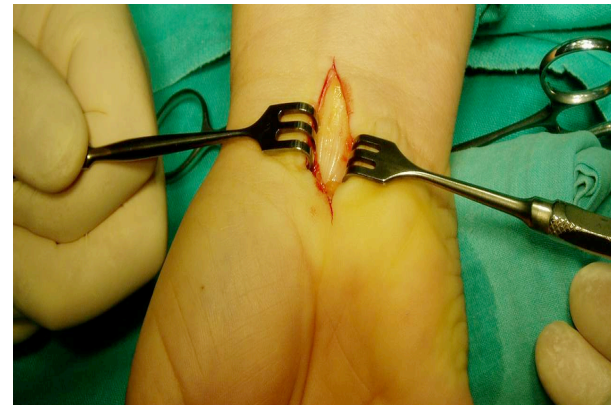


Figure 6. Initial stages of the open method of CTS decompression

Rycina 6. Poszczególne etapy metody otwartej odbarczenia ZCN.

The semi – open method was performed by centimetre skin incision done after the careful recognition of layers to the median nerve. After separating the transverse ligament from the median nerve the grooved elevator was inserted (Fig. 7) and then the transverse ligament was incised by means of an arthroscopic basket along this elevator in ulnar toward , to avoid a damage of the median nerve branches supplying the thenar muscles. (Fig 8)

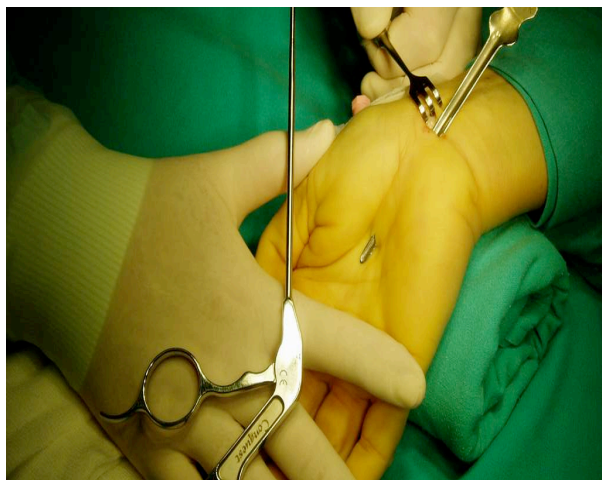
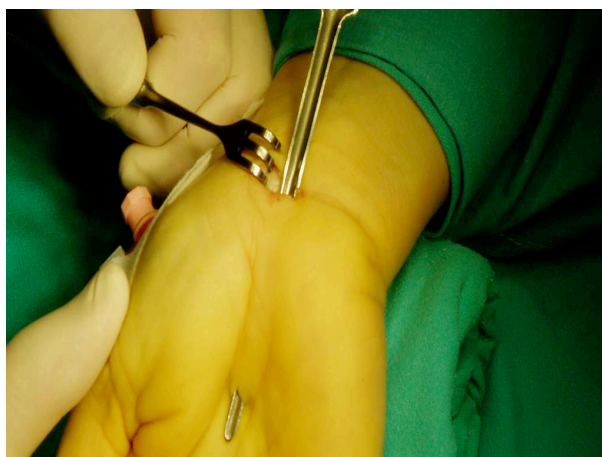
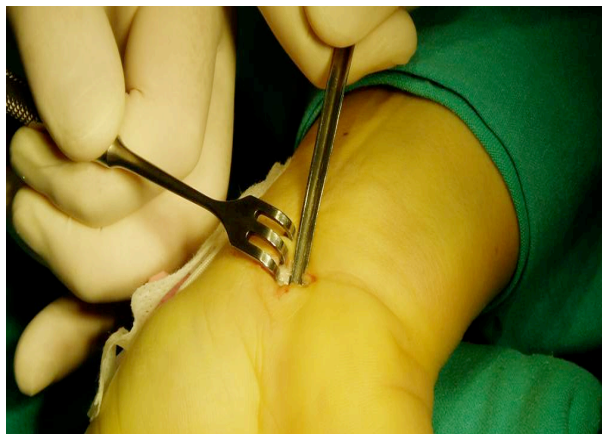


Figure7. Main part of semi – open decompression of CTS

Rycina 8. Właściwa część przecięcia więzadła poprzecznego w metodzie półotwartej odbarczenia ZCN

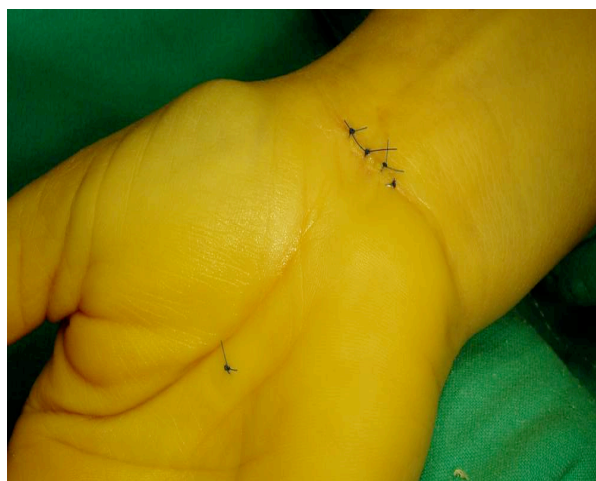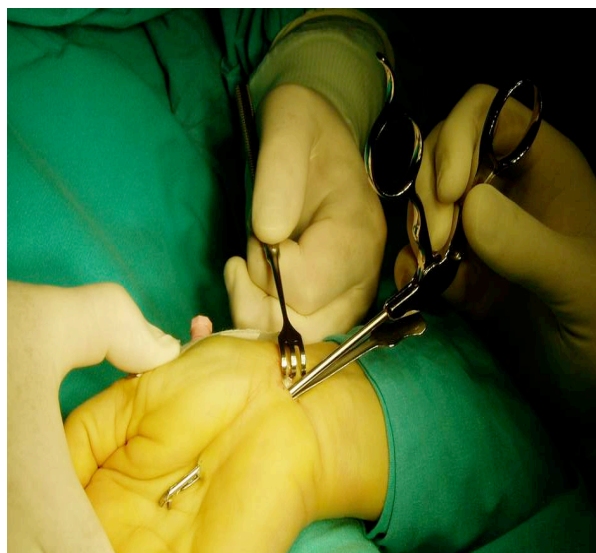
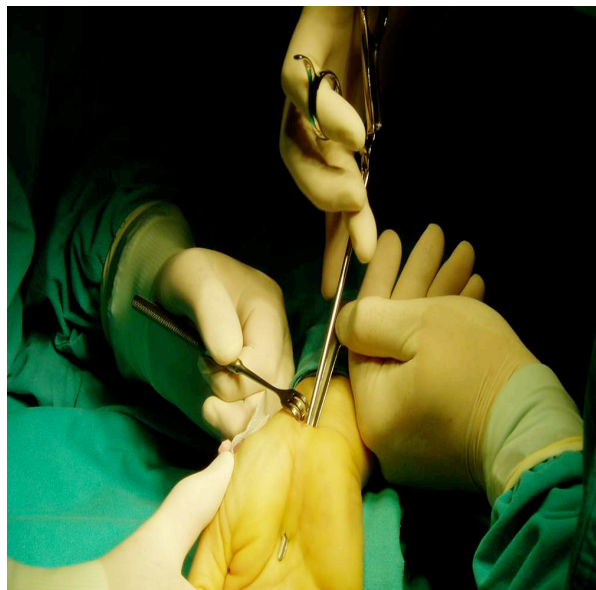


Figure 8. Semi-open method of successive stages of decompression CTS.

Rycina 8. Właściwa część przecięcia więzadła poprzecznego w metodzie półotwartej odbarczenia ZCN

## RESULTS

Outcomes of open surgery of 285 patients with diagnosed CTS according to five criteria are as follows:

Score	Very good	Good	Satisfactorily	Unsatisfactorily	Without effect
Pain	129	85	49	15	7
Thick touch	94	106	60	19	6
Delicate touch	67	99	86	25	8
Static resolution	99	51	94	34	7
Hand grip strength	125	80	34	25	21
Subjective evaluation	88	67	91	34	5
The average of all criteria	100,4(+21,3)	81,3(+18,5)	69(22,7)	25,3(+2)	9(+5,4)

Table I. Outcomes according to 5 criteria for 285 patients surgically treated with open method

Tabela I. Oceny wyników leczenia według pięciu kryteriów dla chorych (n=285) operowanych metodą otwartą

Similar evaluation of the 193 patients treated by means of "semi - open" method shown below (Tab. II)

Grade	Very good	Good	Satisfactorily	Unsatisfactorily	Without effect
Criteria					
Pain	113	48	21	8	3
Thick touch	70	44	59	17	3
Delicate touch	43	71	57	14	8
Static resolution	81	60	46	3	3
Hand grip strength	102	59	27	2	3
Subjective evaluation	139	51	-	-	3
The average of all criteria	91,4(+31)	55,5(+8,9)	35(+21,1)	7,3(+6,3)	3,8(+1,8)

Table II. Outcomes according to 5 criteria for patients (n=193) surgically treated with two incisions method

Tabela III. Zestawienie wyników średniej dla wszystkich kryteriów w obu grupach pacjentów z wynikami uzyskanymi w badaniu EMG.

## DISCUSSION

Surgical treatment of CTS still requires the development of standards of therapeutic conduct. Basically, there are 3 methods of treatment for carpal tunnel decompression standing at the traditional - open method by method of semi - open (two incisions method) ending with endoscopic surgery, which require an adequate endoscopic device and an experienced surgeon [3, 10, 11]. There is no doubt that the open method provides the best opportunity to open a correct movement by surgeon within anatomical structures of the wrist and reduce iatrogenic damages eventuality. So in long lasting entrapment syndromes, as well as in cases of the revision surgery of the recurrence of neuropathy, typical open method, allowing removal of adhesions and simultaneous median nerve neurolysis, should be the method of choice. The disadvantage

of this method is the creation of tenderness post-operative scar and the doubtful cosmetic result, evaluated absolutely negatively by patients [2, 3, 12]. Endoscopic method, which was introduced in 1989, is marked by the worse visual field of surgeon, and the procedure is also limited to the full incision of flexors retinaculum. However, it definitely gives the better result in patients' subjective evaluation. The disadvantage of this method is also the high cost of this procedure. In our study, we tried to present the semi-open method, as the 'middle ground' in the methods of treatment of carpal tunnel syndrome. This method, with high subjective assessment and the limited skin incision, produces also similar treatment results in the objective evaluation, in relation to the open method; simultaneously costs of both procedures are at the same level [2, 3, 13, 14].

## CONCLUSIONS:

1. The results of objective data in most cases were good or very good comparable in both operating groups.
2. In the assessment of subjective, significantly better results were there in the semi - open method.
3. Treatment of carpal tunnel syndrome confirmed by EMG study should be the choice of operating.

## REFERENCES:

1. Burke FD et al.: Relationship between the duration and severity of symptoms and the outcome of carpal tunnel surgery. The Journal of Hand Surgery 2006; 31A:9: 1478-1482.
2. Gerritsen AAM et al.: Systematic review of randomized clinical trials of surgical treatment for carpal tunnel syndrome. British Journal of Surgery 2001; 88: 1285-1295.
3. Giele H: Mini-symposium: nerve compression syndromes; Evidence-based treatment of carpal tunnel syndrome. Current Orthopaedics 2001; 15: 249-255.
4. Gunnarsson LG et al.: The diagnosis of carpal tunnel syndrome. The Journal of Hand Surgery 1997; 22B: 1: 34-37.
5. D'Arcy CA, McGee S: Does this patient have carpal tunnel syndrome? JAMA 2000; 283: 23: 3110-3117.
6. Graham B et al.: Development and validation of diagnostic criteria for carpal tunnel syndrome. The Journal of Hand Surgery 2006; 31A: 6: 919.e1-919.e7.
7. Rempel DM, Diao E: Entrapment neuropathies: pathophysiology and pathogenesis. Journal of Electromyography and Kinesiology 2004; 14: 71-75.
8. Dudley Porras AF et al.: Value of electrodiagnostic tests in carpal tunnel syndrome. The Journal of Hand Surgery 2000; 25B: 4: 361-365.
9. Kamath V, Stothard J: A clinical questionnaire for the diagnosis of carpal tunnel syndrome. The Journal of Hand Surgery 2003; 28B: 5: 455-459.
10. Nawrot P, Nowakowski A, Łabaziewicz L: Chirurgiczne leczenie neuropatii uciskowych kończyny górnej. Wydawnictwo Folium s.c., 2003; 37-46.

11. Klein R et al.: Open carpal tunnel release using a 1-centimeter incision: technique and outcomes for 104 patients. *Plastic and Reconstructive Surgery* 2003; 111: 5: 1616-1622.
12. Longstaff L et al.: Carpal tunnel syndrome: the correlation between outcome, symptoms and nerve conduction study findings. *The Journal of Hand Surgery* 2001; 26B: 5: 475-480.
13. Finse V, Russwurm H: Neurophysiology not required before surgery for typical carpal tunnel syndrome. *The Journal of Hand Surgery* 2001; 26B:1: 61-64.
14. Sharma V, Wilder-Smith EP: Self-administered hand symptom diagram for carpal tunnel syndrome diagnosis. *The Journal of Hand Surgery* 2004; 29B: 6: 571-574.

Address for correspondence:

Szpital Uniwersytecki Nr 1  
Klinika Ortopedii i Traumatologii Narządu Ruchu  
ul. M. Skłodowskiej-Curie 9, 85-094 Bydgoszcz  
Dr n. med. Joanna Górška

Received: 10.06.2013

Accepted for publication: 26.08.2013