

Zavgorodnya N. G., Novikova V. Yu. Prevention method of toric intraocular lens rotation after phacoemulsification of cataract using a standard capsule ring. *Journal of Education, Health and Sport*. 2021;11(2):171-181. eISSN 2391-8306. DOI <http://dx.doi.org/10.12775/JEHS.2021.11.02.017>  
<https://apcz.umk.pl/czasopisma/index.php/JEHS/article/view/JEHS.2021.11.02.017>  
<https://zenodo.org/record/4818582>

The journal has had 5 points in Ministry of Science and Higher Education parametric evaluation. § 8.2) and § 12.1.2) 22.02.2019.  
© The Authors 2021;

This article is published with open access at Licensee Open Journal Systems of Nicolaus Copernicus University in Torun, Poland  
Open Access. This article is distributed under the terms of the Creative Commons Attribution Noncommercial License which permits any noncommercial use, distribution, and reproduction in any medium, provided the original author (s) and source are credited. This is an open access article licensed under the terms of the Creative Commons Attribution Non commercial license Share alike. (<http://creativecommons.org/licenses/by-nc-sa/4.0/>) which permits unrestricted, non commercial use, distribution and reproduction in any medium, provided the work is properly cited.  
The authors declare that there is no conflict of interests regarding the publication of this paper.

Received: 11.01.2021. Revised: 10.02.2021. Accepted: 26.02.2021.

## PREVENTION METHOD OF TORIC INTRAOCULAR LENS ROTATION AFTER PHACOEMULSIFICATION OF CATARACT USING A STANDARD CAPSULE RING

**N. G. Zavgorodnya, V. Yu. Novikova**

**Zaporizhzhia State Medical University**

**Department of ophthalmology**

Zavgorodnya N.G., MD, PhD, DSc, Professor, chief of the Department of Ophthalmology of Zaporizhzhia State Medical University, Zaporizhzhia State Medical University, Zaporizhzhia, Ukraine  
ORCID ID [0000-0002-5678-4196](https://orcid.org/0000-0002-5678-4196)

Novikova V.Yu., Post-graduate student of the Department of Ophthalmology of Zaporizhzhia State Medical University, Zaporizhzhia State Medical University - Zaporizhzhia, Ukraine.

ORCID ID [0000-0002-6370-6348](https://orcid.org/0000-0002-6370-6348).

**Correspondence author:** Novikova Valeriia, [n.valeriya86@gmail.com](mailto:n.valeriya86@gmail.com), [+380957195192](tel:+380957195192)

### **Abstract**

At the same time, phacoemulsification of cataracts remains the most popular surgery. But the problem among phacosurgeons is the correction of existing corneal astigmatism. According to studies, about 30% of the world's population have corneal astigmatism with a strength of 0.75D and above, which leads to a decrease in visual acuity after phacoemulsification of cataracts in the absence of its correction.

The most commonly used method to correct corneal astigmatism is the implantation of toric intraocular lenses (TIOL). The main condition for obtaining high visual acuity after TIOL implantation is the location of the astigmatic component of the artificial lens in accordance with the strong meridian of the cornea. **The aim** of this study was to evaluate the effectiveness of the proposed method of preventing the toric intraocular lens rotation after

phacoemulsification of cataracts in the eyes with corneal astigmatism by implantation of a standart capsule ring.

**Material and methods.** The article presents the results of a comprehensive examination of 43 patients (59 eyes) who underwent surgery by phacoemulsification of cataracts with implantation of toric IOL to correct concomitant corneal astigmatism. Corneal astigmatism according to keratometry ranged from 0.5D to 4.25D (average  $1.96 \pm 0.1$  D). Patients were divided into 2 groups. The first group consisted of 26 patients (31 eyes). Patients in this group underwent phacoemulsification with toric IOL implantation according to standard techniques without the use of techniques that prevent rotation of the artificial lens in the postoperative period. The second group included 18 patients (28 eyes) who were operated on according to our proposed prevention method of TIOL rotation. As a **result** of the study, it was found that rotation of TIOL was detected 6 months after surgery in the I group without the use of developed method in 22 eyes (70.9%), in the II group, where the capsule ring was implanted, rotation occurred in 12 eyes (42.85%). In the II group in all cases, the deviation of the TIOL axis did not exceed 6 degrees. The proposed method of prevention of rotation of TIOL allows to increase the efficiency of phacoemulsification of cataracts.

**Conclusions.** Developed a method of preventing the rotation of the toric intraocular lens using a standard capsule ring, which is implanted and located on top of the haptic support elements of the artificial lens can increase the efficiency of phacoemulsification of cataracts in the eyes with corneal astigmatism, contributes to the rotational stability of the toric lens and provides long-term results of visual functions, reduces the need for repeated surgery due to reposition of the rotated lens and can be recommended for implementation in the practice of ophthalmic surgeons.

The use of implantation of a standard capsule ring according to the proposed in this study method prevents the rotation of the toric intraocular lens by more than 6 degrees in all cases, which does not significantly reduce visual acuity and does not require reposition of the artificial lens. This method of preventing rotation of the toric intraocular lens allows to achieve visual acuity of 0.7 and above in 85.6% of cases.

**Key words:** cataract; corneal astigmatism correction; cataract phacoemulsification; toric IOL.

## **Introduction**

Phacoemulsification of cataracts remains the most popular surgery. The advantage of this intervention is minimally invasive and high-tech. The rapid recovery period makes this

surgery safe and can be performed in an out-patient setting [1]. But the problem among phaco surgeons is the correction of existing corneal astigmatism. According to studies, about 30% of the world's population have corneal astigmatism with a strength of 0.75D and above, which leads to a decrease in visual acuity after phacoemulsification of cataracts in the absence of its correction [2].

The most commonly used method to correct corneal astigmatism is the implantation of toric intraocular lenses (TIOL). This technique provides a short rehabilitation period and high functional results [3, 4, 11, 12].

The main condition for obtaining high visual acuity after TIOL implantation is the location of the astigmatic component of the artificial lens in accordance with the strong meridian of the cornea. Deviation of these parameters by  $1^\circ$  leads to a decrease in the value of the cylindrical component of the lens by 3.3%. At a deviation of  $10^\circ$  - by 35% [5]. It is necessary to adhere intraoperatively to the exact orientation of the TIOL to the axis of astigmatism. Further, receipt of the high visual acuity in such eyes requires the stability of the implanted toric lens in the postoperative period. The occurrence of TIOL rotation in the distant period after surgery leads to a significant reduction in visual acuity and requires repeated surgery of reposition the intraocular lens.

Ophthalmic surgeons are developing new ways to stabilize toric intraocular lenses, such as the development and use of assistive techniques or tools. One of such tools is intracapsule rings [6, 7, 8].

Intracapsule stabilizing rings have been used in the practice of cataract surgeons for more than 20 years. They allow surgeons to increase the proportion of successful interventions on the lens, especially in complicated situations detected before surgery or intraoperatively, such as subluxation of the lens [8].

We have developed a method of preventing TIOL rotation using a standard capsule ring. The difference from the standard technique is that the ring is implanted in a capsule bag after implantation of TIOL, which is tentatively centered according to the strong meridian of the cornea. The ring is located on top of the haptic elements of TIOL (Patent of Ukraine on an useful model №145036, publ. 10.11.2020, Bull.№21) [9].

**The aim** of the work is to evaluate the effectiveness of the proposed method of preventing the toric intraocular lens rotation after phacoemulsification of cataracts in the eyes with corneal astigmatism by implantation of a standart capsule ring.

**Materials and methods.** The article presents the results of a study undertaken on the clinical basis of the Department of Ophthalmology ZSMU - in the clinic of modern

ophthalmology "VISUS". A comprehensive examination of 43 patients (59 eyes) who underwent surgery by phacoemulsification of cataracts with implantation of toric IOL to correct concomitant corneal astigmatism. Corneal astigmatism according to keratometry ranged from 0.5D to 4.25D (average  $1.96 \pm 0.1$  D). The number of patients ranged from 26 to 81. According to the sex, the studied patients were distributed almost equally: there were 22 men (51%) and 21 women (49%). Immature cataract was diagnosed in 30 eyes (51%), primary cataract in 22 eyes (37%), and mature cataract in 1 eye (2%). Refractive lens replacement was performed on 6 eyes (10%).

Toric intraocular lenses were implanted in all eyes: 27 of them - monofocal (AT TORBI 709M / MP (Carl Zeiss Meditec, Germany), AcrySof IQ Toric (Alcon, USA)), 14 - bifocal (AT LISA toric 909M) (Carl Zeiss Meditec, Germany) and AcrySof IQ ReSTOR (Alcon, USA) and 18 trifocal (AT LISA tri toric 909M (Carl Zeiss Meditec, Germany). All examined patients were operated on by surgeons whose individual induced astigmatism was not greater than 0.25D. The tunnel section was performed in the standard meridian in accordance with 160-180 degrees. In all cases, the operation and the postoperative period proceeded without complications. Operated patients were observed for 6 months after surgery.

Patients were divided into 2 groups. The first group consisted of 26 patients (31 eyes). Patients in this group underwent phacoemulsification with toric IOL implantation according to standard techniques without the use of techniques that prevent rotation of the artificial lens in the postoperative period. The second group included 18 patients (28 eyes) who were operated on according to our proposed prevention method of TIOL rotation [9].

All patients underwent the following series of examinations before and after the operation: visual acuity determination, autorefractometry on an automatic refractometer URK 700, biomicroscopy, ophthalmoscopy, perimetry, tonometry, ultrasound linear and two-dimensional scanning on the PACSCAN device using the CLAN 300A -3000P, optical biometrics and IOL calculation on the IOLMaster700 device. Visual acuity was determined for the Snellen table, the results are presented in articles. Additional calculation of toric IOL was performed using the Verion® device (Alcon, USA) and the online calculator "Z CALC Online IOL Calculator" (Carl Zeiss, Germany).

Statistical processing of the obtained results was performed using the software package Statistica 13.0 (license number JPZ8041382130ARCN10-J). The calculation of the arithmetic mean of the variation series (M) and its standard error (m) was performed. Student's t-test was used to compare quantitative values in even series. Previously, the

hypothesis about the normality of the distribution of variables in the variation series was tested. In the absence of such a distribution of values in the studied samples, the nonparametric Mann-Whitney test was calculated.

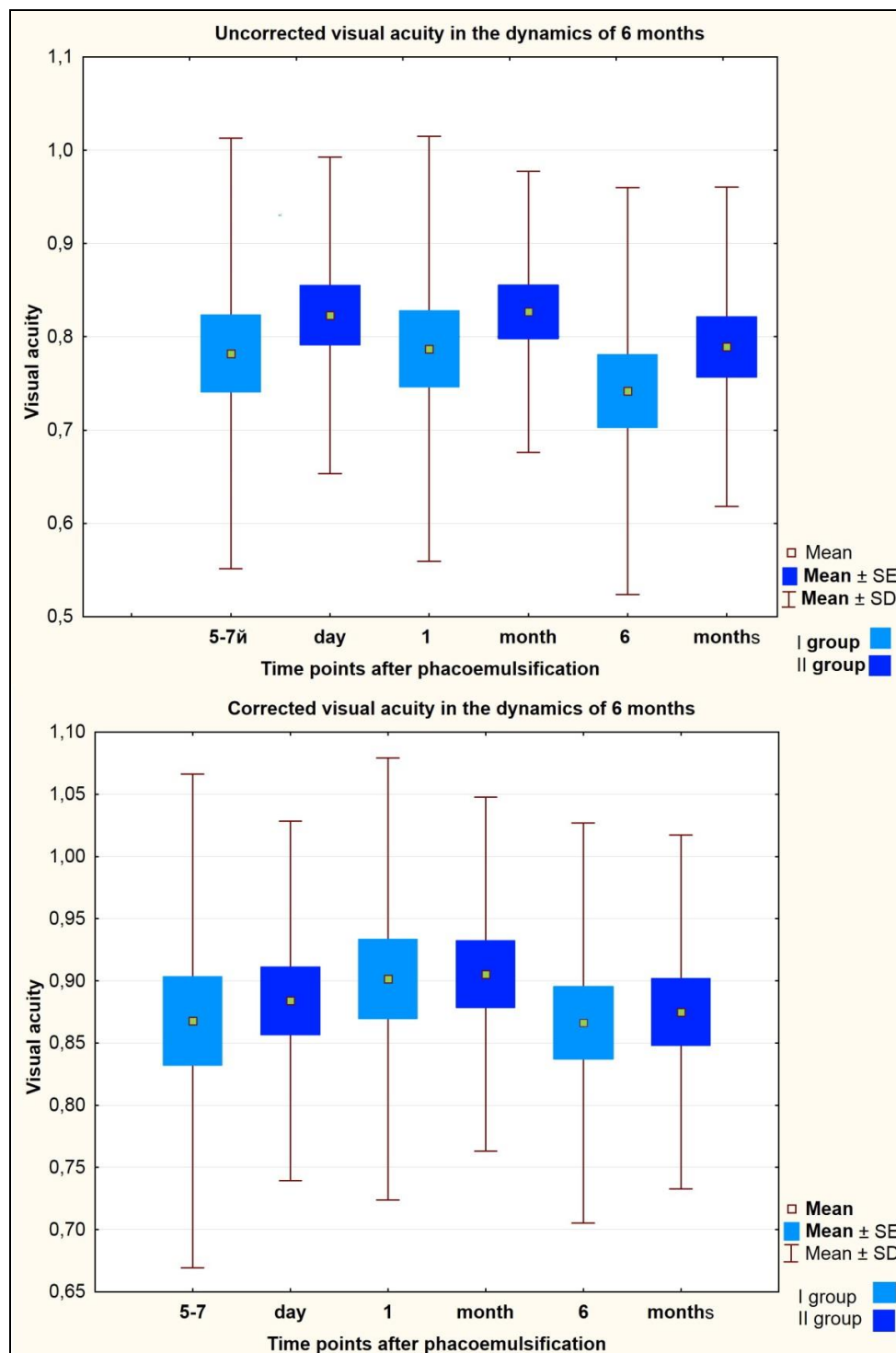


Fig.1 Average visual acuity after FEC with TIOL implantation in the observation groups after 5-7 days, 1 month and 6 months. Postoperatively

Note: the statistical difference with the corresponding indicators between the groups in all cases is not significant,  $p > 0.05$ .

**Results.** The main success rate of surgical treatment of cataracts in patients with concomitant corneal astigmatism is high visual acuity without the use of additional cylindrical correction. It is important to maintain functional parameters in the remote postoperative period, which is achieved by the stability of the TIOL position in the capsule bag in accordance with the axis of implantation. The dynamics of changes in the average visual acuity after surgery is presented in Figure 1 in the first and second groups of the study.

The above diagrams show that the average visual acuity in the groups differs within 0.1. It is also noteworthy that the run-up of results, which are represented by the mustache of the amplitude scale - is smaller in the second group, where was used the prevention of TIOL rotation - implantation of an intracapsular ring. It is also seen that the difference in the average visual acuity without the use of additional correction increased with the term after surgery.

6 months. after the operation, the average indicators of visual acuity without correction in the first group -  $0.74 \pm 0.03$ , in the second -  $0.78 \pm 0.03$ . In the first group, 41.93% (13 eyes) had maximum visual acuity (0.9 and above) for 6 months after surgery, and 45.16% (14 eyes) did not need correction to improve the refractive result. In 4 cases (12.9%) was applied spherical correction, in 12 eyes (38.7%) - cylindrical, in 1 eye (3.2%) - sphero-cylindrical.

In the group where an additional intracapsular ring was implanted on top of TIOL after 6 months visual acuity 0.9-1.0 was determined in 50.0% (14 eyes), in half of the cases (14 eyes) correction was not necessary to improve the refractive result. Spherical correction improved visual acuity in 4 eyes (14.2%), cylindrical correction in 5 eyes (17.8%), and in 5 cases sphero-cylindrical correction was required.

The stability of the TIOL position and the absence of its rotation are assessed by the dynamics of visual acuity and the correspondence of the lens axis position to the implantation axis according according to preoperative calculations. Below are the results of achieving high visual acuity in the observation groups at 1 and 6 months after surgery (Table 1).

As can be seen above: the proportion of eyes in the first group with visual acuity of 0.7 and above 1 month after surgery is 74.1% (23 eyes). 6 months after surgery it becomes slightly lower - 67.7% (21 eyes). In the second group, 1 month after surgery high visual acuity (0.7 and above) was detected in 24 eyes (85.6%). The difference between these indicators in the observation groups is not statistically significant ( $p > 0.05$ ). After 6 months a decrease in the total number of eyes with high visual acuity - 22 (78.5%) was caused by the development of secondary cataracts in 2 eyes from the second group.

Table 1.

Dynamics of changes in visual acuity in the eyes with cataracts and corneal astigmatism in the observation groups

| Terms of observation | Visual acuity                 |               |                             |              |                          |               |
|----------------------|-------------------------------|---------------|-----------------------------|--------------|--------------------------|---------------|
|                      | 0,9 – 1,0 (number of eyes, %) |               | 0,7-0,9 (number of eyes, %) |              | <0,7 (number of eyes, %) |               |
|                      | II group                      | I group       | II group                    | I group      | II group                 | I group       |
| 1 month              | 13<br>(46,4%)                 | 14<br>(45,1%) | 11<br>(39,2%)               | 9<br>(29,0%) | 4<br>(14,2%)             | 8<br>(25,8%)  |
| 6 months             | 14<br>(50%)                   | 13<br>(41,9%) | 8<br>(28,5%)                | 8<br>(25,8%) | 6<br>(21,42%)            | 10<br>(32,2%) |

The stability of the TIOL position in the capsule bag was analyzed. To assess this parameter, the axis of TIOL implantation and its position were compared 6 months after surgery. The position of the toric intraocular lens was evaluated using a slit lamp and the ratio of the light beam parallel to the marks on the artificial lens. Thus, 6 months after surgery, rotation of the intraocular lens was detected in 22 eyes (70.9%) in the first group, in second group - in 42.85% of cases (12 eyes). It is important that in the group without use of the rotation prevention, in 13 eyes (59% of all rotated) was detected deviation of the TIOL axis within 6 degrees or more. In the second group in all 12 cases (100% of cases) the axis of the lens implantation was up to 6 degrees.

Below there are the indicators of the deviation of the TIOL axis 6 months after surgery in the study groups (Fig. 2)

Therefore, it can be argued that the position of TIOL in the group where we used our proposed method with the intracapsular ring implantation was more stable, the intraocular lens retained its position better. The average deviation was  $2.14 \pm 0.4$  degrees (max -  $6^\circ$ , min -  $0^\circ$ ), which did not significantly impair visual function. In group I, the average deviation of the TIOL position -  $5.41 \pm 1.01$  degrees (max -  $30^\circ$ , min -  $0^\circ$ ) at implantation of multifocal TIOL led to a decrease in visual acuity and caused discomfort, diplopia and inability to distinguish small objects and font at close range. The difference between the mean deviations of the axis of the toric lens implantation in group II is statistically significant ( $p < 0,05$ ). It is important that in 2 cases patients from the first group of supervision required repeated surgical intervention - reposition of the rotated TIOL.

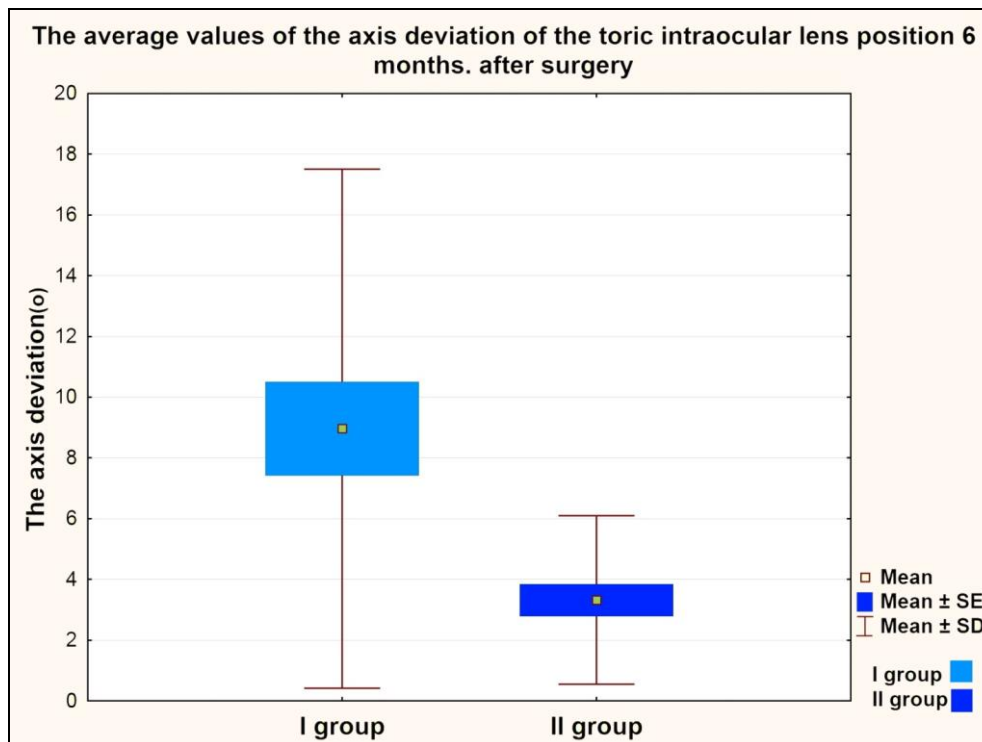


Fig.2. The average values of the axis deviation of the toric intraocular lens position 6 months. after surgery in the observation groups ( $p < 0,05$ ).

### Clinical case:

Patient D., born in 1961, was operated on with a clinical diagnosis: "Immature cataract, complex myopic astigmatism of the right eye." Preoperative index of corneal astigmatism according to keratometry: 2.75 D. TIOL - AT Torbi 709 M (Carl Zeiss Meditec, Germany) was implanted during the initial surgery. At the routine examination 1 month after surgery, the patient required the use of an additional cylindrical correction of 1.5D. It was found that the lens is rotated 30 degrees from the ascending position on the background of pronounced fibrous changes of the capsule bag. Visual acuity decreased to 0.5 without correction, with the use of additional correction sph -0.5D and cyl + 1.5D reached 1.0. From the subjective complaints, the patient noted: blurred vision, diplopia, dissatisfaction with the functional result of surgical treatment. The patient was operated again, reposition was performed: TIOL was returned to the correct position, according to preoperative calculation and stabilized using a standard open ring with a diameter of 13 mm with rounded ends, which was implanted in a capsule bag on top of the haptic elements of TIOL. On examination on the first day after surgery, visual acuity - 1.0 (using the diaphragm), intraocular pressure was normal, TIOL occupied the correct position in the capsule bag. 6 months. after repeated



surgery, visual acuity of the operated eye remains 1.0, intraocular pressure was normal, the position of the IOL was stable without signs of rotation.

### **Discussion**

Ophthalmic surgeons around the world are looking for ways to prevent rotation and ensure the stability of the position of the toric intraocular lens in the capsule bag according to its planned axis. G.A. Fedorov and V.V. Egorov developed a device for improving the rotational stability of implanted toric intraocular lenses. This device is represented by an open flat capsule ring having two hinges at the ends and a soft stopper in the form of a cylinder in the central part of the ring. After implantation, the ring is rotated in the capsule bag clockwise until the position of the stopper coincides with the mark on the cornea, indicating the position of the strong meridian of astigmatism. Next, a toric IOL is implanted in the capsule bag and rotated clockwise so that the base of its support element is located with emphasis in the silicone stopper [6]. This method reliably stabilizes TIOL, but has certain disadvantages: there is no well-established large-scale industrial production of this device, so the implementation of this method has a number of obstacles, there are also some difficulties in implanting the capsule ring. This is more pronounced with insufficient pupil diameter to visualize the silicone stopper and adhere to the correct axis of the implanted TIOL.

Other authors (Kuznetsov S.L. and Galleev T.R.) also developed a device modelled on the intracapsule ring type, the difference of which is the presence on its inner surface of elastic elements in the form of three teeth, which are used to fix the haptic element implanted further TIOL at the "paper clips" type [7, 8]. This method also has the disadvantages of the above previous device.

Interestingly, the works of Vokrojová M, Havlíčková L and others did not reveal the effectiveness of the capsule ring. The statistical difference was not confirmed in the rotational stability of the implanted lens with or without the presence of a capsule ring [10].

The positive data obtained in our study, which indicate greater rotational stability of the toric intraocular lens with the use of a standard capsule ring implantation are explained by the phased implantation of the lens and capsule ring. The technique developed and proposed for our use differs in that it additionally fixes the haptic elements of the lens with the capsule ring implanted on top of them. The obtained results and the given clinical example show that the use of an additional intracapsule ring according to the proposed method prevents the TIOL rotation in the capsule bag. In our opinion, this is due to the following two effects: the capsule ring stabilizes the capsule bag and prevents the development of fibrous processes and its

deformation; the additional ring pressure on the haptic elements of the intraocular lens also promotes rotational stability and prevents the free movement of TIOL in the capsule bag.

### **Conclusions**

1. Developed a method of preventing the rotation of the toric intraocular lens using a standard capsule ring, which is implanted and located on top of the haptic support elements of the artificial lens can increase the efficiency of phacoemulsification of cataracts in the eyes with corneal astigmatism, contributes to the rotational stability of the toric lens and provides long-term results of visual functions, reduces the need for repeated surgery due to reposition of the rotated lens and can be recommended for implementation in the practice of ophthalmic surgeons.

2. The use of implantation of a standard capsule ring according to the proposed in this study method prevents the rotation of the toric intraocular lens by more than 6 degrees in all cases, which does not significantly reduce visual acuity and does not require reposition of the artificial lens

3. This method of preventing rotation of the toric intraocular lens allows to achieve visual acuity of 0.7 and above in 85.6% of cases.

### **References**

1. Leaming, D. (2004), «Practice styles and preferences of ASCRS members — 2003 survey», *Journal of Cataract & Refractive Surgery*, 30, 892-900.

<https://doi.org/10.1016/j.jcrs.2004.02.064>

2. Hripun KV Surgical correction of astigmatism during and after cataract extraction. Extended abstract of candidate's thesis. Sankt-Peterburg, 2016. In Russian.

3. Melnyk VO. AcrySof IQ Toric implantation experience with cataract phacoemulsification in patients with a high degree of astigmatism. Scientific and practical conference with international participation "Filatov memorial lectures" 24- 25 May; Odessa; 2012. 74 p. In Ukrainian.

4. Mencucci R, Giordano C, Favuzza E, Gicquel JJ, Spadea L, Menchini U. Astigmatism correction with toric intraocular lenses: wavefront aberrometry and quality of life. *Br J Ophthalmol*. 2013 May;97(5):578-82.

5. Il'inskaya I.A., *Klinicheskie aspekty intraokulyarnoj korrekcii astigmatizma*. Extended abstract of candidate's thesis 14.01.07. 2014 Moskva. In Russian.

6. Fedorov G. A. Ustrojstvo dlya povysheniya rotacionnoj stabil'nosti toricheskikh IOL v kapsul'nom meshke posle provedeniya fakoemul'sifikcii. Sovremennye tekhnologii kataraktal'noj i refrakcionnoj hirurgii. 2011 In Russian. [https://eyepress.ru/article.aspx?9755\\_6](https://eyepress.ru/article.aspx?9755_6)
7. Kuznecov SL, Galleev TR. Implantacii vnutrikapsul'nogo kol'ca s elementami fiksacii IOL s ploskostnoj gaptiko. Eksperimental'no-klinicheskoe izuchenie. Vestnik OGU. 2010; 12:124-7. In Russian.
8. Kuznecov SL. Opyt primeneniya vnutrikapul'nyh stabiliziruyushchih kolec dlya fiksacii intraokulyarnoj linzy v optiko-rekonstruktivnoj hirurgii. Medicinskij vestnik Bashkortostana. 2014;9 (2): 101-4. In Russian.
9. Sposib profilaktyky rotatsii torychnykh intraokuliarnykh linz pislia fakoemul'sifikatsii katarakty na ochakh z rohivkovym astyhmazyzmom: pat. 145036 Ukraina: MPK A61F 9/00. №u202004231; zaiavl. 13.07.20; opubl. 10.11.20, Biul. №21. 4 s. In Ukrainian.
10. Vokrojová M, and Havlíčková L, Brožková M, Hlinomazová Z., (2020), «Effect of Capsular Tension Ring Implantation on Postoperative Rotational Stability of a Toric Intraocular Lens», Journal of Cataract & Refractive Surgery, 36(3), 186-192. <https://doi.org/10.3928/1081597X-20200120-01>
11. Koch DD, Jenkins RB, Weikert MP, Yeu E, Wang L. Correcting astigmatism with toric intraocular lenses: effect of posterior corneal astigmatism. J Cataract Refract Surg. 2013 Dec;39(12):1803-9.
12. Weinand F, Jung A, Stein A, Pfützner A, Becker R, Pavlovic S. Rotational stability of a single-piece hydrophobic acrylic intraocular lens: new method for high-precision rotation control. J Cataract Refract Surg. 2007 May;33(5):800-3.