

Droniak M. M. The results of a new approach to the method of modeling experimental postoperative peritonitis. *Journal of Education, Health and Sport*. 2020;10(12):365-371. eISSN 2391-8306. DOI <http://dx.doi.org/10.12775/JEHS.2020.10.12.036>  
<https://apcz.umk.pl/czasopisma/index.php/JEHS/article/view/JEHS.2020.10.12.036>  
<https://zenodo.org/record/4876334>

The journal has had 5 points in Ministry of Science and Higher Education parametric evaluation. § 8.2) and § 12.1.2) 22.02.2019.

© The Authors 2020;

This article is published with open access at Licensee Open Journal Systems of Nicolaus Copernicus University in Torun, Poland

Open Access. This article is distributed under the terms of the Creative Commons Attribution Noncommercial License which permits any noncommercial use, distribution, and reproduction in any medium, provided the original author(s) and source are credited. This is an open access article licensed under the terms of the Creative Commons Attribution Non commercial license Share alike. (<http://creativecommons.org/licenses/by-nc-sa/4.0/>) which permits unrestricted, non commercial use, distribution and reproduction in any medium, provided the work is properly cited.

The authors declare that there is no conflict of interests regarding the publication of this paper.

Received: 09.11.2020. Revised: 25.11.2020. Accepted: 29.12.2020.

## The results of a new approach to the method of modeling experimental postoperative peritonitis

M. M. Droniak

Ivano-Frankivsk National Medical University

<https://orcid.org/0000-0001-7976-0384>

### Abstract

**Purpose:** to develop a new, as close as possible to clinical conditions method of experimental modeling of postoperative peritonitis.

**Materials and methods.** In the experiment we use 60 rats Vistar line, weighing 160-240 g, kept in a vivarium in compliance with all standards. General clinical and biochemical studies were conducted in the laboratory of the Department of Biological and Medical Chemistry of Ivano-Frankivsk National Medical University.

**Research results and their discussion.** The method of experimental modeling of postoperative peritonitis developed by us is performed in sterile operating conditions. General anesthesia was performed by intramuscular injection of 0.15 ml per 100 g of sodium oxybutyrate. After processing of the operating field, we performe an upper median laparotomy, a loop of the small intestine is removed into the wound, a purse string suture is applied to its wall, a cross section of the intestinal wall is made in the middle of the purse, and purse sutures are removed to the anterior abdominal wall. The node was then tied to the skin 1.0 cm to the left of the median wound, sutured to the postoperative wound, and treated with betadine solution. The next day, the purse string suture dissolves and the contents of the intestine enter the abdominal cavity, causing postoperative peritonitis, which is as close as

possible to clinical conditions and allow to avoid relaparotomy. With the help of a purse string suture, we avoided relaparotomy.

**Key words: Postoperative peritonitis; experimental modeling.**

**Problem statement and analysis of recent research and publications.** The problem of postoperative peritonitis remains one of the most important in practical surgery, because, despite recent advances, is the direct cause of death of 50-86% of patients after surgery on the abdominal cavity [5; 9]. Making up 35-56% of all intra-abdominal complications that occur after abdominal surgery, postoperative peritonitis is the most common cause of early relaparotomy. Significant variation in the frequency of postoperative peritonitis is mainly due to the lack of a common understanding of the definition of "postoperative peritonitis". [6; 8]. Nowadays it is not clear whether to include untreated (existed before the first operation) peritonitis, as well as abscesses and infiltrates of the abdominal cavity. It is also important that a lot of authors, determining the frequency of postoperative peritonitis, do not proceed from the generally accepted terminology, but from their own understanding of this term [9; 4]. Dissatisfaction with the existing definitions has led clinicians to propose a further interpretation of the term "postoperative peritonitis" as a complication arising after planned or emergency surgery on the anterior abdominal wall, abdominal organs and retroperitoneal space, which was not preceded by pre-existing peritonitis or previously existing peritonitis was subjected to surgical treatment to eliminate the source of the disease and the lavage of the abdominal cavity [1; 5]. The development of postoperative peritonitis is difficult to study, because such patients are mostly in a serious condition after a previous operation, which complicates research [4]. Clinical studies do not allow to fully determine all the mechanisms of disease development and the possibility of optimizing approaches to the treatment and prevention of postoperative peritonitis [7]. This issue can be solved by creating an adequate experimental model of the disease in animals [2]. Currently, among all published models of peritonitis development, there is no model of postoperative peritonitis development, which has a number of significant shortcomings and does not allow to get as close as possible to clinical conditions [3].

**Purpose:** to develop a new, as close as possible to clinical conditions method of experimental modeling of postoperative peritonitis.

**Materials and methods.** In the experiment we use 60 rats Vistar line, weighing 160-240 g, kept in a vivarium in compliance with all standards. General clinical and biochemical studies were conducted in the laboratory of the Department of Biological and Medical

Chemistry of Ivano-Frankivsk National Medical University. According to the objectives of the study, animals are divided into two groups, control (n = 20) and main (n = 40), each of which in turn was divided into subgroups depending on the timing of relaparotomy:

Cp - control group, after modeling of postoperative peritonitis (n = 3).

Cr - control group, operated at 6 h after simulation of peritonitis in the reactive phase (n = 3).

Ctox - control group, operated at 24 h after simulation of peritonitis in the toxic phase of peritonitis (n = 3).

Cter - control group, operated at 72 h after simulation of peritonitis in the terminal phase of peritonitis (n = 3).

C3 - control group of rats on the 3rd day after relaparotomy, intestinal suturing, lavage of peritonitis (n = 3.)

C7 - control group of rats on day 7 after relaparotomy, intestinal suturing, lavage of peritonitis (n = 3).

C14 - control group of rats on the 14th day after relaparotomy, intestinal suturing, lavage of peritonitis (n = 2).

Mp - the main group, after modeling postoperative peritonitis n = 3.

Mr is the main group operated at 6 h after simulation of peritonitis in the reactive phase (n = 3).

Mtox is the main group operated at 24 h after simulation of peritonitis in the toxic phase of peritonitis (n = 3).

Mter is the main group operated at 72 h after simulation of peritonitis in the terminal phase of peritonitis (n = 3).

MO3 - the main group of rats on the 3rd day after relaparotomy, intestinal suturing, lavage of peritonitis (n = 10)

MO7 - the main group of rats on the 7th day after relaparotomy, intestinal suturing, lavage of peritonitis (n = 10)

MO14 - the main group of rats on the 14th day after relaparotomy, intestinal suturing, lavage of peritonitis (n = 8).

**Research results and their discussion.** The method of experimental modeling of postoperative peritonitis developed by us is performed in sterile operating conditions. General anesthesia was performed by intramuscular injection of 0.15 ml per 100 g of sodium oxybutyrate. After processing of the operating field, we performe an upper median laparotomy, a loop of the small intestine is removed into the wound, a purse string suture is

applied to its wall, a cross section of the intestinal wall is made in the middle of the purse, and purse sutures are removed to the anterior abdominal wall. The node was then tied to the skin 1.0 cm to the left of the median wound, sutured to the postoperative wound, and treated with betadine solution. The next day, the purse string suture dissolves and the contents of the intestine enter the abdominal cavity, causing postoperative peritonitis, which is as close as possible to clinical conditions and allow to avoid relaparotomy. With the help of a purse string suture, we avoided relaparotomy.

We proceeded from the fact that for the veracity of the experiment and the maximum approximation to clinical conditions, first of all two conditions are necessary: the first - the fact of surgery, anesthesia, which in itself causes changes in the body in both experimental animals and patients; the second - at postoperative peritonitis in an abdominal cavity of animals the own intestinal contents turn out.

In the study of clinical and laboratory parameters of the blood of animals observed leukocytosis, lymphocytopenia, increased erythrocyte sedimentation rate, the growth of medium weight molecules

Table 1 – Clinical and laboratory parameters in rats with acute experimental postoperative peritonitis

№	Investigated indicators	Intact animals	Animals with acute experimental peritonitis (first day)
1	Number of animals	n=60	n=60
2	Hemoglobin (g / l)	128,0±0,87	114,0±0,86
3	Erythrocytes ( $\times 10^{12}$ l)	6,35±0,11	5,84±0,10
4	Leukocytes ( $\times 10^9$ l)	11,8±0,27	19,4±0,38
5	Lymphocytes (%)	64,3±1,8	43,6±1,55
6	ESR	2,6±0,28	7,6±0,47
7	MSM (CU)	0,212±0,002	0,612±0,003

Relaparotomy was performed after 12, 24 and 72 hours to suture the intestinal wound and lavage the abdominal cavity on the animals. Macroscopically, intestinal contents were found in the abdominal cavity, the loops of the intestine were swollen, fibrinous layers were

visible on their surface after 24 and 72 hours, the peritoneum was swollen, with injected vessels.

The use of the proposed method of modeling postoperative peritonitis provides a high level of reproducibility of the model and the manufacturability of the process of its modeling with maximum approximation to clinical conditions.

In the terminal state, on the third day, most animals did not rise, were adynamic, did not respond to palpation of the abdomen, there was a violation of respiratory rhythm and heart rate. On autopsy of dead animals in the abdominal cavity were found a muddy effusion. The loops of the intestine are swollen without peristalsis, on their surface you can see a significant number of fibrinous layers, hyperemia of the visceral and parietal peritoneum with injected vessels. Between the loops of the intestine, as well as between the parietal peritoneum and intestine, there are multiple, easily torn joints of different lengths and shapes.

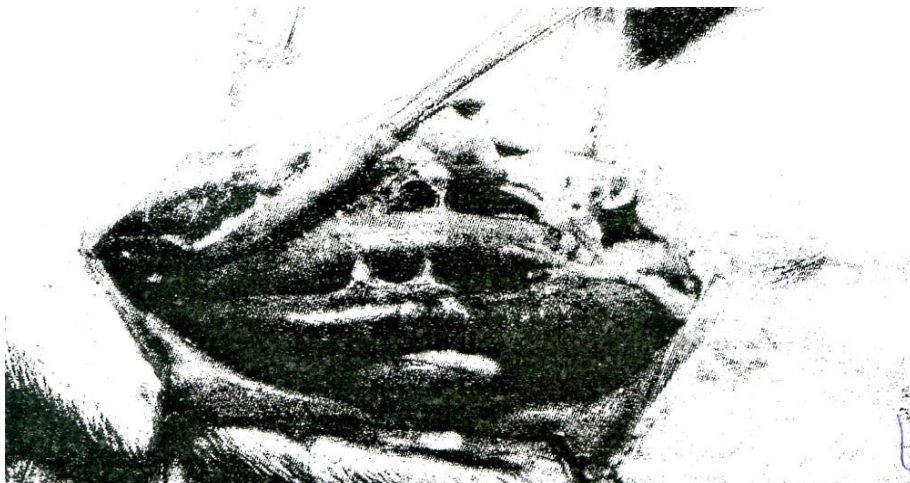

Figure 1 – General view of the rat peritoneum on the third day of experimental peritonitis.

Histological examination of the peritoneum shows edema and severe cellular infiltration with vascular thrombosis. Neutrophilic leukocytes dominate among infiltrate cells, disturbances of integrity of mesothelial insoles are defined in many sites.

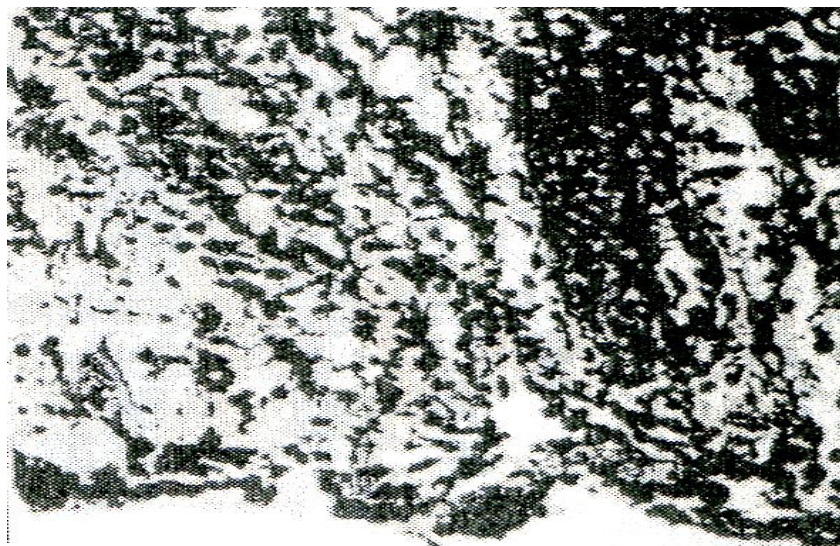


Figure 2 – Histomorphological structure of the parietal peritoneum of rats on the third day of development of experimental peritonitis.

The level of the content of molecules of average mass increased 2.5 times and amounted to  $0.612 \pm 0.003$ , at a rate of  $0.212 \pm 0.002$  conventional units.

The results indicate the presence of acute peritonitis in rats, accompanied by an increase in endotoxicosis.

**Conclusion.** The results indicate the presence of postoperative peritonitis in operated rats, which is accompanied by an increase of endotoxicosis. Experimental modeling of postoperative peritonitis made it possible to study in more detail the indicators of early signs of liver failure, the severity of endogenous intoxication, as well as the adequacy of our proposed treatment of postoperative peritonitis.

#### References

1. Bryusov PG. Postoperative peritonitis is an urgent problem of abdominal surgery P.G. Bryusov // Military Medical Journal - 1988 - Vol. 319. - №9. - P. 25-29.
2. Kovtun AI. Peculiarities of the glutathione system of the liver of rats with acute experimental peritonitis under the action of hyperbaric oxygenation and dalargin / A.I. Kovtun, IF Meshchishen, VM Kopovchuk // Buk.med. herald. - 2005. - V. 9, №2. - P. 126-127.
3. Boateng SJ, Matthews HK, Stevens HN, Eccleston MG. Wound healing dressing and drug delivery systems: a review. J Pharm Sci. 2008 Aug, 8(97):2892-23. Doi: 10.1002 / jps.21210.

4. Montravers P, Guglielminotti J, Zapella N, et al. Clinical Features and Outcome of Postoperative Peritonitis Following Bariatric Surgery. *Obesity Surgery*. 2013; 23: 1536-1544.
5. Bader F, Schroder M, Kujath P, et al. Diffuse Postoperative Peritonitis – Value of Diagnostic Parameters and Impact of Early Indication for Relaparotomy. *European Journal of Medical Research*. 2009; 14: 491-496.
6. Horer TM, Norgren L, Jansson K. Intraperitoneal glycerol levels and lactate/pyruvate ratio: early markers of postoperative complications. *Scandinavian Journal of Gastroenterology*. 2011; 46(7–8): 913–919.
7. Alqarni A, Kantor E, Grall N, et al. Clinical characteristics and prognosis of bacteraemia during postoperative intra-abdominal infections. *Critical Care*. 2018; 22: 175.
8. Lock JF, Eckmann C, Germer CT. [Characteristics of postoperative peritonitis]. *Chirurg*. 2016; 87(1): 20-5.
9. Bensignor T, Lefevre JH, Creavin B, Chafai N, Lescot T, Hor T, et al. Postoperative Peritonitis After Digestive Tract Surgery: Surgical Management and Risk Factors for Morbidity and Mortality, a Cohort of 191 Patients. *World J Surg*. 2018; 42(11):3589-3598.