

Mota Yuliya S. Long-term survival after surgical management of renal cell carcinoma with venous tumor thrombus. Journal of Education, Health and Sport. 2020;10(12):246-255. eISSN 2391-8306. DOI <http://dx.doi.org/10.12775/JEHS.2020.10.12.024>
<https://apcz.umk.pl/czasopisma/index.php/JEHS/article/view/JEHS.2020.10.12.024>
<https://zenodo.org/record/4448162>

The journal has had 5 points in Ministry of Science and Higher Education parametric evaluation. § 8.2) and § 12.1.2) 22.02.2019.

© The Authors 2020;

This article is published with open access at Licensee Open Journal Systems of Nicolaus Copernicus University in Torun, Poland
Open Access. This article is distributed under the terms of the Creative Commons Attribution Noncommercial License which permits any noncommercial use, distribution, and reproduction in any medium, provided the original author(s) and source are credited. This is an open access article licensed under the terms of the Creative Commons Attribution Non commercial license Share alike. (<http://creativecommons.org/licenses/by-nc-sa/4.0/>) which permits unrestricted, non commercial use, distribution and reproduction in any medium, provided the work is properly cited.
The authors declare that there is no conflict of interests regarding the publication of this paper.

Received: 09.11.2020. Revised: 25.11.2020. Accepted: 28.12.2020.

LONG-TERM SURVIVAL AFTER SURGICAL MANAGEMENT OF RENAL CELL CARCINOMA WITH VENOUS TUMOR THROMBUS

Yuliya S. Mota

Danylo Halytsky Lviv National Medical University

Lviv, Ukraine

Yuliya S. Mota – corresponding author. PhD student, Department of Surgery №2, Danylo Halytsky Lviv National Medical University, Lviv, Ukraine
ORCID: 0000-0002-6332-8404, e-mail: yuliamota@gmail.com

Abstract

The aim: to evaluate the long-term survival in patients after surgical management of renal cell carcinoma with venous tumor thrombus.

Materials and methods. From 1993 to 2019 88 patients with renal cell carcinoma, complicated by venous tumor thrombus, were observed at the Vascular surgery department of Lviv Regional Clinical Hospital: 65 (73.9%) men, 23 (26.1%) women, mean age – 58.7 ± 1.9 years. Surgical management included radical nephrectomy in combination with thrombectomy from inferior vena cava and right atrium. Kaplan-Meier method and log-rank test were used for survival analysis.

Results and discussion. Long-term survival was evaluated in 78 patients, the median follow-up was 51.6 ± 14.3 months. Cumulative 2-, 5- and 10-year survival rates of patients with renal vein tumor thrombus (78.8%, 48.1%, 37.4%) were significantly higher compared to patients with intraatrial and inferior vena cava tumor thrombus (53.5%, 38.2%, 17.2%) ($p < 0.05$). There was no significant difference in survival among patients with renal cell

carcinoma, complicated with tumor venous thrombus, without and with metastases ($p>0.05$). Regarding to inferior vena cava tumor thrombus level there also was no significant difference in survival ($p>0.05$). As for the prognostic value of tumor histological gradation, the overall survival parameters were significantly higher in patients with G1-G2 compared with G3-G4 differentiation degrees of renal cell carcinoma ($p<0.05$).

Conclusions. Radical nephrectomy with thrombectomy from inferior vena cava and right atrium remains the only curative treatment for patients with renal cell carcinoma and venous tumor thrombus that allows to provide reasonable long-term survival outcomes.

Key words: renal cell carcinoma; inferior vena cava thrombus; radical nephrectomy; thrombectomy; long-term outcomes

Introduction

Renal cell carcinoma (RCC) accounts for 2 - 3% of all types of malignant tumors with a high incidence in Western countries [1]. In 2018, 136,500 new cases and 54,700 deaths due to RCC were registered in Europe [2]. According to the National Cancer Registry, the incidence of RCC in Ukraine is growing annually and in 2018 amounted to 12.3 cases per 100,000 population [3].

RCC is the most frequent among neoplasms showing the tendency to expand into inferior vena cava (IVC) in 4-10% of patients at diagnosis [4, 5, 6]. In 0.4–1% of cases tumor thrombus reaches the level of the right atrium, at the same time - without obligatory vascular wall invasion [7, 8, 9]. Nearly one-third of RCC patients with venous tumor thrombus (VTT) present with metastatic disease [10]. Radical surgical tumor removal remains the only effective method of treatment for RCC with cavaatrial involvement [7, 11, 12]. Expected 5-year survival rates range between 40% and 72% in patients with non-metastatic RCC and VTT [6, 13, 14]. Nevertheless, data from recent studies support the benefit of cytoreductive nephrectomy on survival outcomes and quality of life in patients with metastatic RCC [10].

The aim

To evaluate the long-term survival in patients after surgical management of RCC with VTT.

Materials and methods

From 1993 to 2019 88 patients with RCC, complicated by VTT, were observed at the Vascular surgery department of Lviv Regional Clinical Hospital: 65 (73.9%) men, 23 (26.1%) women, mean age – 58.7 ± 1.9 years.

Preoperatively all patients underwent routine blood tests, ultrasound examination of the abdominal cavity, retroperitoneal space, computer or magnetic resonance imaging with intravenous contrast enhancement, echo-cardiography and venography according to indications.

Using the modified classification of IVC thrombosis [4], Table I summarizes the distribution of patients according to VTT level.

Table I. The distribution of patients according to VTT level

Tumor thrombus level	Total (n=88)	
	abs.	%
Renal vein	26	29.5
Cavarenal segment IVC	12	13.6
Infrahepatic segment IVC	12	13.6
Retrohepatic segment IVC	29	32.9
IIIa	10	11.4
IIIb	7	7.9
IIIc	5	5.7
IIId	7	7.9
Right atrium	9	10.2
Total	88	100.0

Surgical treatment included radical nephrectomy in combination with thrombectomy from IVC and right atrium. Depending on the level of tumor thrombus extension, patient's constitutional features, side of the tumor, presence of thrombus floating component, concomitant diseases, need for advanced lymphadenectomy and infiltrated IVC wall resection different types of surgical approaches were used, in particular: extraperitoneal approach (subcostal, lumbotomy) – in 7 (7.9%), subcostal laparotomy – in 11 (12.5%), transverse laparotomy – in 9 (10.2%) , middle laparotomy – in 20 (22.7%), «Mercedes» approach – in 18 (20.5%), «Chevron» approach – in 2 (2.3%) cases. Thoracotomy (5 (5.7%)) and sternotomy (16 (18.2%)) were performed at supradiaphragmatic IVC and intraatrial tumor thrombosis. 6 (6.8%) patients had been operated using cardiopulmonary bypass.

In several patients concomitant vascular pathology was observed: hemodynamically significant stenosis of internal carotid arteries (ICA) – 2 (2.3%), infrarenal abdominal aortic aneurysm – 3 (3.4%) cases. Tumor infiltration of the aorta was observed in 4 (4.5%), liver – in 3 (3.4%), intestines – in 2 (2.3%) cases. In addition to radical nephrectomy and tumor thrombectomy, these patients required: retrograde carotid endarterectomy from ICA, resection

of aneurysms and affected part of the abdominal aorta with aortic graft interposition, resection of liver and intestines with formation of enteroenteroanastomosis.

Kaplan-Meier method was used to evaluate the long-term survival of patients with RCC, complicated by VTT. Statistically significant difference was set at $p < 0.05$.

Results and discussion

The postoperative complications included: posthemorrhagic anemia – 29 (35.4%), acute renal failure – 19 (23.2%), acute liver failure – 5 (6.1%), pulmonary embolism – 4 (4.9%), pneumonia – 4 (4.9%), pneumothorax – 3 (3.7%), deep vein thrombosis – 3 (3.7%), hemorrhagic shock – 2 (2.4%), stroke – 2 (2.4%), acute adrenal failure – 2 (2.4%), ileus – 2 (2.4%), wound complications – 6 (7.3%) cases. Perioperative mortality rate was 9.1%. The causes of death included: hemorrhagic shock – 5 (5.7%), pulmonary embolism – 3 (3.4%), stroke – 1 (1.1%) cases.

Regional lymph nodes metastases were observed in 25 (28.4%) and distant metastases - in 13 (14.8%) patients. In morphological examination clear cell RCC prevailed - 77.3%.

Long-term survival was evaluated in 78 patients, the median follow-up was 51.6 ± 14.3 months.

Thus, the cumulative 2-, 5- and 10-year survival among 78 patients with RCC and VTT was 62.1%, 40.8% and 25.2% respectively. The median survival - 41.7 months (Fig.1).

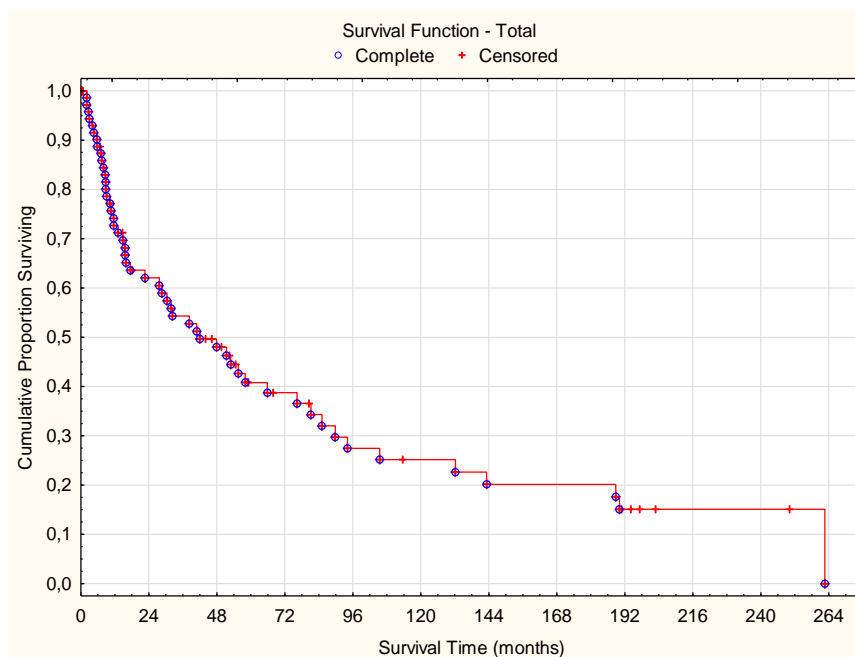


Fig. 1. Cumulative survival among 78 patients with RCC and VTT

Separately we analyzed survival rates in 53 patients with cavaatrial tumor thrombus and 25 patients with renal vein tumor thrombus (Fig.2).

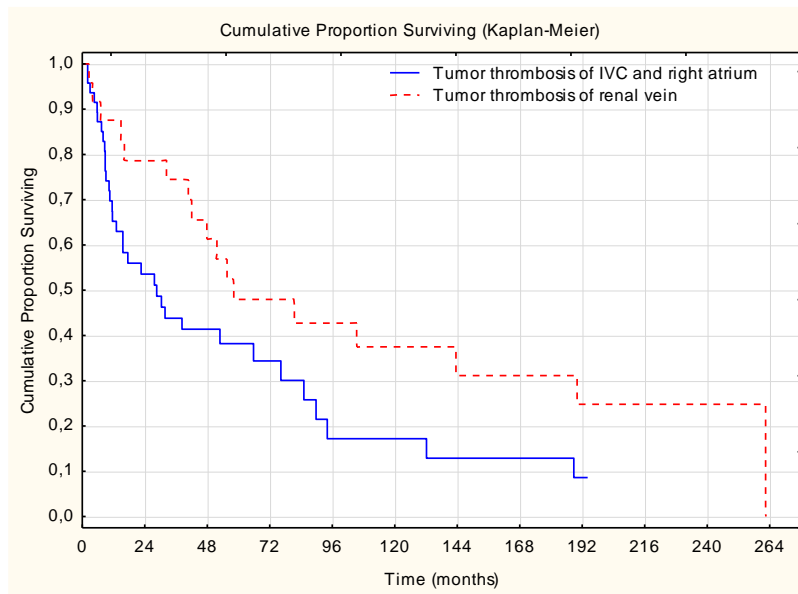


Fig. 2. Cumulative survival in groups of cavaatrial and renal vein tumor thrombus

*- the difference is significant between groups ($p < 0.05$)

As we can see, cumulative 2-, 5- and 10-year survival rates of patients with renal vein tumor thrombus (78.8%, 48.1%, 37.4%) were significantly higher compared to patients with intraatrial and IVC tumor thrombus (53.5%, 38.2%, 17.2%) ($p < 0.05$). The median survival for patients with RCC, complicated with intraatrial and IVC tumor thrombus, was 28.1 months, whereas for patients with RCC and renal vein tumor thrombus - 57.0 months.

Survival rates in 32 patients with cavaatrial and 17 patients with renal vein tumor thrombus without metastases are shown on Fig.3.

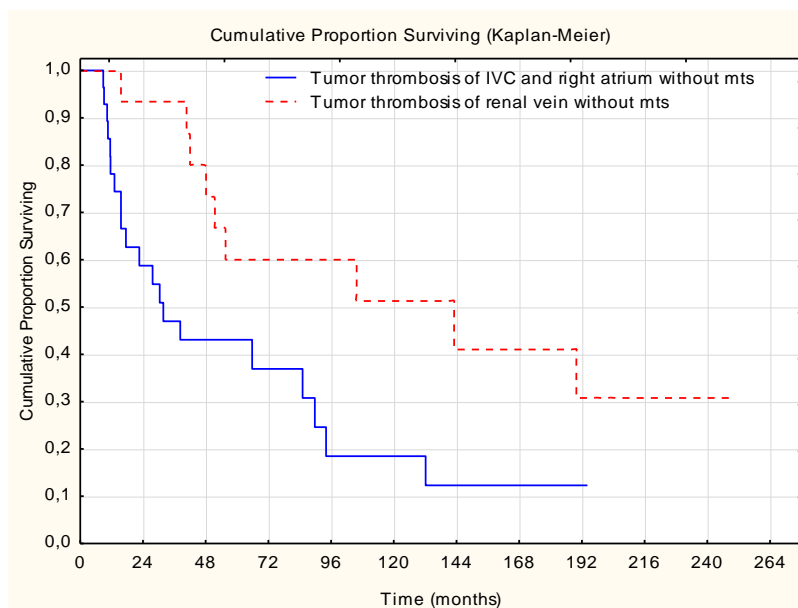


Fig. 3. Survival in groups of cavaatrial and renal vein tumor thrombus without metastases

*- the difference is significant between groups ($p < 0.05$)

Statistically significant difference was also found analyzing 2-, 5- and 10-year survival rates in patients without metastases with renal vein tumor thrombus (93.3%, 60.0%, 51.4%) and intraatrial, IVC tumor thrombus (58.7%, 43.1%, 18.5%) ($p < 0.05$).

At the same time, there was no significant difference in survival among groups of patients with RCC and VTT without and with metastases ($p > 0.05$) (Fig. 4).

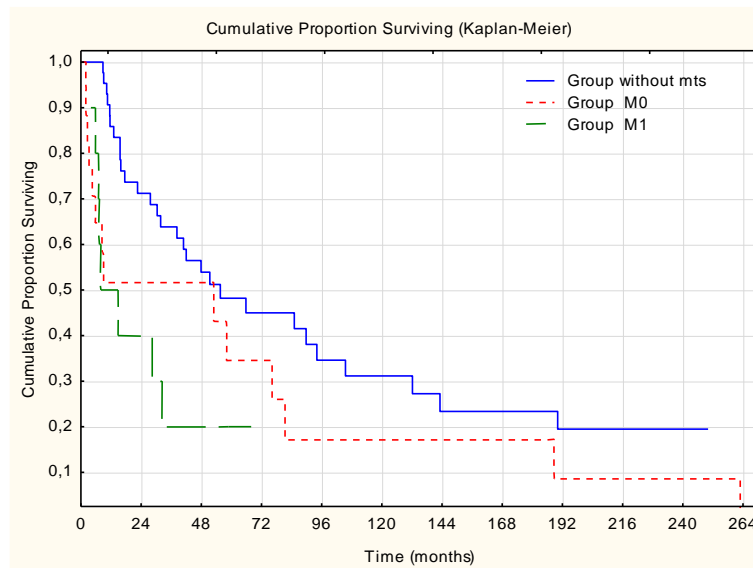


Fig. 4. Survival among patients with RCC and VTT without and with metastases

* - there is no significant difference between groups ($p > 0.05$)

Regarding to IVC tumor thrombus level there also was no significant difference in survival ($p > 0.05$) (Fig. 5).

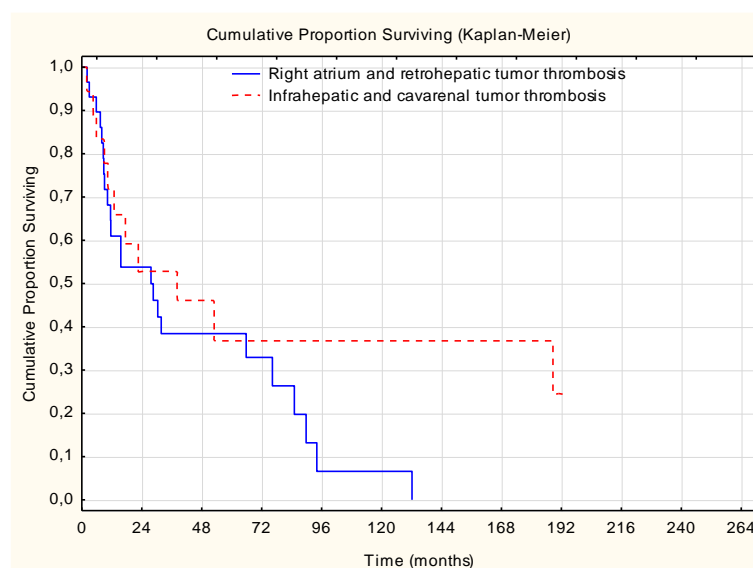


Fig. 5. Survival among patients with infrahepatic and cavarenal VTT

versus intraatrial and retrohepatic VTT

* - there is no significant difference between groups ($p>0.05$)

Among 11 patients with pathomorphologically confirmed IVC wall invasion long-term outcomes were analyzed in 7 patients (Fig. 6). One-year survival rate in this group was 50.0%, 2-year survival was confirmed in 16.7%. The median survival is 11.6 months.

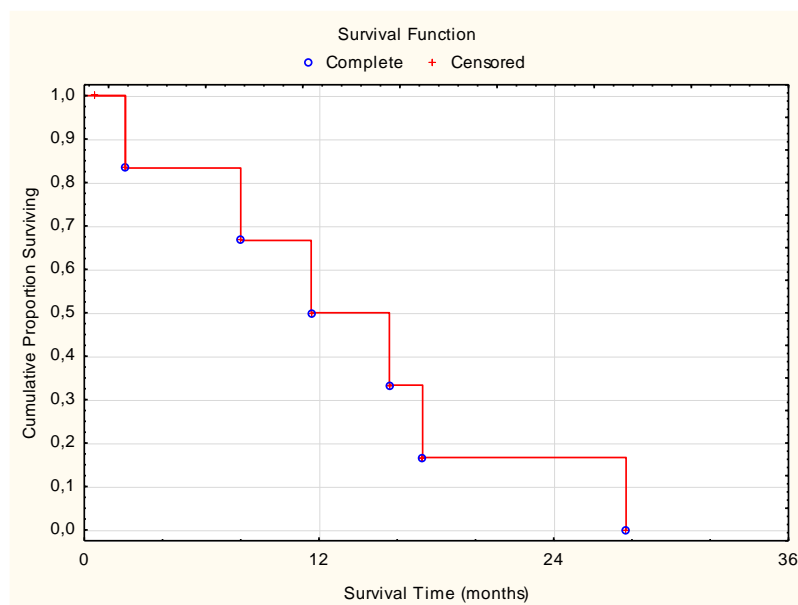


Fig. 6. Survival among patients with IVC wall invasion

Regarding the influence of tumor malignancy grading on life expectancy, significantly higher parameters of overall survival were recorded in patients with high (G1) and mildly differentiated (G2) RCC compared with low- (G3) and undifferentiated (G4) RCC ($p<0.05$).

Several studies are concerned with prognostic factors of RCC and VTT, important of which include: large tumor size, paranephric tissue invasion, Fuhrman grade, thrombus level, lymph node involvement and distant metastases [6, 14, 15].

In this study, we set out to analyse the long-term outcomes of radical nephrectomy with concomitant IVC and right atrium tumor thrombectomy.

Significantly higher survival rates were observed in patients with RCC and renal vein tumor thrombus ($p<0.05$).

According to our data, 5-year survival rate for non-metastatic patients with RCC and IVC tumor thrombus is 43.1%, which is comparable to other studies [6, 14, 15, 16].

In our study-cohort regional and distant metastases were observed in 37.2% of patients. At the same time, we did not confirm significant difference in survival among patients with RCC, complicated by VTT, without and with metastases ($p>0.05$).

The prognostic significance of VTT level has been controversial. Several authors have reported that this factor is not associated with a worse prognosis of survival among operated patients [11, 14, 15, 17]. At the same time, there are publications that indicate the negative impact of IVC tumor thrombus on survival, in particular, according to the results of an international multicenter study [6, 18, 19]. In our analysis, regarding to the level of IVC tumor thrombus there was no significant difference in survival ($p>0.05$). Some studies also reported about worse cancer specific survival in patients with RCC and microscopic IVC wall invasion, but only in univariable analysis [19].

In our observations, as for the prognostic value of tumor histological gradation, the overall survival parameters were significantly higher in patients with G1-G2 compared with G3-G4 differentiation degrees of RCC ($p<0.05$).

Conclusions

Radical nephrectomy with thrombectomy from IVC and right atrium remains the only curative treatment for patients with RCC and VTT that allows to provide reasonable long-term survival outcomes.

References

1. Ljungberg B, Albiges L, Bensalah K et al. EAU guidelines on renal cell carcinoma: 2020 update. <https://uroweb.org/guidelines/>
2. Ferlay J, Colombet M, Soerjomataram I et al. Cancer incidence and mortality patterns in Europe: Estimates for 40 countries and 25 major cancers in 2018. *Eur J Cancer*. 2018; 103: 356–387.
3. Bulletin of the National Cancer Registry of Ukraine №20 Kyiv 2018.
4. Hevia V, Ciancio G, Gómez V et al. Surgical technique for the treatment of renal cell carcinoma with inferior vena cava tumor thrombus: tips, tricks and oncological results. *Springerplus*. 2016; 5:132
5. Haidar GM, Hicks TD, El-Sayed HF et al. Treatment options and outcomes for caval thrombectomy and resection for renal cell carcinoma. *J Vasc Surg Venous Lymphat Disord*. 2017; 5(3): 430–436.
6. Martínez-Salamanca JI, Huang WC, Millan I et al. Prognostic impact of the 2009 UICC/AJCC TNM staging system for renal cell carcinoma with venous extension. *Eur Urol* 2011;59(1):120– 127.

7. Gaudino M, Lau C, Cammertoni F et al. Surgical treatment of renal cell carcinoma with cavoatrial involvement: a systematic review of the literature. *Ann Thorac Surg.* 2016; 101(3): 1213–21.
8. Nini A, Capitanio U, Larcher A et al. Perioperative and oncologic outcomes of nephrectomy and caval thrombectomy using extracorporeal circulation and deep hypothermic circulatory arrest for renal cell carcinoma invading the supradiaphragmatic inferior vena cava and/or right atrium. *Eur Urol.* 2018; 73(5): 793–799.
9. Gagné-Loranger M, Lacombe L, Pouliot F et al. Renal cell carcinoma with thrombus extending to the hepatic veins or right atrium: operative strategies based on 41 consecutive patients. *Eur J Cardiothorac Surg.* 2016; 50(2): 317–21.
10. Lenis AT, Burton CS, Golla V et al. Cytoreductive nephrectomy in patients with metastatic renal cell carcinoma and venous thrombus – Trends and effect on overall survival. *Urol Oncol.* 2019.
11. Davydov MI, Matveev VB, Dzemeshevich SL et al. Surgical treatment of renal cell carcinoma with tumor venous thrombosis in patients without distant metastases. *Clin. Experiment. Surg. Petrovsky J.* 2015; 4: 18 – 27.
12. Miyake H, Sugiyama T, Aki R et al. Oncological outcomes after cytoreductive nephrectomy for patients with metastatic renal cell carcinoma with inferior vena caval tumor thrombus. *Int J Clin Oncol.* 2018; 23(3): 553–558.
13. Verghe DC, Loeser A, Kocot A et al. Tumor thrombus of inferior vena cava in patients with renal cell carcinoma – clinical and oncological outcome of 50 patients after surgery. *BMC Res Notes.* 2012; 5: 5.
14. Ciancio G, Manoharan M, Katkooi D et al. Long-term survival in patients undergoing radical nephrectomy and inferior vena cava thrombectomy: single-center experience. *Eur Urol.* 2010; 57(4): 667–72.
15. Wagner B, Patard JJ, Méjean A et al. Prognostic value of renal vein and inferior vena cava involvement in renal cell carcinoma. *Eur Urol.* 2009; 55(2): 452–9.
16. Pouliot F, Shuch B, LaRochelle JC et al. Contemporary management of renal tumors with venous tumor thrombus. *The Journal of urology* 2010, 184(3), 833–841.
17. Haddad AQ, Wood CG, Abel EJ et al. Oncologic outcomes following surgical resection of renal cell carcinoma with inferior vena caval thrombus extending above the hepatic veins: a contemporary multicenter cohort. *J Urol.* 2014; 192(4): 1050–6.

18. Tilki D, Hu B, Nguyen HG et al. Impact of synchronous metastasis distribution on cancer specific survival in renal cell carcinoma after radical nephrectomy with tumor thrombectomy. *J Urol*. 2015; 193(2): 436–42.

19. Rodriguez Faba O, Linares E, Tilki D et al. Impact of microscopic wall invasion of the renal vein or inferior vena cava on cancer specific survival in patients with renal cell carcinoma and tumor thrombus: a multi-institutional analysis from the international renal cell carcinoma-venous thrombus consortium. *Eur Urol Focus*. 2018; 4(3): 435–441.

Conflict of interest:

The Authors declare no conflict of interest