

Inguinal hernia common problem of modern surgery

Michał Tobiasz¹, Agnieszka Turkosz¹, Maciej Tobiasz², Paweł Polski³,
Rafał Wójcik⁴

¹ Student of Medical University of Lublin

² Department of Plastic Surgery. Eastern Center of Burns Treatment and Reconstructive Surgery

³ Department of General and Transplant Surgery and Nutritional Treatment, Medical University of Lublin.

⁴ Department of Human Anatomy, Medical University of Lublin

Address for correspondence: Paweł Polski, Department of General and Transplant Surgery and Nutritional Treatment, Medical University of Lublin, 8 Jaczewskiego St, 20-954 Lublin, Poland, phone: +48 514 746 457, e-mail: maestro532@wp.pl

Summary

Hernia is a very common challenge faced by modern medicine. It is estimated that this problem affects about 20 million people annually, including 30% abdominal hernias with the highest percentage of inguinal hernias. Despite constant progress of imaging methods, surgical techniques and understanding of the biomechanics muscles, it is still a serious challenge for physicians. This article deals with the most important issues related to the diagnosis and treatment of inguinal hernia. We pay particular attention to the frequency of complications after surgery, comparing the effectiveness of specific repair methods.

Key words: inguinal hernia, surgical treatment, laparoscopy

Introduction

Hernia is a pathological displacement of the body cavity contents beyond its correct position. It is one of the most common pathologies that accompany people from the fetal period to late old age. Currently, most cases can be detected already in the prenatal period mainly by ultrasound. In the postnatal period, abdominal hernias are the most numerous group. They are often encountered not only by surgeons but also by doctors of other specialties, meet in the form of primary, recurrent and postoperative hernia. In each type of hernia you can distinguish between the gate, the bag and its content [1,2,4,18].

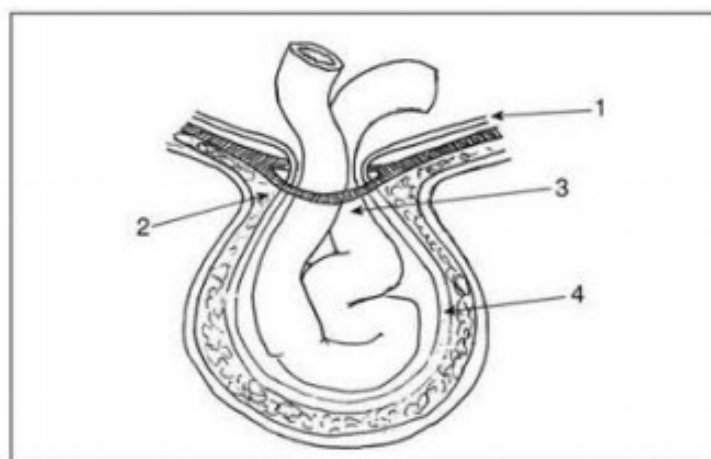


Fig. 1. Hernia 1-peritoneum, 2- gate, 3- neck, 4- hernia bag [6].

Abdominal hernias are formed in places of reduced resistance, they contain part of organs or whole organs which in proper conditions fill the abdominal cavity. There are many classifications of abdominal hernias: due to the etiopathogenesis of the hernia we can divide it into congenital and acquired, but the basic one is the division taking into account the place of its origin. We can distinguish: [4,5,6].

- inguinal hernia (*hernia inguinalis*) - the most common, especially in men (3-4 times more frequent than in women),
- femoral hernia (*hernia femoralis*) - more frequently observed in women,
- umbilical cord (*hernia umbilicalis*) - are formed in the area of the umbilical cord, which is an anatomical site of lower strength,
- white line hernia (*hernia lineae albae*) - they are formed in the middle line of the body, i.e. between the sternum and the pubic symphysis, usually above the navel,
- hernia in the postoperative scar (*hernia ventralis (cicatricea)*) - they may occur at any point of the abdominal wall within the scar tissue after the operation,

- spiegel hernia - very rare, in the area of the lateral margin of the rectus abdominis muscle within the so-called linea semilunaris [4,5,6].

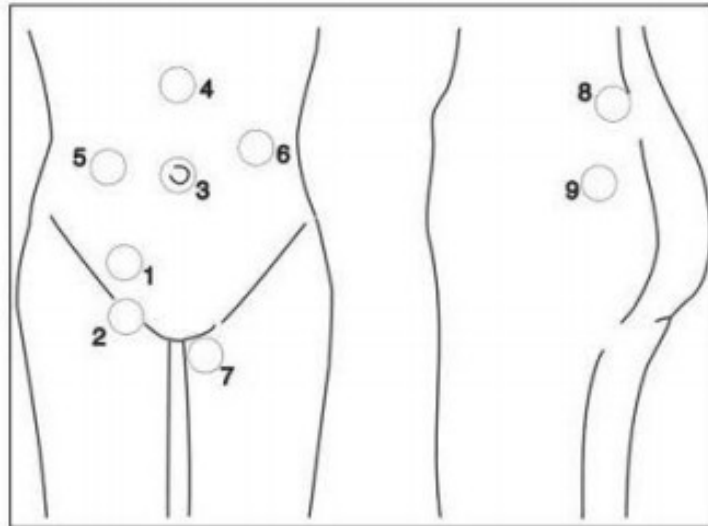


Fig. 2. Types of hernias: 1- inguinal, 2- femoral, 3-umbilical cord, 4-white line, 5-hernia in posta operative scar, 6- peri-stomy hernia, 7-perineal hernia 8- lumbar hernia, 9- ischial hernia [6].

Another important division from the clinical point of view is the classification due to the changes to which the contents of the hernial sac are subject:

- removable, when under slight pressure on the hernia sac or spontaneously as a result of the patient lying down, the contents of the sac goes back to the body cavity,
- irreversible, cumulative; the contents of the hernia sac cannot be discharged into the body cavity due to adhesions between the wall of the sac and its contents,
- entrapment of hernia when we cannot remove the contents of the sac because, under the influence of a sudden increase in pressure in the abdominal cavity, the amount of intestinal contents pressed into the intestine is greater than usual, or the hernia gates have been tightened,
- strangulation occurs when the intestines are in the hernia sac and the mesentery vessels are tightened, without urgent surgical intervention, this condition inevitably leads to intestinal gangrene [4,5,6].

Special cases of hernias are:

- - en W" - the intestines in the hernia sac are arranged in the shape of the letter W
- - Richter's hernia - in the hernia sac there is a fragment of the intestinal wall
- - Litre hernia - in the hernia sac there is an intestinal diverticulum [4,5,6].

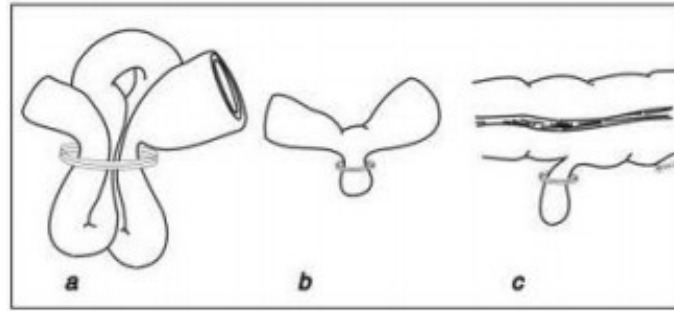


Fig. 3. The different forms of hernia: a-„enW’, b-Richter, c-Liter [6].

There is no doubt that the only effective method of treating abdominal hernia is surgery. We distinguish between classical, laparoscopic and preperitoneal endoscopic procedures. To this day, the most frequently performed hernia repair operation in the world is the classical (open) method [2,4,5,13,18].

It is estimated that the risk of hernia during life is different for men and women, respectively 27% and 3%. In the USA, about 800,000 inguinal hernia procedures are performed annually, a similar number of patients are not treated surgically for various reasons. In Poland, there is no complete data on the number of operations performed, but it is estimated that hernia procedures are performed in the amount of about 70,000 per year. Inguinal hernias are the most common and account for about 60-70% of changes in hernia. Despite such frequent occurrence, the distinction between simple and oblique inguinal hernia before surgery can be very difficult and sometimes even impossible. It is much easier in case of scrotal hernia because then we always have to deal with oblique hernia. Its equivalent in women is labial hernia, which is very rare[8,9,10,12].

Risk factors

Inguinal hernias, due to their frequency of occurrence, are a significant clinical problem both for patients and for medical care in each country, due to relatively high costs associated with the treatment and care of patients. Despite the importance of this issue, there are no clear recommendations and guidelines for reducing the incidence of inguinal hernias in the population. Risk factors for inguinal hernia are:

- smoking,
- family interview,
- persistent the vaginal appendix,
- collagenosis,
- aortic aneurysm,
- condition after appendektomy and prostatectomy,
- ascites,
- peritoneal dialysis,
- prolonged hard physical work,
- chronic obstructive pulmonary disease (COPD).

However, the effect of lifting heavy objects, constipation and prostate hypertrophy on the increased risk of hernia was not demonstrated. Thus, only smoking cessation is a justified preventive measure reducing the risk of developing inguinal hernia [11].

Clasiffication

Inguinal hernias are divided into 2 types:

- straight (medial) inguinal hernia - does not pass through the inguinal canal but directly through the abdominal wall as a result of weakening the muscles of the abdominal coatings in the so-called Hasselbach triangle (above the lower abdominal vessels),
- oblique (lateral) inguinal hernia - runs through the inguinal canal, the outlet is located in the superficial inguinal ring (below the lower epigastric vessels), a special case is the displacement of the hernia sac to the scrotum, then we have a scrotal hernia [6].

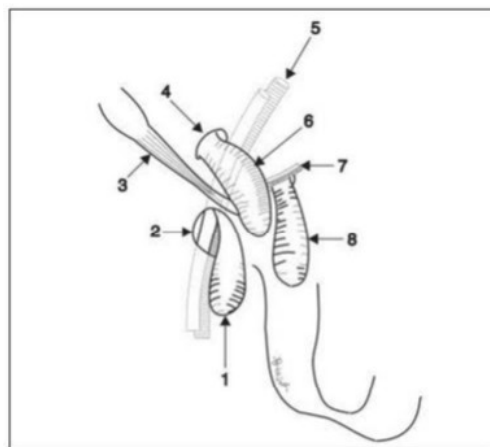


Fig. 4. Hernia of the inguinal region: 1- femoral hernia, 2- saphenous hiatus, 3- inguinal ligamnet, 4- internal inguinal ring, 5- External iliac artery and vein, 6- oblique inguinal hernia, 7- Inferior epigastric artery and vein, 8- straight (medial) inguinal hernia [6].

Symptoms

The diagnosis of hernia in most cases is not difficult for doctors. Often the patients themselves correctly diagnose their disease. However, this is not always the case, especially in cases of early hernia, when there are no characteristic symptoms of a soft tumor that can be removed. There may then be a feeling of discomfort and pain in the inguinal area intensifying after physical exercise. Ultrasound examination is very helpful in such cases, apart from physical examination. The most common clinical symptoms of inguinal hernias are as follows:

- a tumour in the inguinal above or below the inguinal ligament or in the scrotum that can be discharged into the abdominal cavity,
- pain, pulling, burning when the contents of the hernial sac move and when the inguinal area is under pressure,
- radiating pain to the testis during lifting weights, muscle tension, prolonged standing, urination, defecation, increase of intraabdominal pressure,
- pain during touch in the area of the hernia sac position [6,12].

If it happened:

- entrapment of the omentum - there is a nausea, abdominal pain, pain in the area of the hernia, tumor which cannot be removed,
- entrapment of the intestines - increased peristalsis, vomiting, nausea, abdominal pain, pain in the area of hernia, tumor which cannot be removed. During the hours the symptoms of mechanical intestinal obstruction increase,
- bowel strangulation, intestinal obstructive symptoms increase rapidly, and severe shock symptoms appear [6,12].

Differential diagnosis should concern two issues: pain of the inguinal and tumors of this area. Pain is usually associated with the locomotor system, especially for people practicing sports. There is even the term sportsmen hernia, which means pain in the inguinal after exercise without clinical features of hernia. Differentiation of pain requires many consultations, e.g.: neurological, urological, often also X-ray of the spine and pelvis (hip joints) and ultrasound [6,12,19].

Treatment

The most effective method of treatment is definitely surgery. However, it will not always be the best solution for the patient. Conservative treatment with the use of a hernia belt or even withdrawal from any therapeutic procedure and adoption of a waiting posture and observation of the patient is recommended in elderly people with other diseases and with inguinal hernia without symptoms [6,12].

The first information of surgical treatment of inguinal hernias comes from the 16th century. During this very long period of time, the development of medicine and technology contributed to changes in surgical techniques, which resulted in an increase in the effectiveness of treatment. Inguinal hernias can be treated by incision of hernia- herniotomy (historical significance), hernia suture - hernioraphy and hernia plastic surgery- hernioplasty [5,6,12].

Hernioraphy is a procedure involving the anatomical reconstruction of layers of the abdominal cavity layers in the area of hernia. The first operation of this type was carried out in 1889 by the Bassini method. Over the following years, this method was modified many times. Nowadays, the Shouldice method has become the most popular. All techniques based on the principle of hernioraphy lead (especially in the case of large hernias) to excessive

tension in the inguinal region and disturbed the anatomy of this region, which can lead to postoperative recurrences [14,15].

Hernioplasty consists in anatomical preparation of a hernia bag, withdrawal of the bag to the abdominal cavity and then closing the tissue defect by placing a prosthesis (mesh). In laparoscopic method the mesh is usually placed in the intraperitoneal position, so during the classical method the mesh can be placed in 4 locations:

- Onlay (overlay)
- Inlay
- Sublay
- Underly (IPOM) [1,3,17].

Traditional inguinal hernia operations use the patient's own tissue for reconstruction.

Bassini's method is classic and performed since the end of the 19th century, involves the preparation of a hernia bag lying in the inguinal canal, reposition of its contents into the abdominal cavity with strengthening of abdominal layers - it is a three-layer reconstruction.

Very good results, low number of complications and moderate costs of treatment caused that the modified Bassini method - **Shouldice's method**, became the most frequently used in the treatment of inguinal hernias. Observations made in recent years indicate that even better results of treatment are obtained using voltage-less methods using implanted mesh [5,6].

Nowadays, the standard of management are hernioplasty procedures performed using both conventional and laparoscopic methods. Traditional operations may be performed under local, epidural and general anaesthesia, as opposed to laparoscopic operations performed only under general anaesthesia.

Using conventional surgery, the mesh is usually placed Onlay (e.g. Lichtenstein surgery). In the Stoppoy or Wantz method, the mesh can also be placed by Sublay. When performing laparoscopic surgery, the mesh is always placed using the Sublay method. There are two ways:

- completely preperitoneal (TEP - total preperitoneal), when access to the inguinal region is obtained by dissecting the pre-peritoneal region without opening the abdominal cavity,
- transperitoneal (TAPP - transabdominal preperitoneal), when the preperitoneal region is reached through the abdominal cavity after the peritoneal opening in the inguinal region [6,14,15,16].

Laparoscopic methods bring many benefits to the patient such as: reduction of postoperative pain, lower risk of chronic pain, shorter recovery time, fewer complications - however, it depends on the experience of the surgeon performing the procedure. It is estimated that the surgeon should perform about 200 surgeries per year in order, for the laparoscopic method to be beneficial for the patient, less experience of the operator may result

in an increased number of complications compared to classical methods. The multitude of surgical techniques allows the surgeon to choose the best method of supplying the hernia to each patient due to the patient's age, general condition, co-morbidities, as well as his own experience in performing inguinal hernia operations [6,7,14,15,16].

According to scientific data, the results of inguinal hernia treatment with laparoscopic method are more beneficial for the patient than open surgery. A meta-analysis of the results of treatment assessed by the patient shows that inguinal hernia surgery with laparoscopic method is associated with significantly lower intensity of postoperative pain in short (2 weeks to 6 months), medium (6-12 months) and long (over 12 months) period after surgery. Similarly, after laparoscopic inguinal hernia treatment, paresthesias were less frequent. The patient's satisfaction was also higher after laparoscopic procedures. After the mean observation period of 21.9 months, satisfaction after surgery was felt by 88.7% of patients treated with laparoscopic method and only 79.3% of patients treated with classical (open) method. In the mean observation period of 35.4 months, the frequency of recurrences was 4.4% after laparoscopic procedures and 3.9% after open procedures. There were no differences in the frequency of relapses in each analysed period [7].

Summary

Inguinal hernia is a problem affecting a large percentage of the population. The development of medicine and technology as well as knowledge of the risk factors for inguinal hernia have significantly reduced complications after surgery and the frequency of recurrences. Despite this, it is still necessary to strive to reduce the incidence of inguinal hernia as complications and relapses after repair operations.

References

1. Bougard H, Coolen D, de Beer R et al.: HIG (SA) Guidelines for the management of ventral hernias. *S Afr J Surg* 2016; 54(4): 1-32.
2. Czernik J: *Chirurgia dziecięca*. Wydawnictwo Lekarskie PZWL, Warszawa 2005: 105–112.
3. Golaszewski P, Wozniowska P, Dawidowska J, Pawluszewicz P, Soldatow M, Wyszynska M, Razak H: Incisional hernia – clinical characteristics, diagnosis and treatment. *Post N Med* 2018; 31(5): 296-300
4. Komorowski A, L.: *Przepukliny brzuszne*. Medycyna Praktyczna 2017. Dostęp: <https://www.mp.pl/pacjent/choroby/165551,przepukliny-brzuszne>

5. Kuś H, Mackiewicz Z: Przepukliny brzuszne. Wydawnictwo Lekarskie PZWL, Warszawa 1997: 76–96.
6. Noszczyk W: Chirurgia. Wydawnictwo Lekarskie PZWL. Warszawa 2009; 929-940.
7. Patterson T.J. i wsp.: Meta-analysis of patient- reported outcomes after laparoscopic versus open inguinal hernia repair. *Br. J. Surg.*, 2019
8. Pierściński S et al.: Próba oceny częstości występowania i kosztów leczenia operacyjnego przepuklin pachwinowych w Polsce w latach 2001-2002. *Przeegl Epidemiologiczny* 2005; 59: 981-86.
9. Primatesta P, Goldacre MJ: Inguinal hernia repair: incidence of elective and emergency surgery, readmission and mortality. *Int J Epidemiol* 1996; 25: 835-9.
10. Ruhl CE, Everhart JE: Risk factors for inguinal hernia among adults in the US population. *Am J Epidemiol* 2007; 165: 1154-61.
11. Simons, M.P., Aufenacker T, Bay-Nielsen, M. et al. *Hernia* (2009) 13: 343. <https://doi.org/10.1007/s10029-009-0529-7>
12. Szczęsny W, Reśliński A, Dąbrowiecki S, Szmytkowski J: Przepukliny brzuszne – co lekarz rodzinny wiedzieć powinien, *Borgis - Medycyna Rodzinna* 1/2010, s. 10-13
13. Smereczyński A, Kołaczyk K: Znaczenie ultrasonografii w diagnostyce przepuklin powłok brzusznych. *Pediatr Med Rodz* 2014, 10 (4), p. 398–404.
14. Ścierański A.: Definicje, terminologia i klasyfikacja przepuklin. W: *Przepukliny pachwinowe i udowe u dorosłych*. Wyd. 1. Bielsko Biała: Alfa-Medica, 2011, s. 42-55. ISBN 978-83-7522-051-3
15. Ścierański A, Roechte F. Changes of important anatomical structures in the inguinal region after a herniorrhaphy: observations during treatment of recurrent hernia using TEP. *„Wideochirurgia”*, s. 13, 2007
16. Śmietański M: Operacja laparoskopowego zaopatrzenia przepukliny brzusznej z implantem wewnątrztrzewnowym. *Medycyna po Dyplomie* 2015; 3: 27-33.
17. Tobiasz M, Turkosz A, Smorąg M, Tobiasz M, Polski P: The hernia in the postoperative scar- can it be avoided? DOI: <http://dx.doi.org/10.5281/zenodo.3265470>
18. Tonni G, Pattaccini P, Ventura A et al.: The role of ultrasound and antenatal single-shot fast spin-echo MRI in the evaluation of herniated bowel in case of first trimester ultrasound diagnosis of fetal gastroschisis. *Arch Gynecol Obstet* 2011; 283: 903–908.

19. van Veen RN et al.: Successful endoscopic treatment of chronic groin pain in athletes Surg Endosc 2007; 21: 189-93.