

Kurtyka Daria, Budziejko Blanka, Bialkowska Aleksandra, Cywińska Oliwia, Różański Gracjan, Dobosiewicz Anna Maria, Badiuk Nataliia. Conservative and surgical treatment and possible complications of lateral support syndrome of the patellofemoral joint. *Journal of Education, Health and Sport*. 2018;8(11):778-786. eISSN 2391-8306. DOI <http://dx.doi.org/10.5281/zenodo.2839624>
<http://ojs.ukw.edu.pl/index.php/johs/article/view/6897>
<https://pbn.nauka.gov.pl/sedno-webapp/works/913320>

The journal has had 7 points in Ministry of Science and Higher Education parametric evaluation. Part b item 1223 (26/01/2017).
1223 Journal of Education, Health and Sport eISSN 2391-8306 7

© The Author(s) 2018;

This article is published with open access at Licensee Open Journal Systems of Kazimierz Wielki University in Bydgoszcz, Poland

Open Access. This article is distributed under the terms of the Creative Commons Attribution Noncommercial License which permits any noncommercial use, distribution, and reproduction in any medium, provided the original author (s) and source are credited. This is an open access article licensed under the terms of the Creative Commons Attribution Non commercial license (<http://creativecommons.org/licenses/by-nc/4.0/>) which permits unrestricted, non commercial use, distribution and reproduction in any medium, provided the work is properly cited.

This is an open access article licensed under the terms of the Creative Commons Attribution Non commercial License (<http://creativecommons.org/licenses/by-nc/4.0/>) which permits unrestricted, non commercial use, distribution and reproduction in any medium, provided the work is properly cited.

The authors declare that there is no conflict of interests regarding the publication of this paper.

Received: 19.11.2018. Revised: 22.11.2018. Accepted: 30.11.2018.

Conservative and surgical treatment and possible complications of lateral support syndrome of the patellofemoral joint

Daria Kurtyka¹, Blanka Budziejko¹, Aleksandra Białkowska¹, Oliwia Cywińska¹, Gracjan Różański¹, Anna Maria Dobosiewicz¹, Nataliia Badiuk²

¹Scientific Circle of Exercise Physiology at Department of Hygiene, Epidemiology and Ergonomics. Division of Ergonomics and Exercise Physiology, Nicolaus Copernicus Univeristy in Toruń, Collegium Medicum in Bydgoszcz, Poland

²State Enterprise Ukrainian Research Institute for Medicine of Transport, Ministry of Health of Ukraine, Odesa, Ukraine

Corresponding author: Anna Maria Dobosiewicz, annamdo@gmail.com

Abstract

The knee joint is the largest joint in the human body. At the same time, it is most sensitive to various diseases, often leading to the destruction of anatomical structures, disruption of static and dynamic functions. The authors of the article conducted a literary search on the methods of treatment of the syndrome of lateral support of the patellar-hip joint.

In the case of lateral support syndrome of the patella and thigh joint, conservative treatment should be implemented first. Properly selected physiotherapeutic methods allow to

reduce pain and avoid surgery. Surgical treatment should be the final choice, as it is associated with the possibility of complications that will delay the patient's recovery.

Key words: patellofemoral joint, treatment, surgical treatment, conservative treatment, lateral support syndrome

Introduction

The knee joint is the largest joint in the human body. At the same time, it is the most sensitive to various diseases, often leading to the destruction of anatomical structures, static and dynamic function disorders. These, in turn, cause significant pain and movement problems. Overcoming hills and descending stairs requires high tension of the quadriceps muscle of the thigh. This leads to significant support of the kneecaps to the condyles of femoral bones. Symptoms of kneecap and thigh joint failure may intensify, as well as abnormal trajectory of the kneecaps in the form of lateral support syndrome of the kneecap and thigh joint.

The disease poses diagnostic and therapeutic problems for doctors, mainly orthopaedic surgeons, as regards the qualification for conservative or surgical treatment and the adoption of an appropriate course of action. Treatment of the lateral support syndrome of the patellofemoral joint can be a long-term process. The basic principle after the diagnosis is established is to indicate the main cause of lateral patella support and to implement appropriate treatment.

The choice of treatment is extremely important, as improper therapeutic management can lead to significant knee joint complications. The basic principle, after the diagnosis of lateral support syndrome of the patellofemoral joint, is to consider its main cause and implement appropriate conservative treatment. If there is no improvement after conservative treatment, then there is an indication for surgical treatment [1].

Conservative treatment of lateral support syndrome of the patellofemoral joint

The main aims of rehabilitation in the lateral support syndrome of the patellofemoral joint:

- Elimination of pain, exudate and inflammation (if any of them occur)
- Stretching the contracted tissues, restoring the mobility of the patella to the normal range of movement of the knee joint
- Achieve the right muscle mass and strength for your kneecap
- Restoration of the proper dynamics of the diagonal action of the large medial mass muscle

- Re-education of the deep limb sensation

Currently, in many countries, rehabilitation is associated with the use of physical treatments. The use of combined physiotherapeutic methods, in particular, various types of electrical energy, ultrasound, mud therapy and balneal effects, helps not only to avoid complications of drug therapy, but also to improve the blood supply to the musculo-articular tissues, prevent the development of muscle atrophy, and increase the body's defenses [18].

Physiotherapy plays a very important role in the lateral support syndrome of the patellofemoral joint. The basic part of the therapeutic process is kinesitherapy, which should be carefully selected and controlled.

The elimination of pain, especially the pain that accompanies exercises, is very important. Pain inhibits muscle activity, especially the oblique part of the medial head of the quadriceps. In this case, kinesiotaping is very effective [2].

The technique of taping and, directly, the tape itself (teip) was developed by the Japanese doctor Kenzo Kass at the end of the twentieth century. Taping is a therapeutic method of restorative treatment, based on the activation of proprioceptor muscle fibers, the improvement of blood microcirculation and lymph. The method consists of sticking a special elastic patch on the skin and giving a specific effect on the muscle, vascular, nervous and connective tissue [17].

The aim of kinesiotaping is to use natural processes of self-healing. By activating the endogenous system of anaesthesia it influences the elimination of pain. Moreover, it normalizes muscle tension and improves microcirculation. Thanks to the use of this method of therapy, it is possible to improve proprioception, correction of joint position and mechanical correction. In the treatment of lateral support syndrome of the patellofemoral joint, techniques relieving the patellofemoral joint, Hoffa body and patellofemoral ligament are often used [3].

The exudate and inflammation in an isolated form of lateral support of the patellofemoral joint occurs rarely, if already present, physiotherapeutic treatments such as cryotherapy, magnetic field, laser therapy are applied.

Cryotherapy can be applied locally and in general. As a result of the effect of low temperatures on the body surface, there is a reduction in pain and swelling, muscle relaxation and an increase in muscle strength, as well as an increase in the range of movement within the treated knee joint. All this indicates the anti-inflammatory effect of cryotherapy [4].

Pulsating magnetic field of low frequency has mainly analgesic, anti-inflammatory, anti-edema and accelerates wound healing processes.

Laser radiation has an analgesic, anti-inflammatory, anti-edema and angiogenetic effect, facilitates nerve regeneration and increases microcirculation [5].

In order to eliminate swelling, lymphatic kinesiotaping-technique is also used.

In order to restore the static balance of muscles, poisometric muscle relaxation is of great importance. Its main objectives are: reduction of resting tone muscle tone tension, analgesic effect by decreasing resting muscle tone using physiological reflexes from receptors found in muscle tendons.

In the lateral support syndrome of the patellofemoral joint, special attention should be paid to the straight thigh muscle, knee benders, hip and tibia strand, thigh adductors, gastrocnemius muscle of the calf [6].

Another method of loosening excessively contracted muscles is the PNF technique. Its aim is to improve the range of movement by dynamically tensioning the contracted antagonistic muscles, which facilitates the work of agonists [7].

An important role in the rehabilitation process is played by the mobilization of the patella.

Once the elasticity standards of the shrunken muscles have been reached, strength training of the weakened muscles should be started. The condition for starting is lack of pain. During the exercises, biomechanical conditions of the kneecap and thigh joint work should be taken into account, and the medial head of the quadriceps thigh muscle should be given the most attention [8].

It is necessary to use exercises acting locally on specific muscle groups as well as general fitness exercises in order to improve general physical fitness [9].

Muscle strengthening can also be achieved using techniques used in the PNF concept, such as combination of isotonic contractions or dynamic continuous manoeuvrability.

The technique of combination of isotonic contractions, agonistic technique, uses in different phases of one movement dynamic and static work of muscles in order to increase strength and endurance of exercised muscle groups. It is a functional training of eccentric movement control.

Dynamic continuous agility is an antagonistic technique using alternate concentric work of agonists and antagonists, without relaxation, which results in regulation of muscle tension,

increased endurance and strength of trained muscle groups [7]. It is important to remember about proper exercise and avoid excessive rotation of the inner thigh and outer shank.

Another important element of the rehabilitation program for people with lateral support syndrome of the patellofemoral joint is the training of proprioception, it will help to develop dynamic balance and neuromuscular control of the joint [10]. According to the S-E-T concept, this is possible thanks to a proper combination of exercises in closed and open kinetic chains [11]. Exercises of the closed kinematic chain are more commonly used because they allow to restore the function of both the knee joint and the whole limb. They simulate physiological and biomechanical functions, induce proprioceptive stimuli [12]. During these exercises, a "pseudo-isometric" contraction occurs, which is used during everyday functioning (walking, running, etc.). It cannot be recreated during open kinematic chain exercises [10]. The use of closed kinematic chain exercises in early rehabilitation reduces the forces acting on the patellofemoral joint, prevents muscle contractures leading to a reduced range of bending in the knee joint [13].

In order to restore proper proprioception, all exercises on a tilting surface (baton, balance board, sponge mat, rubber cushions), exercises with Swiss balls, elastic bands are applied [12].

In order to improve proprioception, PNF techniques are also used. One of them is rhythmic stabilization. This is a technique in which the patient works against the therapist's resistance, without the intention of movement. Its main aim is to improve stability and balance, strengthen working muscles and reduce pain. Another such technique is the combination of isotonic contractions [7].

Surgical treatment of lateral support syndrome of the patellofemoral joint

Lateral release is a common surgical method of treatment of patients with patellofemoral joint pathology, such as pain, patella chondromalacia, lateral support syndrome of patellofemoral joint, subluxation and dislocation of patella [14].

It was first described by Merchant in 1974.

The lateral release is an arthroscopic or classic intersection of the lateral patellar retinaculum. It is a relatively harmless procedure with little surgical intervention, no immobilization required and only minor complications [15].

The aim of this method is to reduce the forces pushing the kneecap against the lateral condyle of the femur. It is used as a stand-alone procedure or in combination with other

procedures (displacement of the tibia tumor, quadriceps or medial trachea in the reconstruction of an upright knee joint) [1].

The procedure involves cutting all three layers of the side stripe in a straight line, perpendicular to the longitudinal axis of the body, distant by 1 cm from the lateral angle of the patella. The lateral release begins with the most distally located fibers of the large lateral muscle, i.e. about 2 cm above the upper pole of the kneecap, and ends at the level of the joint cavity.

The methods commonly used in lateral release are:

- Open method (classic)
- Arthroscopic method
- Semi-closed method

The lateral support syndrome of the patellofemoral joint is most often performed with the use of the arthroscopic method. It can be a hook-shaped knife, a Smillie knife, ultrasound knife, laser, electrocoagulation and a front-medium portal for arthroscopic viewing. The cut is of the inside out type, which means that first the synovial membrane is cut and then the lateral retinaculum is cut, up to the subcutaneous layer proving that the surgery is complete.

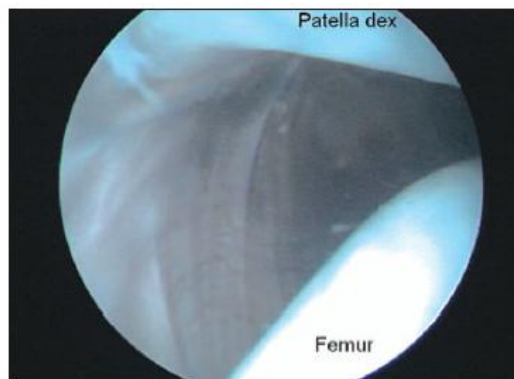


Fig. 1: Excessively tightened side retinaculum of the right kneecap [1].

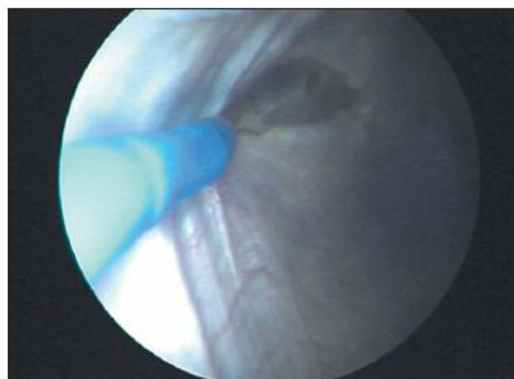


Fig. 2: Electrocoagulation of the right lateral patella retinaculum [1].

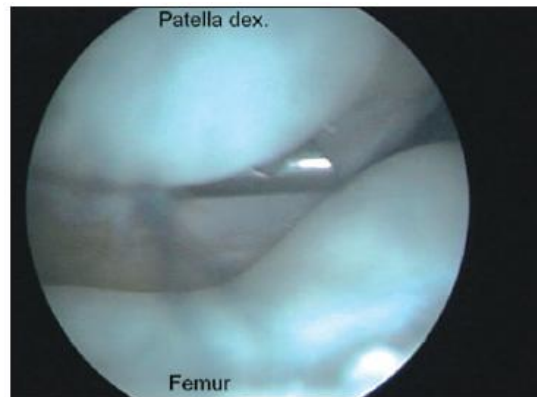


Fig. 3. Condition after the intersection of the lateral retinaculum - correct positioning of the kneecap in the intercondylar notch [1].

The semi-closed technique is used less frequently. It consists in the formation of a subcutaneous tunnel in the subcutaneous tissue from a small incision on the route of future lateral release. Then, with a Smillie knife, the lateral trachea is cut. In this method, the synovial membrane is not affected [1].

To check if the lateral release is sufficient, use the turn up test. This involves raising the lateral edge of the kneecap to an angle of 70 to 90° or so that the medial edge touches the intercondylar furrow. A positive test result indicates that the lateral release is sufficient.

Possible complications

A. Knee hematoma

Arthroscopic lateral release of the patella is complicated by hematoma in 10- 18% of cases [16].

Good knowledge of the course of vascular bundles, selective ligation of these vessels or the use of transillumination technique allow to avoid such complications. Also the use of electrocoagulation or YAG laser potentially reduces the risk of postoperative hematoma.

B. Medial subluxation of the patella

This complication occurs when the procedure was performed without any clear signs of excessive lateral strapless tension. It is difficult to detect in MRI and x-ray, but often the proof of medial subluxation of the patella is the relief of symptoms, after a trial period of use of the orthosis limiting medial displacement of the patella.

C. Fibrosis at the point of intersection

This complication may lead to excessive lateral support of the kneecap again.

D. Skin burns

The complications may occur as a result of electrocoagulation [1].

Conclusion

There are many physiotherapeutic methods that can be used for lateral support syndrome of the patellofemoral joint. Their proper selection and long enough use allows to relieve pain and may protect the patient from the need for surgery. Surgical intervention should be applied only when the conservative treatment did not bring the desired results.

References

1. Dolata T., Rogalika A., Weiss W.: Rola uwolnienia bocznego w patologii stawu rzepkowo-udowego. *Artroskopia i Chirurgia Stawów* 2006, 2 (4): 5- 12
2. Piątkowski M.: Fizjoterapia w zespole bocznego przyparcia stawu rzepkowo-udowego- doświadczenia własne. *Fizjoterapia Polska* 2005 5 (1): 65- 71
3. Senderek T.: Kinesiotaping. Part 1- materiały kursowe. Warszawa 2007
4. Zagrobelny Z.: Krioterapia miejscowa i ogólnoustrojowa. Urban & Partner. Wrocław 2003: 35- 41
5. Straburzyńska- Lupa A., Straburzyński G.: Fizjoterapia. PZWL. Warszawa 2004: 605
6. Lisowski J., Hagner W.: Terapeutyczna moc rozciągania mięśni ćwiczenia w procesie autoterapii i profilaktyki najczęstszych dolegliwości i dysfunkcji narządu ruchu. *Remedium. Włocławek* 2005: 10- 11
7. Lizak A.: Proprioceptive Neuromuscular Facilitation. Skrypt kursu podstawowego. Kraków Warszawa 2006
8. Rakowska M.: Autoterapia i profilaktyka dysfunkcji narządu ruchu w modelu holistycznym medycyny manualnej. *Zeszyt ćwiczeń. Poznań* 2002
9. Milanowska K.: Kinezyterapia. PZWL 2003: 18- 19

10. Milewska M., Mańka J.: Propozycja programu usprawniania po rekonstrukcji więzadła krzyżowego tylnego stawu kolanowego z użyciem autoprzyszczepu ze ścięgna mięśnia prostego uda. *Acta Clinica* 2001; 1 (2): 166
11. Torf T., Vindal V., Kirkesola G.: Teoretyczne i praktyczne aspekty koncepcji Sling Exercise Therapy (S- E- T) z wykorzystaniem urządzenia Terapi Master. Skrypt kursu- poziom 1 dolna część ciała. Warszawa 2007
12. Stefanick G. F.: Low- tech rehabilitation of bilateral patellofemoral knee pain in a runner: a case study. *J Can Chiropr Assoc* 2004; 48 (4): 259- 265
13. Wawrzyniak J. R.: Effect of Closed Chain Exercise on Quadriceps Femoris Peak Torque and Functional Performance. *J Athl Train*. 1996; 31 (4): 335-340
14. Panni A. S. i wsp.: Long- term Results of Lateral Retinacular Release. *Arthroscopy* 2005, 21 (5): 526
15. Christoforakis J. i wsp.: Effects of lateral retinacular release on the lateral stability of the patella. *Knee Surg Sports Traumatol Arthrosc* 2006, 14: 273
16. Viale R. i wsp.: Anatomic and radioanatomic study of the lateral genicular arteries: application to prevention of postoperative hemarthrosis after arthroscopic lateral retinacular release. *Surg Radiol Anat* 1999, 21: 49
17. Kasatkin M. S. Kinezioteypirovaniye: istoriya sozdaniya original'noy metodiki i svoystva kinezioteypov (lektsiya) / M. S. Kasatkin // *Sportivnaya meditsina: nauka i praktika*. – 2015. – № 1. – S. 77–81. (in Russian)
18. Zabolotnykh I. I. Bolezni sustavov [Elektronnyy resurs] : rukovodstvo dlya vrachey / I. I. Zabolotnykh. - SPb. : SpetsLit, 2013. - 270 s. - Rezhim dostupa: <https://www.books-up.ru/ru/book/bolezni-sustavov-4761022/> (in Russian)