

Kurtyka Daria, Dziarkowski Dariusz, Gawrych Szymon, Rózański Gracjan, Dobosiewicz Anna Maria, Badiuk Natalia. **Diagnostics of lateral support syndrome of the patellofemoral joint.** Journal of Education, Health and Sport. 2018;8(11):787-795. eISSN 2391-8306. DOI <http://dx.doi.org/10.5281/zenodo.3013318>
<http://ojs.ukw.edu.pl/index.php/johs/article/view/6896>

The journal has had 7 points in Ministry of Science and Higher Education parametric evaluation. Part b item 1223 (26/01/2017).
1223 Journal of Education, Health and Sport eISSN 2391-8306 7
© The Author(s) 2018;

This article is published with open access at Licensee Open Journal Systems of Kazimierz Wielki University in Bydgoszcz, Poland
Open Access. This article is distributed under the terms of the Creative Commons Attribution Noncommercial License which permits any noncommercial use, distribution, and reproduction in any medium, provided the original author (s) and source are credited. This is an open access article licensed under the terms of the Creative Commons Attribution Non commercial license (<http://creativecommons.org/licenses/by-nc/4.0/>) which permits unrestricted, non commercial use, distribution and reproduction in any medium, provided the work is properly cited.
This is an open access article licensed under the terms of the Creative Commons Attribution Non commercial License (<http://creativecommons.org/licenses/by-nc/4.0/>) which permits unrestricted, non commercial use, distribution and reproduction in any medium, provided the work is properly cited.
The authors declare that there is no conflict of interests regarding the publication of this paper.
Received: 19.11.2018. Revised: 22.11.2018. Accepted: 30.11.2018.

Diagnostics of lateral support syndrome of the patellofemoral joint

**Daria Kurtyka¹, Dariusz Dziarkowski¹, Szymon Gawrych¹, Gracjan Rózański¹,
Anna Maria Dobosiewicz¹, Natalia Badiuk²**

¹Scientific Circle of Exercise Physiology at Department of Hygiene, Epidemiology and Ergonomics. Division of Ergonomics and Exercise Physiology, Nicolaus Copernicus Univeristy in Toruń, Collegium Medicum in Bydgoszcz, Poland

²State Enterprise Ukrainian Research Institute for Medicine of Transport, Ministry of Health of Ukraine, Odesa, Ukraine

Corresponding author: Anna Maria Dobosiewicz, annamdo@gmail.com

Abstract

The lateral support syndrome of the patella and thigh joint is classified as a kind of dysplasia of this joint. The causes may be a muscular balance disorder, congenital abnormalities in the locomotor system or posture defects. Lateral support syndrome is most easily diagnosed through physical and subjective examination of the patient, while imaging is the best method to determine the exact type and scale of the abnormality.

Keywords: Patellofemoral joint, diagnostic, lateral support syndrome

Introduction

The patella-builder joint is the morphological part of the knee, although biomechanically it is a separate unit.

Patella has many important biomechanical functions in the knee:

- extends the lever arm of the quadriceps thigh muscle throughout the entire range of motion

- increases the contact area between the patella ligament and the femur by distributing compression loads on the femur.

- takes part in the thigh quadriceps muscle system acting as a block changes the direction of pulling through this muscle during knee erection.

- regulates the tension of the joint capsule [1].

The classification of patella and thigh joint diseases was presented by Merchant:

1. Injuries to the patellofemoral joint

A. Sharp

- bruises
- dislocations
- fractures
- rupture of the tendon of the quadriceps muscle of the thigh, ligaments of the patella

B. repeated injuries

- jumper's knee
- quadriceps muscle tendonitis
- peripatellar tendinitis
- Osgood-Schlatter's disease
- Sinding-Larsen-Johanssen's disease
- purple bursitis

C. distant effects of injuries

- post-traumatic patella chondromalacia
- post-traumatic degenerative changes in the patellofemoral joint
- acquired low patella position
- acquired quadriceps muscle fibrosis in the thigh
- dystrophy of patella
- fibrosis of the fatty body Hoffa

2. Dysplasia of the patellofemoral joint

A. Lateral support syndrome of the kneecap and thigh joint

- secondary chondromalacia of the patella
- secondary degenerative changes in the patellofemoral joint

B. Chronic lateral subluxation of the patella

- secondary chondromalacia of the patella

- secondary degenerative changes in the patellofemoral joint

C. Reversal of patella dislocations

D. Chronic dislocations of the patella

3. Idiopathic chondromalacia of the patella

4. Osteochondritis dissecans

5. Folds of the synovial membrane [2].

Side support syndrome of the kneecap and thigh joint.

According to Merchant's classification, lateral support syndrome of the patella and thigh joint belongs to the diseases of dysplasia of the patella and thigh joint.

It is one of the forms of patella tract disorders.

There are 4 forms of patella tract disorders:

- form I: the patella deviates from the lateral knuckle of the femur between 30° and 60° of the knee bend. In the remaining phases of movement it may return to the normal track.

- form II: the patella deviates from the lateral knuckle of the femur between 60° and 90° of the knee bend. In the remaining phases of movement, it may return to normal track or it is more likely to dislocate.

- form III: the patella deviates from the lateral knuckle from its full erection to its 90° bend.

- form IV: lateral support syndrome of the patellofemoral joint. The patella perverts, the lateral support of the patella joint surface to the lateral condyle of the femur during the final phase of active straightening between 30° and full straightening occurs [3]. In the literature this is referred to as 'J sign'.

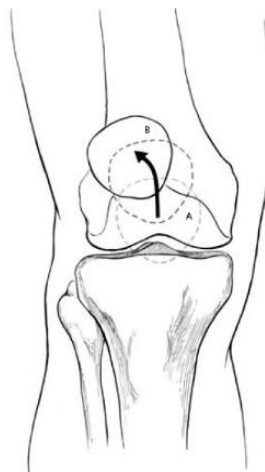


Fig.1. Scheme of the IV form of patella thoracic disturbances. A- setting the patella during 90 bends, B- setting the patella in the full posture [4].

In the final stage of straightening, the patella is not supported by the lateral knuckle of the tibia. A physiological, slight lateral position of the patella occurs as a result of the predominance of laterally directed force of the quadriceps muscle. It follows that the muscular balance disorder, i.e. the predominance of the lateral head of the quadriceps thigh muscle, will force excessive perversion of the patella in this phase of movement [3]. This is the most frequent mechanism of lateral support syndrome of the patellofemoral joint.

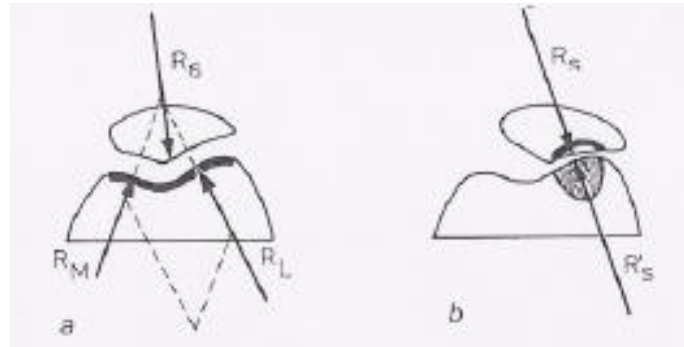


Fig. 2: Distribution of pressure in the patellofemoral joint: a- normal conditions; b- lateral support syndrome of the patellofemoral joint [4].

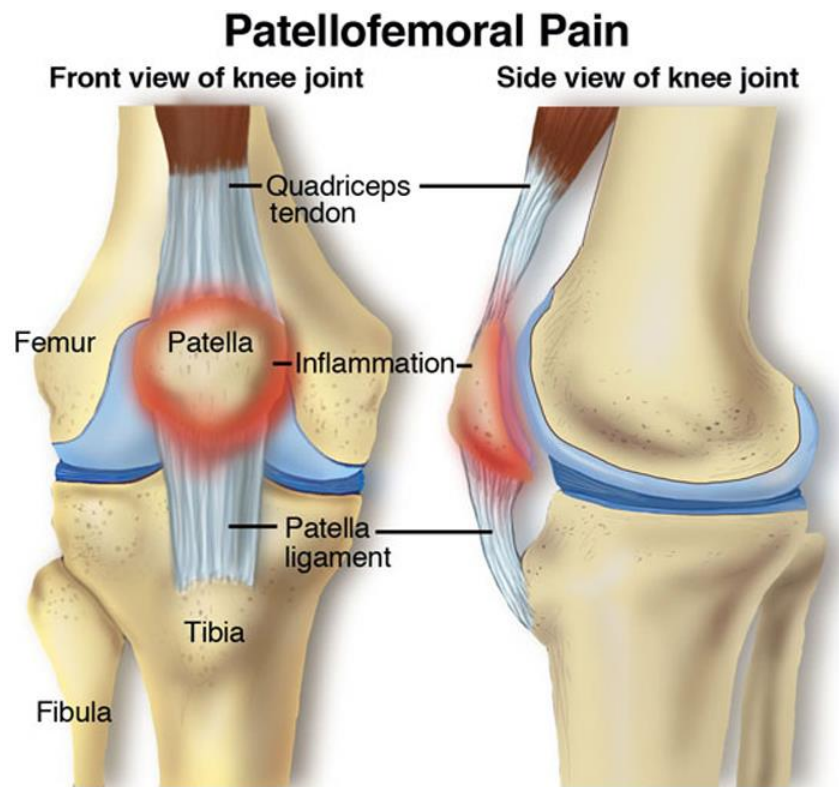

Figure 3: Lateral patella support syndrome [4].

The causes that may affect the muscular balance disorders and the formation of lateral support syndrome of the patella and thigh joint are:

- excessive lateral straplessness
- atrophy of the medial thigh quadriceps muscle head
- limpness of the medial stripe of the patella
- dysplasia of the medial head of the quadriceps thigh muscle [5].
- dysplasia of the lateral condyle of the femur
- antetorsion (internal thigh rotation)
- external rotation of the proximal tibia epiphysis [6]
- valgum genu
- patella alta [7].

Diagnostics of the lateral support syndrome of the patellofemoral joint.

1. Subjective examination

It consists in collecting information concerning the patient, his main complaints, data concerning the current course of treatment, coexisting diseases and past diseases [8].

In order to make a good diagnosis, the patient should be carefully listened to and the origin of pain should be established.

In patients with lateral support syndrome, pain most often occurs when walking upstairs or kneeling. Initially it is intermittent pain, occurring after a longer effort and then it appears more and more often. It is located mainly under the patella, in the area of the lateral side of the knee [9].

2. Physical examination

Viewing

A very important element of the examination of the knee is the examination of a healthy and "sick" knee [10].

The general condition of the patient, both static and dynamic, should be assessed. We observe walk, body structure, posture, proportions and degree of nutrition [8].

Attention should be paid to the deviation of the limb's axis, especially to the anteversion in the hip joint, as increased internal rotation of the thigh and knee top causes compensatory external rotation of the lower leg and increase of the Q angle [11].

Palpation

Touch examination is of great importance for the diagnosis of lateral support syndrome of the patellofemoral joint. The lateral edges of the patella and the area of the lateral trachea attachments are most often sensitive to touch [3]. Moreover, the presence of

exudate, which may accompany the lateral patella support, is easily detected using the symptom of patella balancing. It consists in pressing the patella in the direction of the femur, while the examined person lies with the examined limb slightly bent and completely loosened quadriceps muscle. The presence of exudate causes the kneecap to "sink" into the exudate fluid [12].

Clinical trials

Tilt test

This test is used to evaluate the tension of the lateral strap of the patella. While the test person is lying on his or her back, the test person moves the patella sideways with his or her hands. In the case of a very tight lateral strap, the lateral joint surface of the patella approaches the thigh. If the strapless tension is correct, the position of the patella does not change, and if the strapless is loose, half of the patella rises upwards [13].

The relative and absolute length of the limb and its circumferences should also be measured. Reduced muscle mass, especially of the quadriceps medial head, indicates poor knee function and the predominance of forces lateralizing the patella [3].

Sage Sign

This test is used to assess the lateral strap tension. Knee in a bend of 15° - 20°, relaxed thigh and shin muscles. Press the side edge of the kneecap with your finger to the side of the kneecap and move it towards the medial side. A displacement less than ¼ of the greatest width of the kneecap indicates an excessively tight side strap.

Helpet's Test

It is used to evaluate the external rotation of the shin during the final stage of straightening [3].

3. Additional tests

Radiological examination

The radiological examination complements the findings of the clinical evaluation. Axial pictures of the patella give the most information about the patella and thigh joints. Side support syndrome of the kneecap is usually associated with subchondral sclerotization of the lateral surface of the kneecap, lateralisation of bone beams and traction spur at the lateral edge of the kneecap. The angle of the intercondylar furrow and the angle of congruence are usually preserved [11].

Axial radiographs of the knees

The assessment of the knee bend in the knee bend below 30° is possible with axial pictures of the knee paddles presented by Laurin. The test person lies on the back, feet behind

the edge of the table, knees supported in the bend below 30° so that the thigh muscles are relaxed. The central radius of the X-ray tube shall be parallel to the aperture of the patellofemoral joint and directed from the feet. A disadvantage is that the cassette must be held by another person.

On the basis of the axial images of the bends below 30°, the angle of the kneecap and casing can be measured. It is formed by lines joining the most forward points of the femoral condyle with the line drawn along the edges of the lateral joint surface of the patella. Under normal conditions, the angle is directed towards the medial side.




Fig. 4: The angle of the patella and the casing [4].

Teitge et al. disagree with the need for imaging of the knee joints in relaxed muscles, as they believe that the abnormalities of the patella trajectory occur in active knee movements. According to them, the patellar joint should be imaged on radiograms performed during the operation of the quadriceps muscle of the thigh.

Computed tomography (CT)

Axial computed tomography has many advantages. One of them is its high resolution, which allows to assess the position of the patella in relation to the condylars of femoral bones [3]. Moreover, it is possible to trace the path of patella movement in the final stage of erection, i.e. 20°- 0°, as well as to assess the performance of the quadriceps muscle of the thigh, which cannot be assessed in conventional radiology [12].

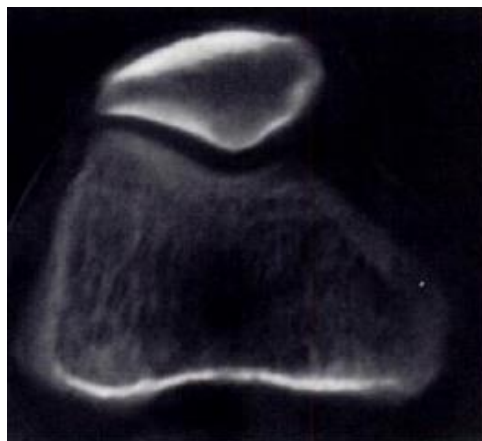


Fig.5: Computed tomography - lateral support of the kneecap [4].

Magnetic resonance imaging (MRI)

Magnetic resonance imaging means higher quality of assessment of the patellofemoral joints without harmful radiation of the patient.

Kinematic MR provides significant information on active and passive patella stabilizers such as the lateral trachea, medial trachea, quadriceps, thigh quadriceps, and patella ligaments, which helps to understand the causes of patella tract disturbances [14].

Arthroscopy

The arthroscopic image gives a lot of information about the position of the patella, so there is a division of the assessment of the wrong position of the patella:

Excessive lateral patella support syndrome - both kneecap joint surfaces are in full contact with each other in the intercondylar groove with slight lateral inclination.

Lateralisation of the patella - joint surfaces of the kneecap in full contact with the intercondylar fissure when bending the knee joint 30° - 60°.

Lateral lateral subluxation of the patella - joint surfaces of the kneecap in full contact with the intercondylar groove with bending of the knee joint above 90° or lack of contact [6].

Summary

The basic method of diagnosing the lateral support syndrome of the patellofemoral joint is subjective and physical examination of the patient. Based on the subjective examination, we are able to make a hypothetical diagnosis, and the subjective examination can easily confirm or exclude it. Imaging tests help to precisely determine the abnormality of which structure is the cause of lateral support of the patellofemoral joint.

REFERENCES:

1. Górecki A.: Uszkodzenia stawu kolanowego. PZWL. Warszawa 2002: 51- 52
2. Chapman M. W.: Operative Orthopaedics Vol. 3. J. B. Lippincott Company Philadelphia 1993: 2065- 2075
3. Modrzewski K.: Stawy rzepkowo- udowe. Wybrane problemy patologii, diagnostyki i terapii. BiFolium. Lublin 1998: 9- 10, 13- 14, 19- 26, 36- 38, 51- 54
4. Figure 1- 5 - www.kneepaininfo.com – 25.03.2018r.- download date
5. Davides A. P., Costa M. L., Donnell S. T., Glasgow M. M., Shepstone L.: The sulcus angle and malalignment of the extensor mechanism of the knee. J Bone Joint Surg [Br] 2000; 82-B: 1162- 1166

6. Calpur O. U. i wsp.: Full arthroscopic lateral retinacular release with hook knife and quadriceps pressure-pull test: long-term follow-up. *Knee Surg, Sports Traumatol, Arthrosc* 2005, 13 (3): 222- 230
7. Calpur O. U. i wsp.: Arthroscopic mediopatellar plicaectomy and lateral retinacular release in mechanical patellofemoral disorders. *Knee Surg, Sports Traumatol, Arthrosc* 2002, 10 (3): 177- 183
8. Gaździk: *Ortopedia i Traumatologia. Podręcznik dla studentów medycyny.* PZWL. Warszawa 2005: 18- 19
9. Fulkerson J. P.: *Diagnosis and Treatment of Patients with Patellofemoral Pain.* *Am J of Sports Med* 2002; 30 (3): 447- 456
10. Hagner W., Stec G. *Urazy stawu kolanowego (część 1) więzadło krzyżowe przednie.* *Script Bydgoszcz.* 2004: 20- 21, 24, 32, 84
11. Widuchowski J. *Kolano urazy i obrażenia sportowe.* G- Kwadrat. Katowice 1997: 164- 166
12. Zembaty A.: *Kinezyterapia. Tom 1.* Kasper. Kraków 2002: 480- 481
13. Buckup K.: *Testy kliniczne w badaniu kości, stawów i mięśni.* PZWL. Warszawa 2002: 155
14. Shellock F. G., Mink J. H., Deutsch A. L., Fox J. M.: *Patellar Tracking Abnormalities: Clinical Experience with Kinematic MR Imaging in 130 Patient.* *Radiology* 1989; 172: 799- 804