

Unstable atherosclerotic plaque of the internal carotid artery in the case of a patient with high surgical risk treated endovascularly

Michał Terpiłowski¹, Jędrzej Tkaczyk¹, Barbara Klatka¹, Klaudia Brożyna¹,
Magdalena Hołowczuk¹, Jan Jakub Kęsik², Marek Ilzecki²

1. Students' Scientific Society at the Department of Vascular Surgery and Angiology, Medical University of Lublin
2. Department of Vascular Surgery and Angiology, Medical University of Lublin

Abstract

Introduction: Internal carotid artery (ICA) stenosis in a majority is caused by atherosclerotic plaque. Symptoms of ICA stenosis manifest most likely a transient ischemic attack (TIA). The dynamics of ICA stenosis progression is unpredictable, the disease may progress quickly or slowly or remain stable for many years. The method of treatment implemented also depends on it. The task of pharmacological treatment is to reduce the progression of the disease and protect against the onset of stroke. Among the invasive methods of treating ICA stenosis, the standard procedure is endarterectomy of a carotid artery (CEA), i.e. surgical removal of atherosclerotic plaque. Another method of treatment is endovascular carotid artery stenting (CAS). CAS should be considered especially in the case of re-operated patients, also after radiotherapy and tracheostomy. CAS is a less invasive procedure, it avoids complications typical for CEA such as cranial nerve palsy or complications at the site of the wound. On the other hand, the risk of postoperative ischemic stroke is greater in the case of CAS. In recent years, the improved CAS method seems to be the implantation of dual-layered mesh-covered carotid stent systems (DLS).

Case report: We present the case of a 69 old man, long-term smoker, with hypertension and coronary heart disease. In 2001 diagnosed with larynx cancer and underwent surgical laryngectomy and radiotherapy. He was admitted in scheduled mode due to symptomatic carotid artery stenosis. In USG examination there was visible stenosis of the right internal carotid artery (80%) caused by an

unstable atherosclerotic plaque with irregular structure and thrombotic clots. Due to the obvious difficulties of performing endarterectomy following radiotherapy in the neck area and laryngectomy, the endovascular method has been considered. In spite of the unstable plaque, which is a contraindication to perform the endovascular procedures CAS has been decided to perform. The patient underwent implantation of a dual-layered carotid stent in the combination with proximal balloon occlusion protection with a MoMa device. After procedure arteriography confirmed the optimization of the carotid artery flow and the correct position of the stent. The treatment was carried out without complications. After a few days of hospitalization, the patient was discharged home.

Discussion: The method of treatment of internal carotid artery stenosis is selected taking into consideration morphology and localization of atherosclerotic plaque, anatomical conditions and the local condition of the surgical area as well as the general condition of the patient and coexisting diseases. On the one hand, the patient underwent cervical radiotherapy and laryngectomy which are contraindications for CEA. On the other hand, an atherosclerotic plaque was unstable with the features of stratification which is a contraindication to the performance of CAS. In the described case it was decided to make implantation of dual-layered carotid stent system (DLS) connected with proximal balloon occlusion protection with a MoMa device allowed to reduce the risk of embolization.

Keywords: carotid artery; stenosis; stenting; atherosclerotic plaque; mesh

Introduction

Internal carotid artery (ICA) stenosis is a significant clinical problem. In 20-25% it leads to ischemic brain stroke [1]. The majority of stenoses and obstructions located in the ICA are caused by atherosclerotic plaque. The morphology of the atherosclerotic plaque is thought to be one of the most important factors in determining its stability. Furthermore, it is important in the development of spontaneous symptoms in the carotid arteries and it has an impact on the selection of methods of treatment [2]. Symptoms of ICA stenosis manifest most likely a transient ischemic attack (TIA) which is the result of temporary interruption of blood flow to the brain and subsequent restoration within a few minutes. Through the symptoms of a TIA or an ischemic stroke we can distinguish weakness or numbness in an arm or leg, difficulty speaking, a drooping face, vision problems or paralysis affecting one side of the body [3]. According to the recommendations made by the European Society of Cardiology and the European Society for Cardio Vascular Surgery, carotid treatment depends on a past episode of TIA and the degree of carotid stenosis (table 1). The dynamics of ICA stenosis progression is unpredictable, the disease may progress quickly or slowly or remain stable for many years. The method of treatment implemented also depends on it. The task of pharmacological treatment is to reduce the progression of the disease and protect against the onset of stroke. Antiplatelet drugs have been shown to reduce the incidence of stroke, and statins have stabilized atherosclerotic plaque [4]. Among the invasive methods of treating ICA stenosis, the standard procedure is endarterectomy of a carotid artery (CEA), i.e. surgical removal of atherosclerotic plaque. Another method of treatment is endovascular carotid artery stenting (CAS). CAS should be considered especially in the case of re-operated patients, also after radiotherapy, tracheostomy, with paralysis of vocal cords, obese, narrowing of the carotid artery elsewhere and severe coexisting diseases which are a contraindication to CEA. However, CAS is contraindicated when the ICA diameter is less than 3 mm, when plaque has an irregular morphology with the presence of thrombi and features of instability and when massive calcifications in the aortic arch obstruct the passage of the intravascular catheter [5]. CAS is a less invasive procedure, it avoids complications typical for CEA such as cranial nerve palsy or complications at the site of the wound. In addition, this procedure has a lower incidence of complications in the form of myocardial infarction compared to CEA [6]. On the other hand, the risk of postoperative ischemic stroke is greater in the case of CAS, because during implantation of the stent into the vessel wall there is a

high risk of detachment of the atherosclerotic plaque. In recent years, the improved CAS method seems to be the implantation of dual-layered mesh-covered carotid stent systems (DLS).

Case Report

We present the case of a 69 old man, long-term smoker, with hypertension and coronary heart disease. In 2001 diagnosed with larynx cancer and underwent surgical laryngectomy and radiotherapy. He was admitted in scheduled mode due to symptomatic carotid artery stenosis to The Department of Vascular Surgery and Angiology. In USG examination there was visible stenosis of the right internal carotid artery (80%) caused by an unstable atherosclerotic plaque with irregular structure and thrombotic clots. An abnormal structure of the atherosclerotic plaque was confirmed by angiography (Figure 1). Due to the obvious difficulties of performing endarterectomy following radiotherapy in the neck area and laryngectomy, the endovascular method has been considered. In spite of the unstable plaque, which is a contraindication to perform the endovascular procedures CAS has been decided to perform. During the patient's preparation before procedure, a double antiplatelet therapy with acetylsalicylic acid and clopidogrel was implemented. The patient underwent implantation of a dual-layered carotid stent in the combination with proximal balloon occlusion protection with a MoMa device (Figure 2). Postoperative arteriography confirmed the optimization of the carotid artery flow and the correct position of the stent. Contrast revealed remains of the dissection of the atherosclerotic plaque, however, the use of DLS eliminates the risk of recurrence of fragments of the atherosclerotic plaque into the lumen of the artery (Figure 3). The treatment was carried out without complications. After a few days of hospitalization, the patient was discharged home in good general condition with recommendations for preventive pharmacotherapy which includes acetylsalicylic acid, clopidogrel, and atorvastatin.

Table 1.

Recommendations on carotid artery procedures in patients after a TIA episode [3]	Class of recommendations/level of evidence
Endarterectomy (CEA) or angioplasty (CAS) of the carotid arteries is recommended in patients with 70-99% stenosis	I/C
The treatment may be considered in men with 50-69% stenosis if the central nervous system ischemic symptoms have occurred in less than 6 months.	IIb/C
The treatment is not recommended in men with stenosis <50% and in women with stenosis <70%	III/C
Recommendations on carotid artery procedures in patients with asymptomatic stenosis [3]	Class of recommendations/level of evidence
The treatment may be considered in men with bilateral stenosis of 70-99% or if the stenosis and contralateral obstruction of the artery coexist	IIb/C
The treatment is not recommended in patients with expected survival <5 years	III/C

Figure 1. Arteriography of the aortic arch branches. Visible stenosis of the right internal carotid artery with high-risk atherosclerotic plaque.

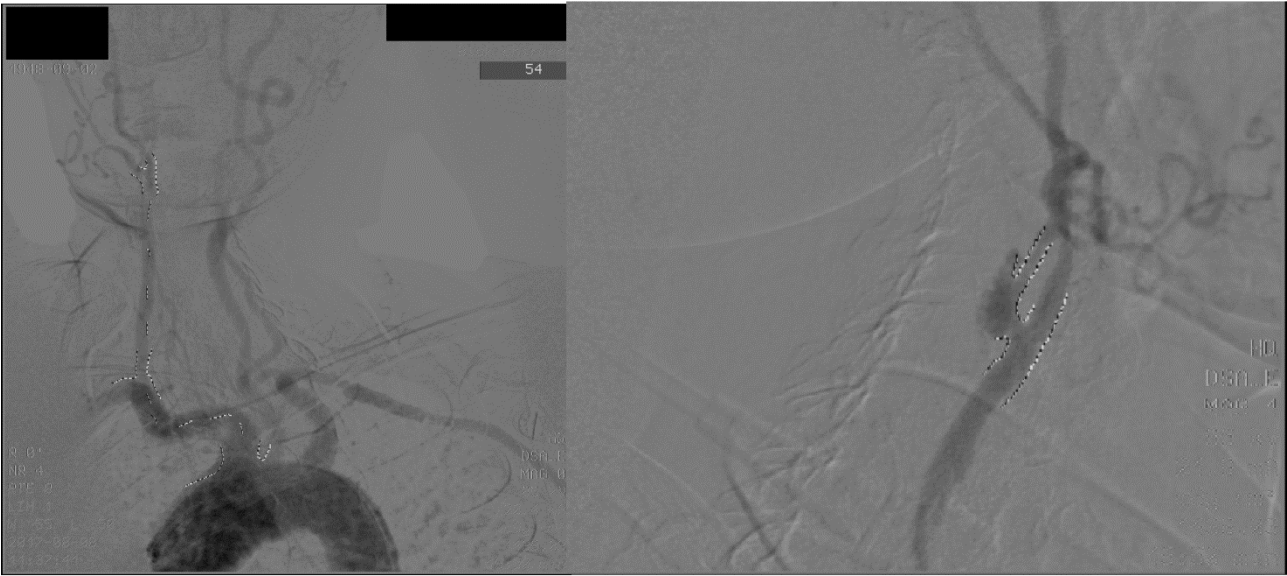


Figure 2. Arteriography during the procedure. Visible proximal balloon occlusion protection with a MoMa device

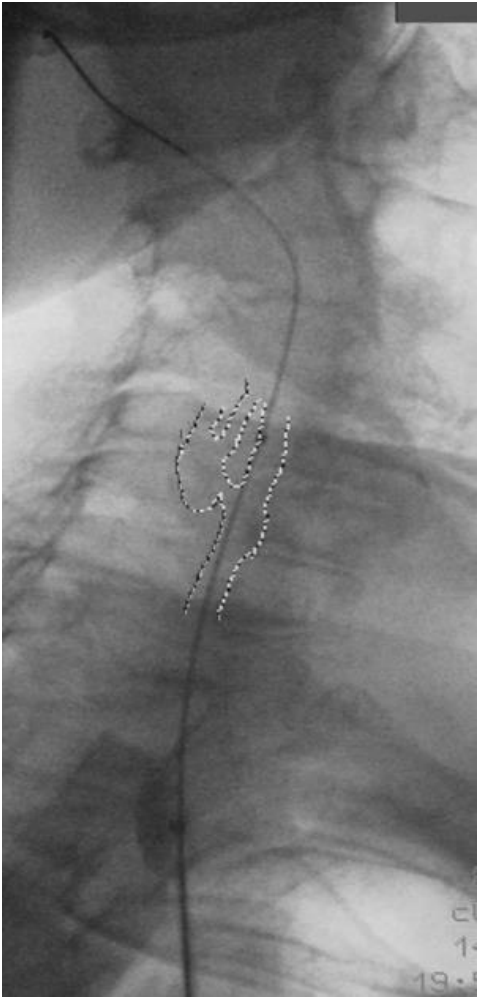
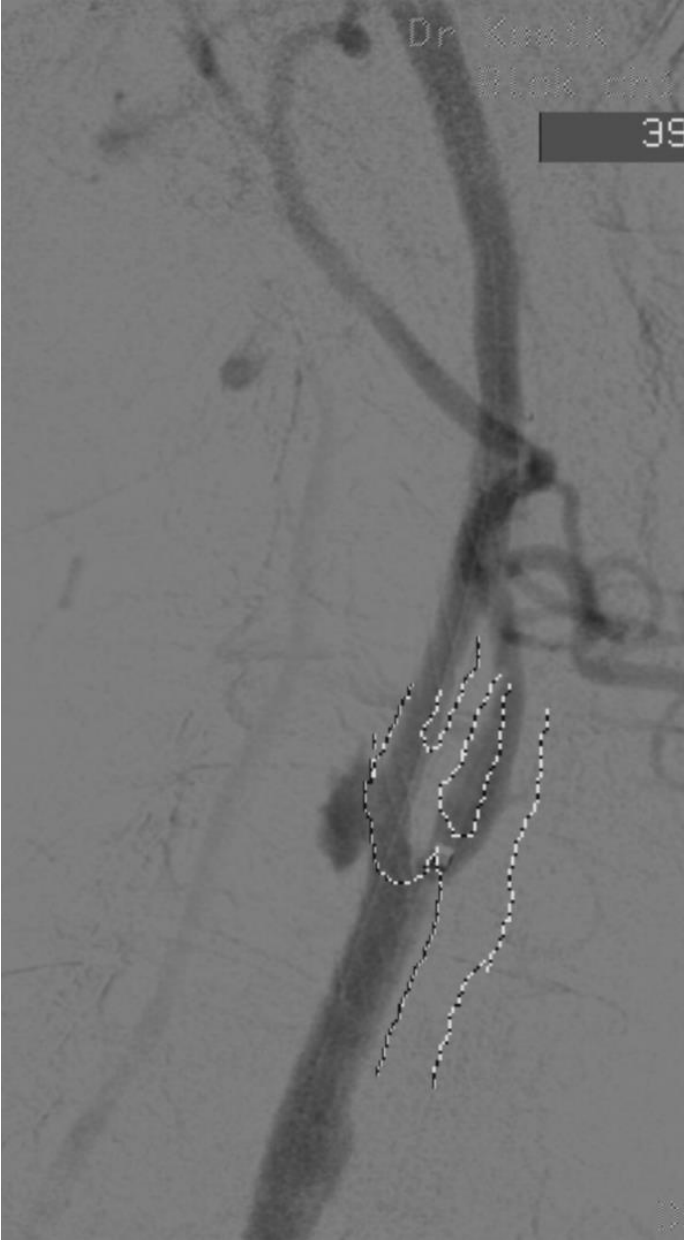


Figure 3. Post-operative arteriography. Confirmation of the optimization of the carotid artery flow and the correct position of the stent.



Discussion

The method of treatment of internal carotid artery stenosis is selected taking into consideration morphology and localization of atherosclerotic plaque, anatomical conditions and the local condition of the surgical area as well as the general condition of the patient and coexisting diseases [7]. On the one hand, the patient underwent cervical radiotherapy and laryngectomy which are contraindications for CEA [4]. On the other hand, an atherosclerotic plaque was unstable with the features of stratification which is a contraindication to the performance of CAS due to the high risk of postoperative complications such as ischemic stroke and death [8]. In the described case it was decided to make implantation of dual-layered carotid stent system (DLS) connected with proximal balloon occlusion protection with a MoMa device. In a recent study by Montorsi et al., it has been shown that proximal balloon occlusion protection with a MoMa device had a lower number of microembolic signals (MES) assessed by transcranial Doppler compared with the distal filter protection group [9]. DLS consists of a nitinol layer with thin mesh. This structure is intended to eliminate the risk of embolization of the plaque during the implantation of the stent to the vessel wall [10]. The advantage of a mesh-covered stent is a free cell area ranging from 0.18 to 0.50mm², whereas existing closed cell and open cell stents have a free cell area ranging from 1.1-4.4mm² to 6.0-11.5mm²[11]. According to the ICSS trial, the rate of procedural stroke or ipsilateral stroke was 9% in the CAS, whereas in CEA the number of strokes was reaching 4.7% at one year. In the CREST trial, the rate of ipsilateral stroke at one year was 6% in the CAS group versus 2.8% in the CEA. The CLEAR-ROAD trial which examined complications after implantation of DLS showed lack of ipsilateral stroke in 95.8% cases during 12 months [12]. Comparison of these trials shows that the DLS is an appropriate treatment for ICA stenosis in patients who have contraindications to performing CEA, having at the same time high-risk atherosclerotic plaque which is a contraindication to CAS. In our case, the use of DLS and proximal balloon occlusion protection with a MoMa device allowed to reduce the risk of embolization.

Bibliography

1. Dyken M: Stroke risk factors in the prevention of stroke. W: Norris JW, Hachinski VC (red.): Prevention of Stroke. Springer-Verlag, New York 1991: 83–102.
2. Bicknell CD, Cheshire NJ. The relationship between carotid atherosclerotic plaque morphology and the embolic risk during endovascular therapy. *Eur J Vasc Endovasc Surg*. 2003 Jul;26(1):17-21.
3. Guidelines on myocardial revascularization Guidelines on myocardial revascularization. The Task Force on Myocardial Revascularization of the European Society of Cardiology (ESC) and the European Association for Cardio-Thoracic Surgery (EACTS). *Eur Heart J* 2010; 31: 2501-2555
4. C.D. Liapis, Sir P.R.F. Bell, D. Mikhailidis, J. Sivenius, A. Nicolaides, J. Fernandes e Fernandes, G. Biasi, L. Norgren: European Society of Vascular Surgery (ESVS) guidelines. Invasive treatment for carotid stenosis: indications, techniques *Eur J Vasc Endovasc Surg* 2009; 37: S1–S19
5. Ścibisz A, Michalak M, Kochman J. Angioplastyka tętnic szyjnych w świetle najnowszych wytycznych *Kardiologia po Dyplomie* 2011; 10 (6): 70-75
6. Silver FL, Mackey A, Clark WM, Brooks W, Timaran CH, Chiu D, et al. Safety of stenting and endarterectomy by symptomatic status in the Carotid Revascularization Endarterectomy Versus Stenting Trial (CREST). *Stroke*. 2011 Mar;42(3):675-80.
7. Schneider, P. A., Kasirajan, K. (2007). Difficult Anatomy: What Characteristics Are Critical to Good Outcomes of Either CEA or CAS? *Seminars in Vascular Surgery*, 20(4), 216–225. doi:10.1053/j.semvascsurg.2007.10.005
8. Yamada K., Yoshimura, S., Kawasaki, M., Enomoto, Y., Asano, T., Hara, A., ... Iwama, T. (2011). Embolic complications after carotid artery stenting or carotid endarterectomy are associated with tissue characteristics of carotid plaques evaluated by magnetic resonance

- imaging. *Atherosclerosis*, 215(2), 399–404.
9. Tatli E, Buturak A, Grunduz Y, et al. Comparison of anti-embolic protection with proximal balloon occlusion and filter devices during carotid artery stenting: clinical and procedural outcomes. *Postepy Kardiologii Interwencyjnej*. 2013;9(3):221-7.
 10. Stabile E, Tesorio T, Esposito G. The modern approach to endovascular carotid revascularisation. *EuroIntervention* 2016;12:e538–40
 11. Carly N. Richards and Peter A. Schneider, Will Mesh-covered stents help reduce stroke associated with carotid stent-angioplasty?, *Seminars in Vascular Surgery*, ISSN: 1558-4518, Vol: 30, Issue: 1, Page: 25-30
 12. Bosiers M, Deloose K, Torsello G, Scheinert D, Maene L, Peeters P, Müller-Hülsbeck S, Sievert H, Langhoff R, Callaert J, Setacci C, Wauters J. :Evaluation of a new dual-layer micromesh stent system for the carotid artery: 12-month results from the CLEAR-ROAD study. *EuroIntervention*. 2018 Nov 20;14(10):1144-1146