






## Extramedullary plasmacytoma diagnosed by fine needle aspiration and flow cytometry – case report


Name Katarzyna Karwicka   
ORCID iD <http://orcid.org/0000-0003-0542-5991>  
Affiliation Department of Haemato-oncology and Bone Marrow Transplantation, I Faculty of Medicine with Dentistry Division, Medical University of Lublin  
Country Poland  
Bio Statement —  
Principal contact for editorial correspondence.


Name Olga Czabak   
ORCID iD <http://orcid.org/0000-0002-9083-9058>  
Affiliation Department of Haemato-oncology and Bone Marrow Transplantation, I Faculty of Medicine with Dentistry Division, Medical University of Lublin  
Country Poland  
Bio Statement —

Name Magdalena Koziol   
ORCID iD <http://orcid.org/0000-0001-7520-1067>  
Affiliation Department of Haemato-oncology and Bone Marrow Transplantation, I Faculty of Medicine with Dentistry Division, Medical University of Lublin  
Country Poland  
Bio Statement —

Name Aneta Szudy-Szczyrek   
ORCID iD <http://orcid.org/0000-0003-2352-394X>  
Affiliation Department of Haemato-oncology and Bone Marrow Transplantation, I Faculty of Medicine with Dentistry Division, Medical University of Lublin  
Country Poland  
Bio Statement —

Name Aneta Gorący   
ORCID iD <http://orcid.org/0000-0001-8758-0981>  
Affiliation Department of Haemato-oncology and Bone Marrow Transplantation, I Faculty of Medicine with Dentistry Division, Medical University of Lublin  
Country Poland  
Bio Statement —

Name Maria Soroka-Wojtaszko   
ORCID iD <http://orcid.org/0000-0002-7977-8418>  
Affiliation Department of Haemato-oncology and Bone Marrow Transplantation, I Faculty of Medicine with Dentistry Division, Medical University of Lublin  
Country Poland  
Bio Statement —

Name Marek Hus   
ORCID iD <http://orcid.org/0000-0002-9036-6625>  
Affiliation Department of Haemato-oncology and Bone Marrow Transplantation, I Faculty of Medicine with Dentistry Division, Medical University of Lublin  
Country Poland  
Bio Statement —

## Abstract

The case report presents a patient diagnosed as IgA  $\kappa$  type multiple myeloma (MM) (stage IIIA Durie Salmon stage, with ISS3). The patient was presenting with feature of progressive disease, complicated with extramedullary presentation. There was a discrepancy between histopathology result suggestive alternative diagnosis and clinical presentation compatible with MM. The diagnostic fine needle aspiration biopsy has been made. The samples were examined using the flow cytometry, which showed the presence population of monoclonal plasma cells. The final diagnosis of nodule revealed infiltration of plasma cells and was possible following the cytometric analysis of FNA biopsy

Key words: Multiple myeloma; plasma cells; plasmacytoma; flow cytometry

## Introduction

Multiple myeloma (MM) is a malignant neoplastic disease characterized by the clonal proliferation of atypical plasma cells in the bone marrow, which is usually accompanied by the overproduction of abnormal monoclonal protein. It represents about 0,8% of all malignant diseases and is the third most common hematologic malignancy. Median age at diagnosis is currently 69 years. It occurs more common in men.

Symptomatology of the disease is very diverse. First symptoms are usually non specific - there may include low grade fever, weakness, weight loss and recurrent infections. The disease leads to bone loss, pathological fractures, bone marrow failure and kidney damage. Unfortunately, the diagnosis of the disease is usually made, at an advanced stage, when multi-organ damage is known as CRAB acronym (C - hypercalcemia, R - renal failure, A - anemia, B - bone lesions).

In the last 30 years there was a progress in the treatment of MM associated with the introduction of new immunomodulatory drugs (IMiDs) and proteasome inhibitors, which resulted in improvement in overall survival (OS) relative to previous observations. According to current statistics, the percentage of 5-year survival is 48,5% and median OS reaches over 6 years. Unfortunately, MM remains an incurable disease [1,2].

## Case report

66-years old patient was admitted to Department of Haemato-oncology and Bone Marrow Transplantation in Lublin in February 2018. He was presenting with chest bone pains, weight loss and mental confusion for further diagnosis and treatment. On admission blood tests revealed normocytic anaemia with haemoglobin level 9g/dl, [lab normal range] hypercalcaemia (Ca level – 3,47 mmol/L) [local lab normal range values] elevated creatinine level (1,99 mg/dl)[local lab normal range value], elevated IgA level – 6,1 g/L (N: 0,7-4 g/L). His past medical history was unremarkable, medical examination did not revealed significant abnormalities.

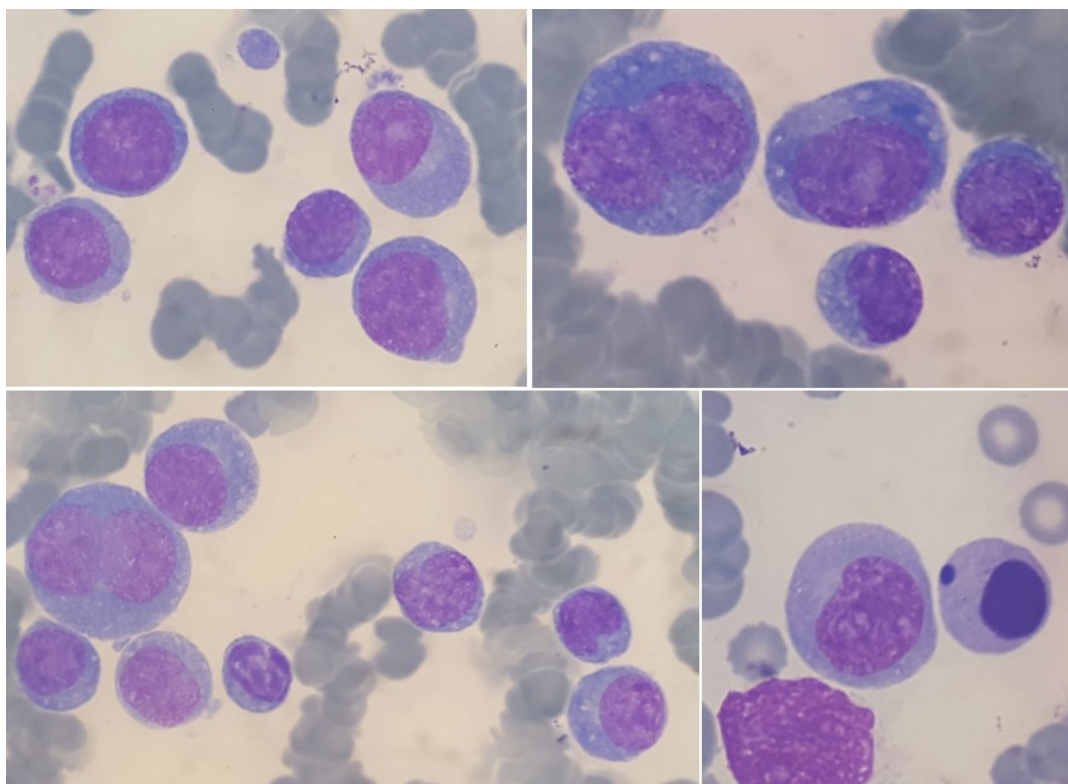
The clinical presentation and laboratory results were compatible with (MM). The diagnosis has been confirmed bone marrow aspiration biopsy and results of protein electrophoresis with immunofixation which showed presence of IgA monoclonal kappa protein at level 1,87 g/dl. The bone marrow biopsy revealed dominant population plasma cells – 68% with presence of large plasma cells with low-density chromatin structure. The flow cytometry of bone marrow revealed presence of monoclonal plasma cells

– 53% cells with the presence of antigens: CD138+, CD38+, CD45-, CD19-, CD56+, CytKappa+. The FISH analysis of bone marrow was positive for: del 17p13.1 and t(4;14) (p16;q32), usually associated with the high cytogenetic risk of poor prognosis.

The Low - Dose Computed Tomography (LDCT) showed the presence of the osteolytic involvement of the bones. The final diagnosis was: multiple myeloma IgA  $\kappa$  type, stage IIIA Durie Salmon stage, ISS3. The Patient started VTD therapy (Thalidomide combined with Bortezomib, and Dexamethasone). Because of the severe bone pain, especially in the pelvis, the radiotherapy of this area was performed in March 2018r. X-ray of right clavicle – showed pathological fracture of the bone, therefore local radiotherapy has been applied in May 2018r.

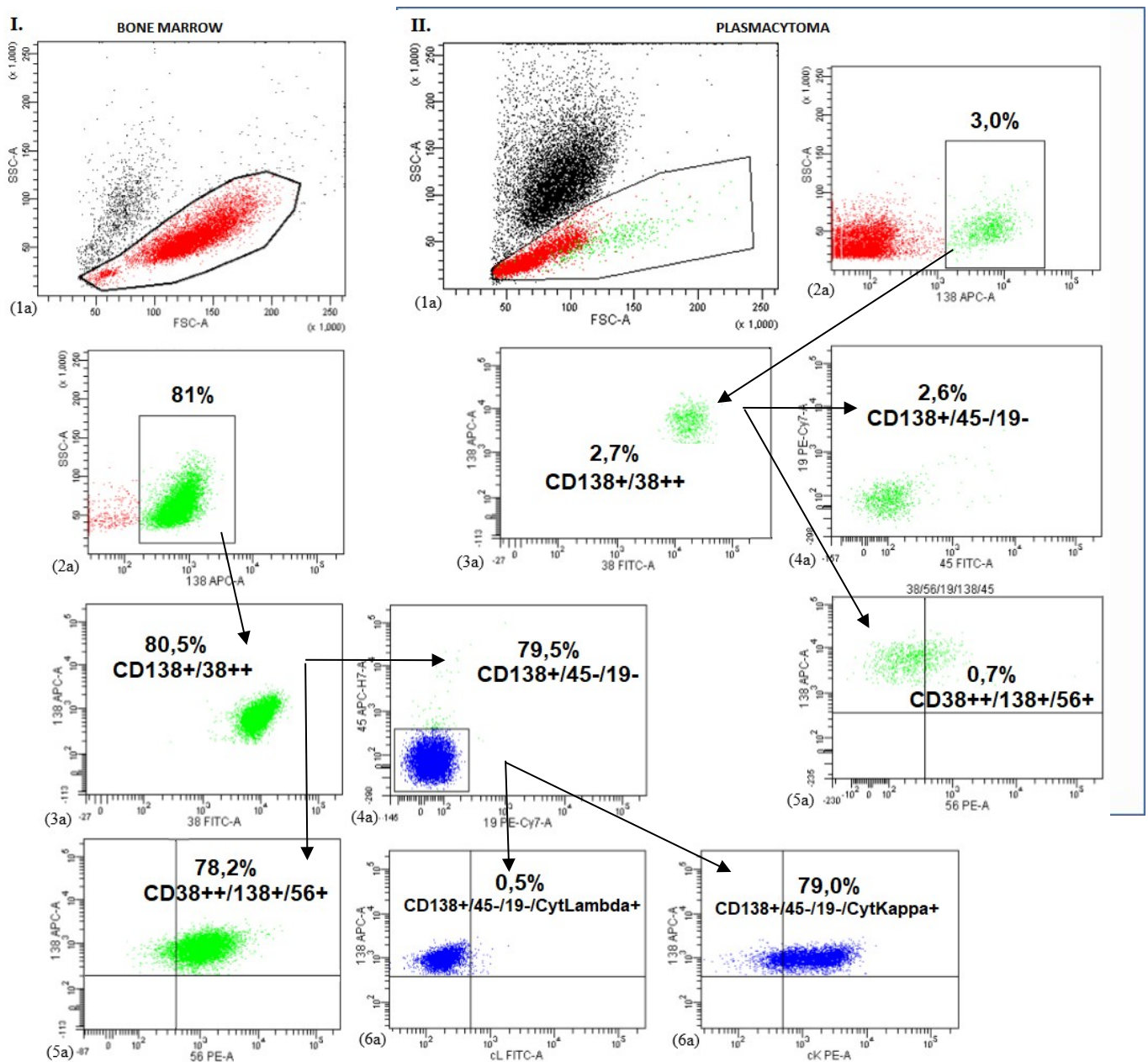
The response evaluation following 4 cycles of VTD chemotherapy showed reduction of 96% monoclonal proteins which was compatible with very good partial response (VGPR) according to the International Myeloma Working Group (IMWG). In July 2018 the autologous hematopoietic stem cell transplantation (AH SCT) procedure has been proposed, but not consented by the patient. VTD chemotherapy has been planned to continue up to 8 courses. Before the 7th VTD course of, in September 2018 a solid infiltration of the right side of the neck and the chest appeared. In the ultrasound imaging the infiltration corresponded with conglomerate of hypoechogenic lymph nodes with strong peripheral vascularity. Lymph node mass has been removed in the Surgical Department. The LDCT was repeated showing massive osteolytic involvement of bones.

In the routine blood smear assessment the plasmablastic cells were present, what may be suggestive of early plasma cell leukemia transformation. As a next step the bone marrow aspiration was performed and revealed presence of plasma cells and plasmablastic cells (Fig. 1.) The flow cytometry of bone marrow cells confirmed the presence of monoclonal plasma cells identical to the first immunophenotypic test result (CD138+, CD38+, CD45-, CD19-, CD56+, CytKappa+). The percentage of CD38+/138+/45-/19- monoclonal plasma cells was 79,5% cells, among which the proportion of CD138+/45-/19-/CytKappa+ was 79,0% cells (Fig. 2).



**Figure 1. Bone marrow smear with plasma cells and plasmablastic cells.**

Second line chemotherapy based on Lenalidomide with Dexamethasone (Rd) has been started. During the first course of the treatment the histopathology result of tumour was obtained. The description suggested undifferentiated lung cancer (immunohistochemical results cytokeratin (CK+), chromogranin (-) and synaptophysin (+). Due to the unexpected result not corresponding with the clinical course the diagnostic fine needle biopsy was made. The samples were examined using the flow cytometry, which showed the presence of monoclonal plasma cells. The percentage of plasma cells in the tumour was approx. 2,6% of cells (Fig. 1.). The treatment was escalated by adding 2 weeks monthly ixazomib therapy, in addition to RD chemotherapy protocol. Patient died two months later, despite intensive chemotherapy and radiotherapy.



**Figure 2. Side-by-side comparison of plasma cell bone marrow (BM) sample I and biological material coming from a neck mass (EP) II by flow cytometry.**

(1a) An acquisition gate was put on lymphocytes, monocytes and plasmocytes in keeping with forward and side scatter (respectively: FSC, SSC) qualities. (3a) The double positive subpopulation CD138+ and CD38++ was chosen from gate (2a) SSC+138+, which plasma cells separated (BM 81%; EP 3%). The percentage of cells with

(4a) CD19-, CD45-, (5a) CD56+ was estimated among plasma cells (SSC+38++138+). In the case of EP, we observe the lack expression of the CD56 marker. Selective gating on this CD138+/45-/19- plasma cells population reveals them to be monoclonal for CytKappa Ig light chains (6a) and absence of CytLambda Ig light chains expression. In the second case, CytLambda and CytKappa were not labelled. Nevertheless, the obtained immunophenotype profile was compatible with monoclonal plasma cell dyscrasia.

The diagnostic panel for plasma cell disorders contained Mouse Anti-Human monoclonal antibodies CD38-FITC, CD56-PE, CD19-PE-Cy7, CD138-APC, CD45-APC-H7 for the presented patient. Tube 2 was composed by a combination of the Mouse Anti-Human Ig light chain lambda (FITC) with kappa (PE) antibodies intracellular determined and CD19-PE-Cy7, CD138-APC, CD45-APC-H7 (BD Biosciences).

\*\* FITC, fluorescein isothiocyanate; PE, phycoerythrin; Per Cy7, peridinin cyanin7; APC, allophycocyanin; H7, Hillite 7; Cyt, cytoplasmic; Ig, immunoglobulin; EP, extramedullary plasmacytoma

## Discussion

Fine-needle aspiration cytology (FNAC) is an easy, safe and unexpensive , procedure. The material necessary for examination of cells in fluid may be accessed easily in the quickest, and at the same time, least invasive way. As a result, a major surgical biopsy is avoided and there is no need for hospitalization. Since MM is focal disease negative result does not exclude MM diagnosis and may lead to trephine biopsy study. Diagnostic accuracy depends on the particular site being sampled and the type of subcutaneous nodules. However, in general, high specificity and sensitivity have been observed in metastatic disease. FNAC might be helpful as the first line of investigation, but it does not have to be the basis for making a diagnosis. It can be used as a support in the diagnosis of disease [3]. In the case of extramedullary plasmacytoma, clinical symptoms and findings of investigation may be unclear and incorrectly classified as other soft tissue tumors [4]. The finding of a nodule composed of plasmacytoid cells was possible due to result of the cytometric analysis of outcomes obtained following FNAC.

Multiparameter flow cytometry (MFC) is often underestimated in the diagnosis of plasma cells. The percentage of plasma cells is repeatedly inadequate as compared to other laboratory methods. The advantages of flow cytometry , differential diagnosis between reactive, malignant plasma cell dyscrasias vs other lymphomas/leukemias. Verification of cell monoclonality and has also prognostic prognostic value [5]. Immunophenotype examination revealed the expression of CD138+/38<sup>high</sup>/45-/19- antigens which are characteristic for the detection of aberrant plasma cells in bone marrow [6,7]. Aberrant plasma cell immunophenotype in BM includes also overexpression of CD56 marker. Absence of CD56 expression might be associated with extramedullary dissemination (i.e., extramedullary plasmacytomas) and has worse prognosis [7,8].

## References

1. Morse D, Dailey RC, Bunn J. *Prehistoric multiple myeloma*. Bull N Y Acad Med. 1974; 50: 447-458.
2. Solly S. *Remarks on the pathology of mollities ossium; with cases*. Med Chir Trans. 1844; 27: 435-498.
3. Roskell DE, Buley ID. *Fine needle aspiration cytology in cancer diagnosis*. BMJ. 2004; 329 (7460): 244-245.
4. Bhat RV, Iyengar KR. *Soft tissue plasmacytoma diagnosed by fine needle aspiration cytology*. Acta cytologica, 2001; 45 (3): 481-483.
5. Jelinek T, et al. *Current applications of multiparameter flow cytometry in plasma cell disorders*. Blood cancer journal, 2017; 7(10): e617

6. Flores-Montero J, de Tute R, Paiva B, et al. *Immunophenotype of Normal vs. Myeloma Plasma Cells: Toward Antibody Panel Specifications for MRD Detection in Multiple Myeloma*. *Cytometry Part B* 2016; 90B: 61–72.
7. Kumar S, Kimlinger T, Morice W. *Immunophenotyping in multiple myeloma and related plasma cell disorders*. *Best Pract Res Clin Haematol*. 2010; 23(3): 433-451.
8. Lin P, Owens R, Tricot G, et. al. *Flow Cytometric Immunophenotypic Analysis of 306 Cases of Multiple Myeloma*. *Am J Clin Pathol* 2004; 121: 482-488.