

Hys Michal, Kempisty Jakub, Budny Agnieszka, Baranowska-Kempisty Katarzyna, Rutyna Rafal. Massive burn >90% of body surface – case report. *Journal of Education, Health and Sport*. 2019;9(2):362-366. eISSN 2391-8306. DOI <http://dx.doi.org/10.5281/zenodo.2577937>  
<http://ojs.ukw.edu.pl/index.php/johs/article/view/6622>

The journal has had 7 points in Ministry of Science and Higher Education parametric evaluation. Part B item 1223 (26/01/2017).  
1223 Journal of Education, Health and Sport eISSN 2391-8306 7

© The Authors 2019;

This article is published with open access at Licensee Open Journal Systems of Kazimierz Wielki University in Bydgoszcz, Poland  
Open Access. This article is distributed under the terms of the Creative Commons Attribution Noncommercial License which permits any noncommercial use, distribution, and reproduction in any medium, provided the original author (s) and source are credited. This is an open access article licensed under the terms of the Creative Commons Attribution Non commercial license Share alike. (<http://creativecommons.org/licenses/by-nc-sa/4.0/>) which permits unrestricted, non commercial use, distribution and reproduction in any medium, provided the work is properly cited.

The authors declare that there is no conflict of interests regarding the publication of this paper.

Received: 30.01.2019. Revised: 30.01.2019. Accepted: 25.02.2019.

## **Massive burn > 90% of body surface – case report**

**Michal Hys<sup>[1]</sup>, Jakub Kempisty<sup>[2]</sup>, Agnieszka Budny<sup>[3]</sup>,  
Katarzyna Baranowska-Kempisty<sup>[4]</sup>, Rafal Rutyna<sup>[1]</sup>**

<sup>[1]</sup> Chair of Anaesthesiology and Intensive Therapy with Clinical Paediatric Department, Medical University of Lublin

<sup>[2]</sup> Chair of Urology and Oncologic Urology, Teaching Hospital No 1 in Rzeszow

<sup>[3]</sup> St. John`s Cancer Center in Lublin

<sup>[4]</sup> Chair of Otolaryngology, Teaching Hospital No 1 in Rzeszow

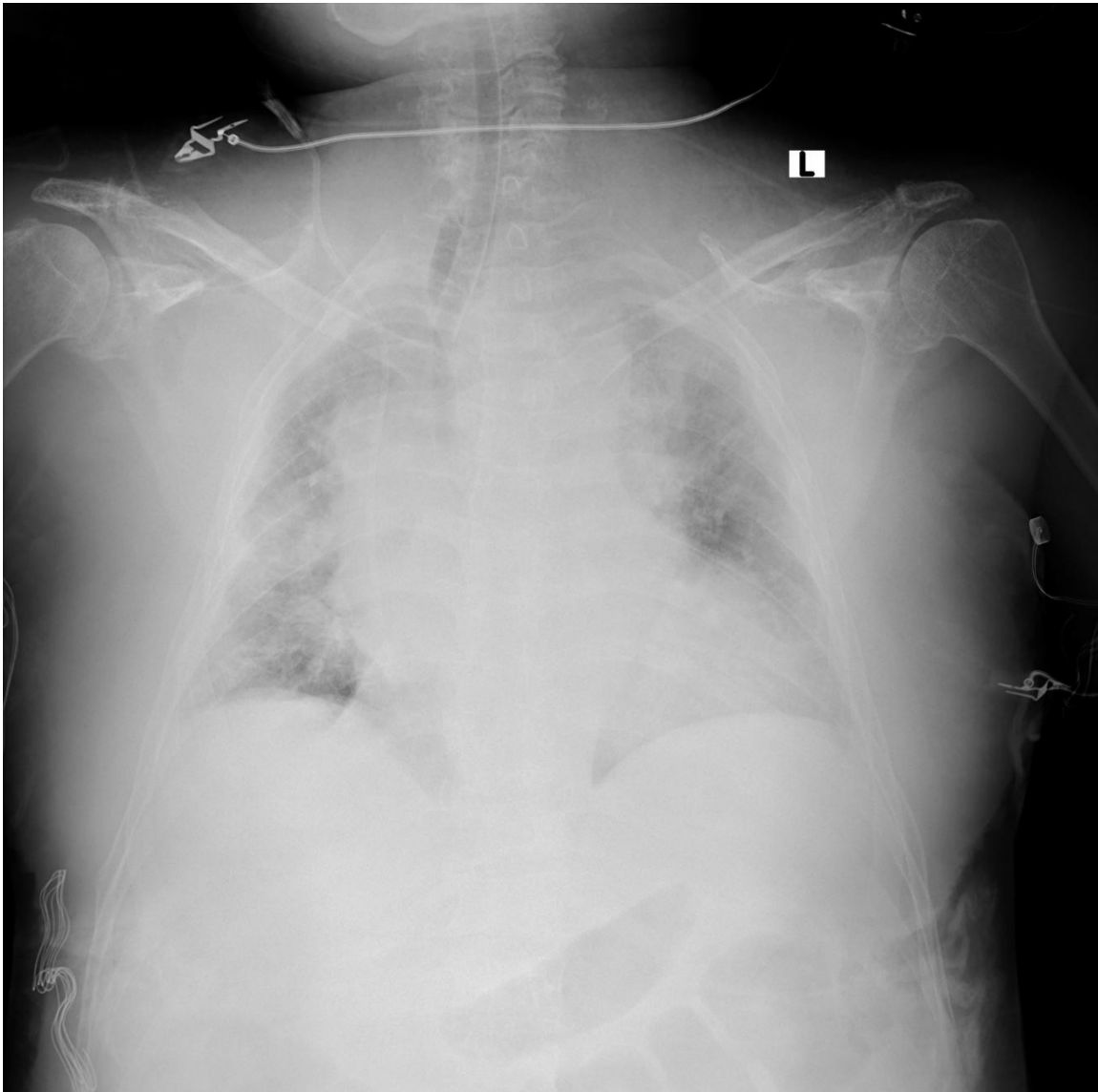
### **Abstract:**

Severe burns are life-threatening injuries very difficult to heal. Multidisciplinary treatment is necessary due to complicated pathophysiological cascades induced by massive tissue destruction. Children and elderly people are especially endangered in being burnt. We present case of 73 years old woman with massive burn injury of >90% body surface.

**Key words:** burns, shock, mortality, critical care, acute respiratory distress syndrome.

**Case report:**

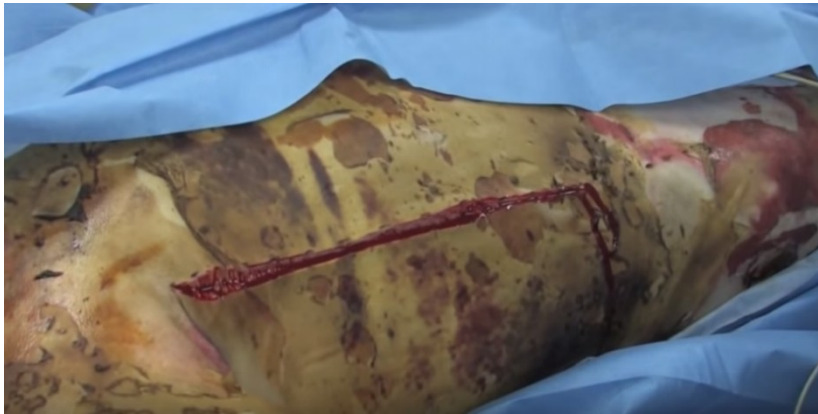A 73 years old woman was admitted to the Emergency Department with severe burn injuries caused by the explosion of the furnace. >90% of patient's body surface was covered in 2/3 degree burn injury. In the ED patient was monitored, patient's trachea was intubated and central venous catheter was placed in right internal jugular vein with use of ultrasound. Immediately, crystalloid fluids infusion started in accordance with Parkland formula. Patient was admitted to the Intensive Care Unit directly from the ED with acute respiratory failure and multiple organ failure. Patient was unconscious and there was impossibility to assess pupil reaction due to swelling. Patient's airway was also injured by inhalation of hot air and toxic gases. Acute respiratory distress syndrome aroused dynamically causing problems with mechanical ventilation. Plateau pressures eventually increased to 50cmH<sub>2</sub>O. Continuous infusion of noradrenaline and dobutamine was initiated because of cardiovascular distress. Hemodynamic monitoring was started to assess cardiac index and systemic vascular resistance. Continuous venovenous hemodiafiltration was implemented to replace renal function. Broad-spectrum antibiotic intravenous therapy was initiated. Tissue destruction caused elevation of myoglobin to >1000ng/ml (stand. 0.0-110 ng/ml). As a result of numerous surgical consultations bedside electrocoagulation escharotomy on the front and the side of the chest and abdomen was performed. A reduction in pressure in the airways to a value approximately 35 cmH<sub>2</sub>O and improvement in patient ventilation was achieved. Reduction in fraction of inspired oxygen to 0.5 was possible.



Pic. 1. Acute respiratory distress syndrome caused by burn inhalational injury.

Patient's condition started to deteriorate 12 hours after admission to the ICU. Low chest and lung compliance led to increase in inspiratory pressure. The circulatory system was unstable, thus continuous infusion of noradrenaline and dobutamine in increasing doses was obligatory. Metabolic acidosis with significant increase in blood lactates concentration remained resistant to treatment. Coagulation disorders and anemia required transfusion of blood products. Fasciotomy of four limbs was performed due to progressing compartment syndrome.

Unfortunately, despite multidisciplinary treatment patient's condition deteriorated significantly in the next 3 hours, leading eventually to decrease in blood pressure and cardiac arrest. Because of severe electrolyte, coagulation and metabolic disturbances resuscitation was ineffective.



Pic. 2. Escharotomy of III° burn injury

### **Discussion:**

Burn and fires account for more than 300,000 deaths each year worldwide. Despite these big numbers, the majority of burns are not fatal. Higher mortality rate is observed in children and elderly people especially in low-income regions[1]. Uncontrolled heating devices such as wood or coal furnaces are vulnerable to malfunction exposing users to severe burn injuries. Age is a direct contributor to increased burn mortality, and dealing with burn injury in the setting of multiple medical comorbidities presents a difficult challenge [2,3]. Severe burns are dangerous because of complicated pathophysiological dynamics. Electrolyte disturbances, coagulation disorders and abnormal fluid distribution are treatment challenges[3,4]. Metabolic acidosis treatment require efficient oxygen administration and distribution with gasometry-controlled mechanical ventilation. Impaired renal function have to be replaced with continuous hemodiafiltration. Tissue oedema can lead to compartment syndrome and eventually severe limb ischemia. Fasciotomy is most efficient treatment[6]. Chest wall

dismissed compliance caused by hardened necrotic tissue restrict effective ventilation. Thus, escharotomy of chest and abdomen wall is necessary to maintain ventilation and oxygen supply. After a burn lesion, Acute Respiratory Distress Syndrome (ARDS) may occur via direct lung injury due to inhaled smoke and fumes or mediated by the inflammatory response associated with the burn or its infectious complications[3,5]. ARDS is associated with higher mortality rate among burnt patients, especially in those requiring mechanical ventilation. Multidisciplinary treatment team including critical care specialists and surgeons is needed to heal patients with severe burn injuries. Rapid and continuous access to operation room, laboratory, critical care equipment and hemodynamic monitoring is crucial. Fast-track diagnostics and rapid treatment are needed to decrease mortality rate in massive burn patients[5,6].

#### **References:**

- [1]Peck M. D. Epidemiology of burns throughout the world. Part I: Distribution and risk factors. *Burns*, 2011 , 37 , 1087 – 1100.
- [2] Sharmila D, Maham R. Epidemiology of burn injuries: Highlighting cultural and socio-demographic aspects, *Intern Rev of Psych*, 2009 ,21:6, 505-511.
- [3] Gibran NS, Heimbach DM. Current status of burn wound pathophysiology. *Clin Plast Surg*. 2000 Jan;27(1) 11-22. PMID: 10665353.
- [4] Bonate P.L. Pathophysiology and Pharmacokinetics Following Burn Injury. *Clin Pharmacokinet*. 1990, 18: 118.
- [5] Silva L, Garcia L, Oliveira B, et al. Acute respiratory distress syndrome in burn patients: incidence and risk factor analysis. *Ann Burns Fire Disasters*. 2016;29(3):178-182.
- [6] Yowler C. J, Fratianne R. B. Current status of burn resuscitation. *Clin. Plast. Surg*. 27: 1, 2000