

The journal has had 7 points in Ministry of Science and Higher Education parametric evaluation. Part b item 1223 (26/01/2017).  
1223 Journal of Education, Health and Sport eISSN 2391-8306 7

© The Authors 2018;

This article is published with open access at Licensee Open Journal Systems of Kazimierz Wielki University in Bydgoszcz, Poland  
Open Access. This article is distributed under the terms of the Creative Commons Attribution Noncommercial License which permits any noncommercial use, distribution, and reproduction in any medium, provided the original author (s) and source are credited. This is an open access article licensed under the terms of the Creative Commons Attribution Non commercial license Share alike. (<http://creativecommons.org/licenses/by-nc-sa/4.0/>) which permits unrestricted, non commercial use, distribution and reproduction in any medium, provided the work is properly cited.

The authors declare that there is no conflict of interests regarding the publication of this paper  
Received: 03.12.2018. Revised: 10.12.2018. Accepted: 31.12.2018.

## Multidimensional assessment of a patient with perinatally diagnosed multiaxis - a case study

Agata Bloch<sup>1</sup>, Anna Złotnik<sup>2</sup>, Krystian Kałużny<sup>3</sup>, Magdalena Hagner-Derengowska<sup>4</sup>,  
Anna Kałużna<sup>3</sup>, Walery Zukow<sup>4</sup>

- 1) Nicolaus Copernicus University in Toruń, Ludwik Rydygier Collegium Medicum in Bydgoszcz
- 2) Pulmonary-Cardiological Specialistic Hospital in Torzym
- 3) Department of Rehabilitation, Faculty of Health Sciences, Nicolaus Copernicus University in Toruń, Ludwik Rydygier Collegium Medicum in Bydgoszcz
- 4) Department of Spatial Management and Tourism, Faculty of Earth Sciences, Nicolaus Copernicus University in Toruń

### Abstract

**Introduction:** For many years, congenital defects have been of particular interest to epidemiologists, neonatologists and paediatricians. Their incidence is still increasing, and the types are constantly being modified. Well-prepared prenatal tests allow for their early detection and if possible, these defects are operated during fetal life. Unfortunately, a significant proportion of cases do not qualify for these treatments. Then, a child with a defect or congenital malformation syndromes may undergo surgery only after birth. This often

results in a delay in neurophysiological development, and in an extreme case also in the mental state.

**The aim of this study** was to test a multidimensional assessment of a child who was diagnosed with numerous congenital malformations perinatally. After combining the elementary auxiliary diagnostics of the boy with pediatric norms, he tried to assess his general physical fitness by carrying out a Wrocław test of general physical fitness for pre-school children prepared by B. Sekita. We also analyzed selected practical tests for the integration of dynamic and postural reflexes developed by S. Masgutova and N. Akhmatova.

**Results:** The results of selected anthropometric measurements of the patient are definitely lower than those in parallel, despite normal birth parameters. The overall physical fitness of the boy is sufficient. The integration of selected dynamic and structural reflexes is correct. He was diagnosed with a problem of motor coordination in the area of body bias.

**Summation:** Immediate and comprehensive care from a team of specialists increases the chances of survival and optimal development of a child with serious congenital malformations. Early and systematic rehabilitation of the patient is a necessary condition to obtain effects in the convalescence process and its optimal neurophysiological development.

**Key words:** malformation syndrome, children's rehabilitation, physical fitness, small motor skills.

## **Introduction**

During the pre- and post-natal period, multi-stage development processes occur, which lead to continuous physiological and anatomical changes. Then they include transformations also in the psychomotor range. Due to the action of many pathological factors, various anomalies may occur. As a consequence, the child is often born with very serious, congenital malformations [<sup>1,2</sup>].

## **1 Reference**

Chochowska M., Zgorzalewicz-Stachowiak M., Sereda-Wiszowaty E., Wpływ wybranych czynników na skuteczność metody NDT-Bobath w usprawnianiu dzieci z mózgowym porażeniem dziecięcym. Fizjoterapia. 2008, Tom 16, nr 3, str.: 8-24

The definition of congenital malformation includes the intrauterine growth that arises during intrauterine life and the morphological pathology present at birth, internal or external. It is worth noting, however, that this term is used regardless of the etiology of the defect, its pathogenesis, but also the very moment of diagnosis. This also applies to morphological abnormalities at birth, even if they are not detectable during this period.

Congenital defects diagnosed in prenatal tests can still be corrected as far as possible by intrauterine surgery. However, there are often situations in which it is too late for any surgery to correct the pathology. Unfortunately, there are still cases of incorrect prenatal tests, which in turn leads to the failure to detect existing defects.

The aim of the work is a multidimensional assessment of a patient with perinatally diagnosed polyplantation, based on a case study. The assessment covered the somatic development of a five-year-old child. The analysis of his previous anthropometric measurements has been analyzed. Also, his general physical fitness and manual skills were tested. In the field of neurophysiological development, the integration of postural and dynamic reflexes of the boy was verified.

### **Case study**

The subject of research is a five-year-old boy. From medical records and family history it transpires that he was born in the 37th week of pregnancy. An autonomous spontaneous birth was diagnosed with polyhydramnios. After birth, the patient received 10 points on the Apgar scale. His body weight was: 2590 g., body length: 52 cm.

In the first diagnosis, the patient was diagnosed, among others, with coarctation of the aorta with hypoplasia, right subclavian stroke, loss of intraventricular septum and atrial septum, patent ductus arteriosus, congenital esophageal atresia with esophago-tracheal fistula. The deletion 22q11.2 was phenotypically diagnosed. In addition, the lack of third finger was found in the left upper limb and malformations of the ear pinna.

The patient underwent primary anastomosis of the esophagus in the first day of life, two weeks later correction of heart defect (hypoplastic aortic arch surgery and pulmonary artery banding) in extracorporeal circulation. The urological examination of a 1-day patient showed cryptorchidism, hydronephrosis and right megaureter widened along its entire length. The boy up to the third month is fed parenterally. He also had gastroesophageal reflux. After a genetic

consultation of almost a 3-month-old patient, no chromosome 22 deletion was detected, despite the patient's typical DiGeorge syndrome phenotype presence. The radiological examination revealed very broad cranial sutures, especially carbonus, defects of the bone of the left hand. V metacarpal bone, from which four bones of the fingers come out, from the third and fourth metacarpal bones - one phalange. The bones of the arms and forearms are correct.

In addition, the orthopedist stated the right hand falling, suggesting damage or paresis of the radial nerve. There were also weak movements of the fingers. Already at the age of 9 months, it was observed that the patient choses to use the left hand, despite the lack of the third finger. The boy was not diagnosed with neurological deficits.

Currently, the five-year-old is under the care of cardiology, metabolic, urological, neurological, endocrine and rehabilitation clinics. Despite the correction of basic anatomical defects, pharmacological treatment, metabolic disorders, the prognosis for development is uncertain. The patient requires constant, multi-specialized care, including systematic physical rehabilitation. The boy has a disability certificate from birth.

### **Research methods**

The research was carried out in the period from March to June 2018. The research sample included a five-year-old boy who was perinatally diagnosed with congenital malformations. The methods used were: individual case study and observational study.

The research tools used in the work were:

1. auxiliary diagnostics of a 5-year-old patient based on selected measurements,
2. Wrocław test of general physical fitness for pre-school children by B. Sekina,
3. practical tests of the integration of dynamic and postural reflexes developed by S. Masgutova and N. Akhmatova.

### **Results**

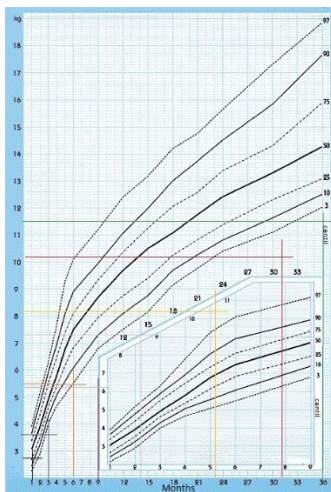
An auxological diagnostics of a 5-year-old patient was made based on selected measurements. Body weight measurements and height that were recorded in hospital epicrisis were used for verification. In addition, the range of motion in the individual joints of the patient was examined.

Table 1 shows the body mass and height of the patient in particular stages of life. The source of data were hospital epicrisis and the current measurement.

**Table 1:** Measurements of the patient in selected months of life.

<b>Age (months)</b>	<b>Body Mass (kg)</b>	<b>Height (cm)</b>
1	2,6	52
3	3,6	53
4	3,6	58
6	5,5	64
7	5,4	64
9	5,4	65
10	5,9	67
16	6,5	70
23	8,2	77
31	10,2	85
36	11,5	86
48	13,5	95
60	14,8	102

Figure 1 presents the birth weight centile grid of boys born between the 32nd and 37th week of pregnancy. Measured body weight was applied to it, immediately after birth and in: 3, 6, 9, 23, 31 and 36 months of age.



**Figure 1:** Weight percentile grid of boys born between 32nd and 37th week of pregnancy (selected patient measurements) [3]: Weight percentile grid of boys born between 32nd and 37th week of pregnancy (selected patient measurements) [4]

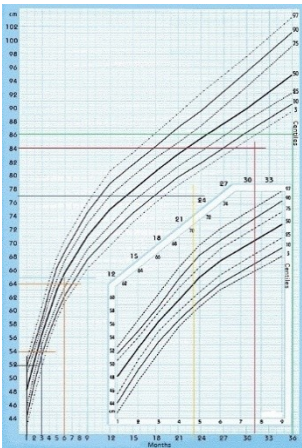
Analyzing the patient's body weight, the centile grid designed to assess premature babies born between the 32nd and 37th weeks of pregnancy shows that in addition to the first measurement performed after birth, none of the other results are above the 3rd percentile. The subject does not even reach the limit value. The condition of malnutrition in the first year could have occurred due to fistula in the area of the esophagus and inclusion of enteral nutrition, which was potentially unable to compensate for nutritional deficiencies in the period of the highest energy and mineral demand.

3

4  
str.: 15-44

Krawczyński M., Norma kliniczna w pediatrii,, Wyd. Ikar. Warszawa 2005,

Figure 2 is the centile grid of the body length of boys born between the 32nd and 37th week of pregnancy. Measured body weight was applied to it, immediately after birth and in: 3, 6, 9, 23, 31 and 36 months of age.



**Figure 1:** Centile grid of the body length of boys born between the 32nd and 37th weeks of pregnancy (selected patient measurements) [3]: Centile grid of the body length of boys born between the 32nd and 37th weeks of pregnancy (selected patient measurements) [3]

Figure 2 shows that the patient's height up to the sixth month was between the 25th and 50th percentile, which indicates that it falls within the upward norm. However, from the 9th month, the results of the subject are no longer between percentile curves. Perhaps hypoparathyroidism, and thus a low level of calcium in the body of the subject, led to the situation.

The next stage of the research was to collect measurements and assess the patient's body parameters. These were: limb lengths, ranges of movements in individual joints.

Before analyzing the above table, it should be noted that the researched boy, despite the lack of 3rd finger of the left hand, is actively using the hand. It is the dominant hand. On the right side, perinatal artery was diagnosed as an articular subclavian artery, which should vascularize the muscles of the right upper limb. The epicritum shows that it is 1/10 of capacity, which is why there was a slight muscular hypotension and hypotonus, which was examined in this work. However, in each of the measurements the right limb was 5 ° less than the left one, both in the case of flexion, extension, and abduction and adduction. Much greater disproportion occurred in the study of wrist mobility. The dorsal and palmar flexion of the left hand reaches almost the right range. However, this can not be said of the right hand. The patient made only 25 ° flexion and 20 ° dorsal flexion. As no bone anomalies have been found within this limb, it can be concluded that both extensors and flexors of the wrist have a reduced muscular tonus. A similar situation occurred also in the measurement of radial and ulnar deviation on the right side. Its ranges reach half of the standard mobility. Pronation and supination of the left forearm is within the normal range. On the right-hand side, however, the anomalies associated with the motion ranges are once again visible. Therefore, one should work, among others on the muscles: two-headed arm, forearm distractor and on the brachioradial arm in the case of supination. Regarding the pronation, there may be a disorder in the muscles: reversible oblong, reversible four-sided, brachial-radial, but also in the radial flexor of the wrist, the radial extender of the long wrist. These abnormalities could have originated in radial nerve damage, which was diagnosed in the ninth month of a patient's life. Also the rotations: external and internal of the shoulder joint in the horizontal plane in the right limb are disturbed. The patient reached a range of 50 ° and 25 °, which is just over half the range of normal mobility.

Another element of the research was to conduct a general physical fitness test in Wrocław, consisting of four tasks, to assess the level of motor fitness of the examined patient [5]. To assess the physical fitness, the recorded age of the child, which was 5 years, 2 months and 1 day, should be calculated. Then, functional tests were carried out in accordance with the recommendations and read from the tables, taking into account: age (5 years), sex (male), environment (rural), number of points assigned to a specific measurement size (test result).



**Table 2:** Patient's results obtained from the Wrocław physical fitness test [6].

Test	The best result obtained	Number of points awarded from individual trials	Evaluation of classification standards for individual trials
Agility test - 4x5m "swimming" with transferring the block	10,7 s	49	sufficient level of feature
Power test - long jump	87 cm	48	sufficient level of feature
Test of arm strength - throwing a medicine ball	162 cm	35	low, insufficient level of feature
Speed test - Short run at 20m. distance	6,7 s	29	low, insufficient level of feature
Total		161	sufficient level of physical fitness

Analyzing the results obtained from the Wrocław general fitness test for pre-school children by B. Sekina, it appears that the examined patient has a sufficient level of physical fitness. Obtaining a total of 161 points after completing four trials. Considering the patient's initial condition, the result is satisfactory. However, it can be noticed that the subject examined exceeded the barrier of a sufficient level of physical fitness by only one point.

Analyzing the individual tests, it can be seen that the patient obtained the smallest number of points for a short run on a distance of 20 meters, which was to verify his speed. An unsatisfactory grade for this level of feature may potentially result from lower patient height and possibly shorter lower limbs than other five-year-olds. However, it can not be officially confirmed. The cause could also be a slightly worse coordination of the patient, which was examined later in the work.

The shoulder test was also assessed at a low level. In this case the problem could be in the grip of the ball. Lower manual efficiency, reduced muscle strength in the right leg and lack of the third finger in the left hand did not allow for a secure grip, which resulted with lower score.

It was also decided to verify one reflex of three groups isolated by S. Masgutova and N. Akhmatova. The tests were done on the Robinson grip reflex from the group diagnosing laterality, the Bauer creeping reflex from the centering group and the Landau reflex belonging to the focus group.

The primitive **Robinson's gripping reflex** is to grip and hold the adult fingers firmly by the baby. This reflex develops large coordination, movement of hands, gripping and holding objects.

The subject, in a supine position, was given a task of taking the toy in one hand and keeping it over his head for 15 seconds. Another element of the study was to keep the toy with both hands for 30 seconds.



**Figure 3:** The patient performs a Robinson grasp reflex test - grip with both hands.

Referring to the photo above, a faulty execution can be seen. The object clearly surpasses the center line. It was observed that the subject was mainly operated with the left hand, while the right one was only placed on the toy without grasping it.

**Bauer's creeping reflex** occurs when the child, lying down on his stomach, with his head and torso in the middle line, raises his head for a few moments and performs creeping movements. However, if you put your hand under the child's feet, then the movements will become more active. This reflex affects the overall coordination of body movements, develops the connection between the upper and lower part of the body, between the limbs and the center of the body, hence this is the dimension of the centering. The task of the examined patient was, in the frontal position, to perform several creeping movements. After the previous demonstration, he had to overcome this distance about a meter away.

The observation of the whole exercise shows that the subject has trouble with coordination of movements. It was visible primarily during "pulling up" on the right upper limb. In addition, there were no movements in the neck. He did not perform spontaneous rotation of the head when switching sides of the limbs. This proves his general coordination problem, which may translate into problems with learning and concentration in the future. This is probably also due to reduced muscle strength within the upper limb.

## **Discussion**

A child born with congenital malformations is a kind of challenge for the entire team of specialists. Adequate to the nature of the pathology, the chosen doctors should diagnose the defect, often perform an immediate surgical procedure and recommend a long-term treatment process. The evolution of a newborn child occurs very progressively within each system, unfortunately, any surgical or pharmacological interference suppresses it to a greater or lesser degree. Hence the need for immediate assistance of specialized medical care, so that if a newborn is diagnosed, the newborn can react as quickly as possible and restore the physiological function of all systems [7, 8, 9].

7 Dryżek P., Politowska B., Moszura T., Mazurek-Kula A., Moll J. A., Sysa A., Rzadkie postaci przerwanego łuku aorty - trudności diagnostyczne. Opis dwóch przypadków. *Polski Przewodnik Kardiologiczny*. 2010, Tom 12, nr 4, str.: 325-328

8 Jurkowska L., Wpływ ruchu na prawidłową postawę dziecka. *Wychowanie Fizyczne i Zdrowotne*. 2006, Tom 53, nr 4, str.: 42-43

9 Kopczyńska-Sikorska Jadwiga, *Normy w pediatrii*. Wyd. Idea Sp. z o.o. Warszawa, 1999, str.: 19-53

The tests were carried out in a child diagnosed for multiovascular disease. One of the detected pathologies was congenital esophageal atresia with esophago-tracheal fistula. This defect belongs to a group that requires immediate surgery. It was done right after birth. The treatment area was wide and covered the upper digestive tract, therefore it was decided to establish a percutaneous endoscopic gastrostomy for the child, the so-called PEG. This allowed the infant to be fed the enteral route. From the interview with the mother, it was assessed that the lactation process was disturbed in her, so the boy was fed with modified milk.

The first problem that has been raised in this work is the disturbingly low parameters of anthropometric measurements in the patient under test, in relation to his peers. According to medical records up to the age of 3, apart from body weight and height, verified immediately after birth, the patient was placed even below the 3rd percentile. The sources of his severe underweight and short stature can be traced to diagnosed defects that indirectly affected such a condition. According to the literature on clinical nutrition, among others Gawęcki et al., oral feeding is the best way to feed. Then all ingredients are absorbed to the maximum extent. So if the patient from birth to the third month of life, i.e. in the period of increased growth, was fed the enteral route, then the upper gastrointestinal tract was omitted, did not develop actively due to the pathology that appeared in this area. In addition, during feeding by PEG, up to 1 year of age, the patient struggled with a strong gastro-oesophageal reflux. It could also be the reason for the appearance of malnutrition [<sup>10</sup>, <sup>11</sup>, <sup>12</sup>].

Another argument that confirms all dietary reports is the fact that breast milk is the best and most balanced food, rich in energy, amino acids, but very importantly containing colostrum - a natural substance containing immune bodies. The examined patient was fed with modified milk, applied directly to the stomach. One can only assume that this is one of the reasons for the patient's deep underweight. In addition, the number of surgical procedures and permanent

10 Dryżek P., Politowska B., Moszura T., Mazurek-Kula A., Moll J. A., Sysa A., Rzadkie postaci przerwanego łuku aorty - trudności diagnostyczne. Opis dwóch przypadków. *Polski Przewodnik Kardiologiczny*. 2010, Tom 12, nr 4, str.: 325-328

11 Czerwionka-Szaflarska M., Adamska I., Żywnienie a prawidłowy rozwój dziecka. *Klinika Pediatria*. 2010, Tom 18, nr 2, str.: 209-212

12 Krawczyński M., *Norma kliniczna w pediatrii*, Warszawa 2005, str.: 15-44

pharmacological treatment contributed to the increase in catabolic metabolism in the body [13, 14, 15].

The research analysis including anthropometric measurements allows to conclude that the patient is significantly shorter than his peers. Low growth was not genetically conditioned, because the parents are in the upper limit of body height, according to age. The patient's growth hormone also reached the correct level. The reasons should be located in the deficiency of calcium, which was marked in each of the analyzed medical epicrisis. Hypocalcaemia caused by hypoparathyroidism was diagnosed in the first two weeks of life. The boy received calcium-enriched medicines from that moment. In addition, the occurrence of left limb myoclonus in the second month of life, had its etiology in calcium deficiency. The indirect symptoms of hypocalcaemia, which were visible in stages, were inhomogeneous calcification of the vertebrae and lack of bone ossification of the ilium heads at the age of 5 and 8 months. All these symptoms could potentially relate to a slower growth of the boy [16, 17, 18, 19, 20].

Another problem that was verified was the integration of postural and dynamic reflexes in the examined patient. It was decided to choose a tool, the authors of which are S. Masgutova and N. Akhmatova, because of the innovative program that tests reflexes and their impact on the body. The vast majority of neonatologists, pediatricians and physiotherapists assess the child's neurophysiological development according to the formation and fading of reflexes. However, the above-mentioned therapists are of the opinion that stress and nervous system diseases automatically activate the body's defensive reactions. They often evoke impulsive behaviors

13 Dryżek P., Politowska B., Moszura T., Mazurek-Kula A., Moll J. A., Sysa A., Rzadkie postaci przerwanego łuku aorty - trudności diagnostyczne. Opis dwóch przypadków. *Polski Przewodnik Kardiologiczny*. 2010, Tom 12, nr 4, str.: 325-328

14 Kułakowska Z., Ocena neurologiczna dzieci wypisywanych z oddziałów neonatologicznych. *Klinika Pediatryczna*. 2007, vol. 15, nr 1, str.: 24-32

15 Sielużycka A., Metody oceny rozwoju fizycznego u dzieci i młodzieży. *Klinika Pediatryczna*. 2010, Tom 18, nr 2, str.: 204-208

16 Demczyszak I. Fizjoterapia w chorobach układu sercowo-naczyniowego. *Podręcznik dla studentów licencjatów wydziału fizjoterapii*. Górnicki Wydawnictwo Medyczne, Wrocław, 2006, str.: 24-44

17 Grzegorzewska J., Juskowa J., Korabiewska I., Kłoda M., Wady postawy dzieci i młodzieży. *Wychowanie Fizyczne i Zdrowotne*. 2007, vol. 54, nr 4, str.: 9-19

18 Kleinrok A., Szeremeta E., Czochna W., Fizjoterapia w kardiologii. Skrypt dla studentów. Wyższa Szkoła Zarządzania i Administracji w Zamościu, Zamość, 2008, str.: 14-34

19 Krawczyński M., Krawczyński M. R., Zaburzenia rozwojowe: terminologia i klasyfikacja, zakres normy rozwojowej. *Pediatrics Polska* 2010, Vol. 85, nr 1, str.: 5-9

20 Tomczyński J., Werner B., Wasiak K., Fizjoterapia niemowląt ze wzmożonym napięciem mięśniowym. *Kardioprofilaktyka*. 2009, Tom 7, nr 6, str.: 395-400

and primitive reflex reactions, leading to regression of internal control processes and higher functions at the level of the psyche [21, 22, 23, 24, 25].

Hence, by directing work to inhibiting the persistent reflex, it traditionally "fights" with defense mechanisms and mechanisms of survival. Masgutova's concept brings the idea of "talking" with pathomechanisms in a positive way, without activating their defense programs. One does not "fight" with pathomechanisms directly, but offers the genetically programmed patterns of reflexes, which are called normal, to the brain-body system. The authors of this innovative program of reflexive assumptions, largely deviate from assessing the development of the child, in terms of the appearance and expiration of the reflex, as it usually does in the generally accepted diagnosis of the patient [26, 27, 28].

The last problem that was decided to be discussed is the diagnosis of the patient being examined itself. In the perinatal diagnosis the DiGeorge syndrome is found in the boy. Most of the congenital anomalies were diagnosed at that time, which usually appear in a child with a chromosome 22 deletion. To confirm this diagnosis of the DiGeorge syndrome, genetic tests were performed. In spite of the "book" characteristic symptoms, it turned out that deletion of

21 Masgutowa S., Akhmatova N., Integracja odruchów dynamicznych i posturalnych z układem ruchowym całego ciała (podejście kinezylogii edukacyjnej) Międzynarodowy Instytut Neurokinezylogii rozwoju ruchowego i integracji odruchów, Warszawa 2005, str.:9-61

22 Masgutowa S., Regner A., Rozwój mowy dziecka w świetle integracji sensomotorycznej Źródło: - Wrocław, Wydaw. Continuo 2009, str.: 163-168

23 MATERIAŁY z: Międzynarodowej Konferencji pt. Nowoczesne metody stymulacji rozwoju ruchowego i mowy. Krynica Zdrój. 04-05.06. 2005, Dzierma I. Twórcza edukacja przez ruch : wykorzystanie kinezylogii edukacyjnej w przedszkolu 2005, str.: 137-153

24 MATERIAŁY z: Międzynarodowej Konferencji pt. Nowoczesne metody stymulacji rozwoju ruchowego i mowy. Krynica Zdrój. 04-05.06. 2005, Masgutowa S., Sadowska L. Zastosowanie kinezylogii edukacyjnej u dzieci z trudnościami w nauce w świetle rozwoju wczesnych dynamizmów ruchowych. 2005, str.: 37-50

25 MATERIAŁY z: Międzynarodowej Konferencji Naukowej pt. Aktywność ruchowa osób niepełnosprawnych. Wrocław. 02-03.12. 2006, Różański P., Zastosowanie ćwiczeń terapeutycznych w aspekcie problematyki usprawniania korekcyjnego w wodzie, Aktywność ruchowa osób niepełnosprawnych. 2006, Tom 2, Wrocław, str.: 49-56

26 Gajewska E., Narzędzia diagnostyczne do oceny wczesnego rozwoju motorycznego stosowane w fizjoterapii dziecięcej., Neurologia Dziecięca. 2011, Vol. 20, nr 40, str.: 53-59

27 Kleinrok A., Szeremeta E., Czochra W., Fizjoterapia w kardiologii. Skrypt dla studentów. Wyższa Szkoła Zarządzania i Administracji w Zamościu, Zamość, 2008, str.: 14-34

28 MATERIAŁY z: Międzynarodowej Konferencji pt. Nowoczesne metody stymulacji rozwoju ruchowego i mowy. Krynica Zdrój. 04-05.06. 2005, Kowal J., Masgutowa S., Terapia Taktylna NeuroKinezylogiczna\*\*TM według dr str.: Masgutowej. 2005, str.: 96-107

chromosome 22 was not found with the patient. The patient's phenotype is DiGeorge syndrome, and genetics denies it. This is a very unusual situation in which the occurrence of such numerous defects has not yet been classified [29, 30, 31, 32, 33].

### **Summation**

The results obtained in the tests showed a therapeutic effect in reducing pain associated with plantar aponeurosis, nonetheless the comparison of both physical methods showed a statistically significant difference between the groups studied. The improvement with a greater severity was noted in group II, treated by sonotherapy, as the form of ultrasounds.

29                   Drewno G., Ferenc T., Genetyka medyczna. Podręcznik dla studentów, Wrocław 2011, str.: 496-499

30                   Kaźmierczak P., Moll J. A., Moll J. J., Operacja koarktacji aorty u noworodka z masą ciała 1200 g. Opis przypadku. Kardiologia i Torakochirurgia Polska. 2010, Tom 7, nr 1, str.: 27-36

31                   Kessler M., Techniki terapeutyczne w fizjoterapii neurologicznej. Redakcja wydania I polskiego Saulicz E., Wrocław 2007, str.: 52-95

32                   Latos-Bieleńska A., Materna-Kiryluk A., Badura-Stronka M., Wiśniewska K., Wiśniewska M., Mejnartowicz J., Jamsheer A., Chrzanowska K., Krajewska-Walasek M., Polski Rejestr Wrodzonych Wad Rozwojowych i EUROCAT w identyfikacji rzadkich chorób. Ginekologia praktyczna. 2009, Tom 17, nr 3, str.: 49-60

33                   Piórkowska K., Gładkowski J., Rehabilitacja protetyczna pacjentów z wadami wrodzonymi. Protetyka Stomatologiczna 2008, Tom 58, nr 1, str.: 22-28

## References

1. Chochowska M., Zgorzalewicz-Stachowiak M., Sereda-Wiszowaty E., Wpływ wybranych czynników na skuteczność metody NDT-Bobath w usprawnianiu dzieci z mózgowym porażeniem dziecięcym. *Fizjoterapia*. 2008, Tom 16, nr 3, str.: 8-24
2. Dryżek P., Politowska B., Moszura T., Mazurek-Kula A., Moll J. A., Sysa A., Rzadkie postaci przerwanego łuku aorty - trudności diagnostyczne. Opis dwóch przypadków. *Polski Przewodnik Kardiologiczny*. 2010, Tom 12, nr 4, str.: 325-328
3. Krawczyński M., *Norma kliniczna w pediatrii*, Wyd. Ikar. Warszawa 2005, str.: 15-44
4. Talaga J., *Sprawność fizyczna ogólna. Testy*. Wyd. Zysk i S-ka, Poznań 2004, str.: 64 - 72
5. Ibid.
6. Dryżek P., Politowska B., Moszura T., Mazurek-Kula A., Moll J. A., Sysa A., Rzadkie postaci przerwanego łuku aorty - trudności diagnostyczne. Opis dwóch przypadków. *Polski Przewodnik Kardiologiczny*. 2010, Tom 12, nr 4, str.: 325-328
7. Jurkowska L., Wpływ ruchu na prawidłową postawę dziecka. *Wychowanie Fizyczne i Zdrowotne*. 2006, Tom 53, nr 4, str.: 42-43
8. Kopczyńska-Sikorska Jadwiga, *Normy w pediatrii*. Wyd. Idea Sp. z o.o. Warszawa, 1999, str.; 19-53
9. Dryżek P., Politowska B., Moszura T., Mazurek-Kula A., Moll J. A., Sysa A., Rzadkie postaci przerwanego łuku aorty - trudności diagnostyczne. Opis dwóch przypadków. *Polski Przewodnik Kardiologiczny*. 2010, Tom 12, nr 4, str.: 325-328
10. Czerwionka-Szaflarska M., Adamska I., Żywnienie a prawidłowy rozwój dziecka. *Klinika Pediatria*. 2010, Tom 18, nr 2, str.: 209-212
11. Krawczyński M., *Norma kliniczna w pediatrii*, Warszawa 2005, str.: 15-44
12. Dryżek P., Politowska B., Moszura T., Mazurek-Kula A., Moll J. A., Sysa A., Rzadkie postaci przerwanego łuku aorty - trudności diagnostyczne. Opis dwóch przypadków. *Polski Przewodnik Kardiologiczny*. 2010, Tom 12, nr 4, str.: 325-328
13. Kułakowska Z., Ocena neurologiczna dzieci wypisywanych z oddziałów neonatologicznych. *Klinika Pediatria*. 2007, vol. 15, nr 1, str.: 24-32
14. Sielużycka A., *Metody oceny rozwoju fizycznego u dzieci i młodzieży*. *Klinika Pediatria*. 2010, Tom 18, nr 2, str.: 204-208
15. Demczyszak I. *Fizjoterapia w chorobach układu sercowo-naczyniowego*. Podręcznik dla studentów licencjatów wydziału fizjoterapii. Górnicki Wydawnictwo Medyczne, Wrocław, 2006, str.: 24-44



16. Grzegorzewska J., Juskowa J., Korabiewska I., Kłoda M., Wady postawy dzieci i młodzieży. Wychowanie Fizyczne i Zdrowotne. 2007, vol. 54, nr 4, str.: 9-19
17. Kleinrok A., Szeremeta E., Czochra W., Fizjoterapia w kardiologii. Skrypt dla studentów. Wyższa Szkoła Zarządzania i Administracji w Zamościu, Zamość, 2008, str.: 14-34
18. Krawczyński M., Krawczyński M. R., Zaburzenia rozwojowe: terminologia i klasyfikacja, zakres normy rozwojowej. *Pediatrics Polska* 2010, Vol. 85, nr 1, str.: 5-9
19. Tomczyński J., Werner B., Wasiak K., Fizjoterapia niemowląt ze wzmożonym napięciem mięśniowym. *Kardioprofilaktyka*. 2009, Tom 7, nr 6, str.: 395-400
20. Masgutowa S., Akhmatova N., Integracja odruchów dynamicznych i posturalnych z układem ruchowym całego ciała (podejście kinezylogii edukacyjnej) Międzynarodowy Instytut Neurokinezylogii rozwoju ruchowego i integracji odruchów, Warszawa 2005, str.:9-61
21. Masgutowa S., Regner A., Rozwój mowy dziecka w świetle integracji sensomotorycznej Źródło: - Wrocław, Wydaw. Continuo 2009, str.: 163-168
22. MATERIAŁY z: Międzynarodowej Konferencji pt. Nowoczesne metody stymulacji rozwoju ruchowego i mowy. Krynica Zdrój. 04-05.06. 2005, Dzierma I. Twórcza edukacja przez ruch : wykorzystanie kinezylogii edukacyjnej w przedszkolu 2005, str.: 137-153
23. MATERIAŁY z: Międzynarodowej Konferencji pt. Nowoczesne metody stymulacji rozwoju ruchowego i mowy. Krynica Zdrój. 04-05.06. 2005, Masgutowa S., Sadowska L. Zastosowanie kinezylogii edukacyjnej u dzieci z trudnościami w nauce w świetle rozwoju wczesnych dynamizmów ruchowych. 2005, str.: 37-50
24. MATERIAŁY z: Międzynarodowej Konferencji Naukowej pt. Aktywność ruchowa osób niepełnosprawnych. Wrocław. 02-03.12. 2006, Różański P., Zastosowanie ćwiczeń terapeutycznych w aspekcie problematyki usprawniania korekcyjnego w wodzie, Aktywność ruchowa osób niepełnosprawnych. 2006, Tom 2, Wrocław, str.: 49-56
25. Gajewska E., Narzędzia diagnostyczne do oceny wczesnego rozwoju motorycznego stosowane w fizjoterapii dziecięcej., *Neurologia Dziecięca*. 2011, Vol. 20, nr 40, str.: 53-59
26. Kleinrok A., Szeremeta E., Czochra W., Fizjoterapia w kardiologii. Skrypt dla studentów. Wyższa Szkoła Zarządzania i Administracji w Zamościu, Zamość, 2008, str.: 14-34
27. MATERIAŁY z: Międzynarodowej Konferencji pt. Nowoczesne metody stymulacji rozwoju ruchowego i mowy. Krynica Zdrój. 04-05.06. 2005, Kowal J., Masgutowa S., Terapia Taktylna NeuroKinezylogiczna\*\*TM według dr str.: Masgutowej. 2005, str.: 96-107

28. Drewa G., Ferenc T., Genetyka medyczna. Podręcznik dla studentów, Wrocław 2011, str.: 496-499
29. Kaźmierczak P., Moll J. A., Moll J. J., Operacja koarktacji aorty u noworodka z masą ciała 1200 g. Opis przypadku. Kardiochirurgia i Torakochirurgia Polska. 2010, Tom 7, nr 1, str.: 27-36
30. Kessler M., Techniki terapeutyczne w fizjoterapii neurologicznej. Redakcja wydania I polskiego Saulicz E., Wrocław 2007, str.: 52-95
31. Latos-Bieleńska A., Materna-Kiryluk A., Badura-Stronka M., Wiśniewska K., Wiśniewska M., Mejnartowicz J., Jamsheer A., Chrzanowska K., Krajewska-Walasek M., Polski Rejestr Wrodzonych Wad Rozwojowych i EUROCAT w identyfikacji rzadkich chorób. Ginekologia praktyczna. 2009, Tom 17, nr 3, str.: 49-60
32. Piórkowska K., Gładkowski J., Rehabilitacja protetyczna pacjentów z wadami wrodzonymi. Protetyka Stomatologiczna 2008, Tom 58, nr 1, str.: 22-28