

Wróbel Grzegorz. Wormian bones - a case report of post-mortem examination. *Journal of Education, Health and Sport*. 2018;8(6):412-417. eISSN 2391-8306. DOI <http://dx.doi.org/10.5281/zenodo.1442512>  
<http://ojs.ukw.edu.pl/index.php/johs/article/view/6144>

The journal has had 7 points in Ministry of Science and Higher Education parametric evaluation. Part B item 1223 (26/01/2017).

1223 Journal of Education, Health and Sport eISSN 2391-8306 7

© The Authors 2018;

This article is published with open access at Licensee Open Journal Systems of Kazimierz Wielki University in Bydgoszcz, Poland

Open Access. This article is distributed under the terms of the Creative Commons Attribution Noncommercial License which permits any noncommercial use, distribution, and reproduction in any medium, provided the original author (s) and source are credited. This is an open access article licensed under the terms of the Creative Commons Attribution Non commercial license Share alike. (<http://creativecommons.org/licenses/by-nc-sa/4.0/>) which permits unrestricted, non commercial use, distribution and reproduction in any medium, provided the work is properly cited.

The authors declare that there is no conflict of interests regarding the publication of this paper.

Received: 01.06.2018. Revised: 15.06.2018. Accepted: 30.06.2018.

## **Wormian bones - a case report of post-mortem examination**

**Grzegorz Wróbel<sup>1</sup>**

<sup>1</sup> Department of Anatomy, Faculty of Medicine and Health Sciences, Jan Kochanowski University, Kielce, Poland

Correspondence: Department of Anatomy, Faculty of Medicine and Health Sciences, Jan Kochanowski University, Al. IX Wieków Kielc 19A, 25-317 Kielce, Poland.

Tel: 413496965. E-mail: [grzegorz.wrobel@ujk.edu.pl](mailto:grzegorz.wrobel@ujk.edu.pl)

## **Abstract**

Skull bones provide attachment to numerous facial expressions. Sometimes, as an anatomical variant, small irregular bones (ossicles) appear in the area already present and located at the seams of the cranial skull. These asymmetrical bones are also called sutural bones, which usually occur along the sutures. The observational study concerns bone material located in the Department of Anatomy of the Jan Kochanowski University in Kielce. During the analysis of human skulls, the occurrence of additional bones within the cranial sutures was observed. Morphologically, these bones have different shapes (oval, oblong, round, quadrilateral, polygonal, triangular) and sizes. Wormian bones are more common in the human skull than previously reported, therefore doctors or radiologists should know about this anatomical variant not to confuse it with the clinical aspect during surgery or imaging the skull.

**Keywords:** skull, sutural bones, osteology

## **1. Introduction**

Skull is the bone of the human skeleton, which has a very important function because it protects the brain. In anatomy, the skull generally consists of 28 separate bones and most of them are paired. Skull bones provide attachment to numerous facial expressions. Sometimes, as an anatomical variant, small irregular bones (ossicles) appear in the area already present and located at the seams of the cranial skull [1-3]. The name "wormian bones" (WB) comes from Olaus Worm, Danish anatomist who described them in a letter to Thomas Bartholin in 1643 [4]. These asymmetrical bones are also called sutural bones, which usually occur along the sutures. They may be present in various anatomical points on the skull, such as bregma, pterion, asterion or lambda, but most often appear on the lambdoid suture [5]. The occurrence of Wormian bones is recorded in normal as well as abnormal cases. They can be found as normal variants and appear to be genetically determined in some populations. One of the factors that can affect the presence of additional bones is the adaptation of the skull to expand, the bone number of the Wormian increases with the capacity of the skull, regardless of the cause of the enlargement [6-8].

## 2. Case presentation

The observational study concerns bone material located in the Anatomy Department of the Jan Kochanowski University in Kielce. During the analysis of human skulls, the occurrence of additional bones within the cranial sutures was observed. The first photo shows the presence of WB in a non-regular shape located near the sagittal suture and lambdoid suture (Figure 1). The second photograph shows WB located near the following sutures: lambdoid, occipitomastoid and parietomastoid (Figure 2). The third photograph shows a large WB located near the following sutures: lambdoid and occipitomastoid (Figure 3).




Figure 1. Posterior view of the skull vault with the presence of the sutural bone. WB – Wormian bone, SS – sagittal suture, LS – lambdoid suture, OB – occipital bone, LPB/RPB – left/right parietal bone (photographed by Grzegorz Wróbel)

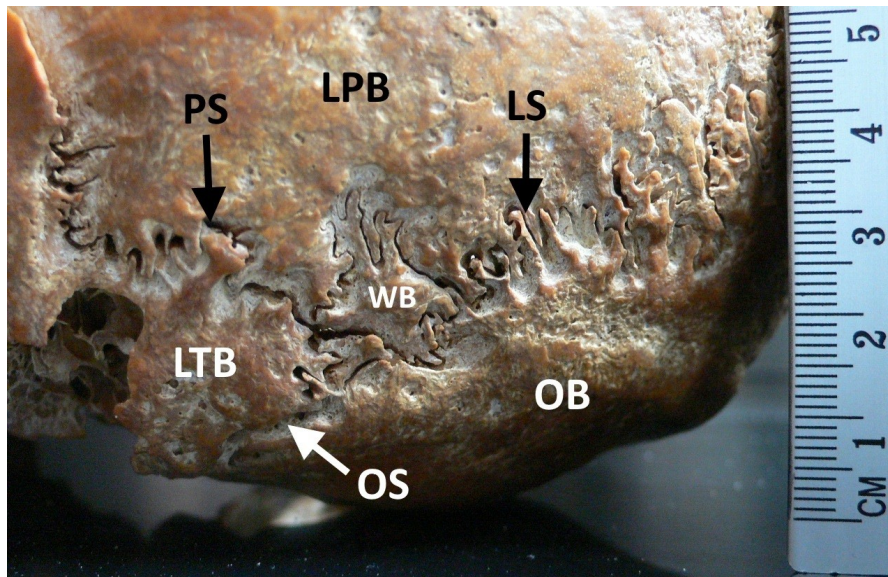


Figure 2. Side view of the skull with the presence of the sutural bone. WB – Wormian bone, PS – parietomastoid suture, LS – lambdoid suture, OS – occipitmastoid suture, OB – occipital bone, LPB – left parietal bone, LTB – left temporal bone (photographed by Grzegorz Wróbel)

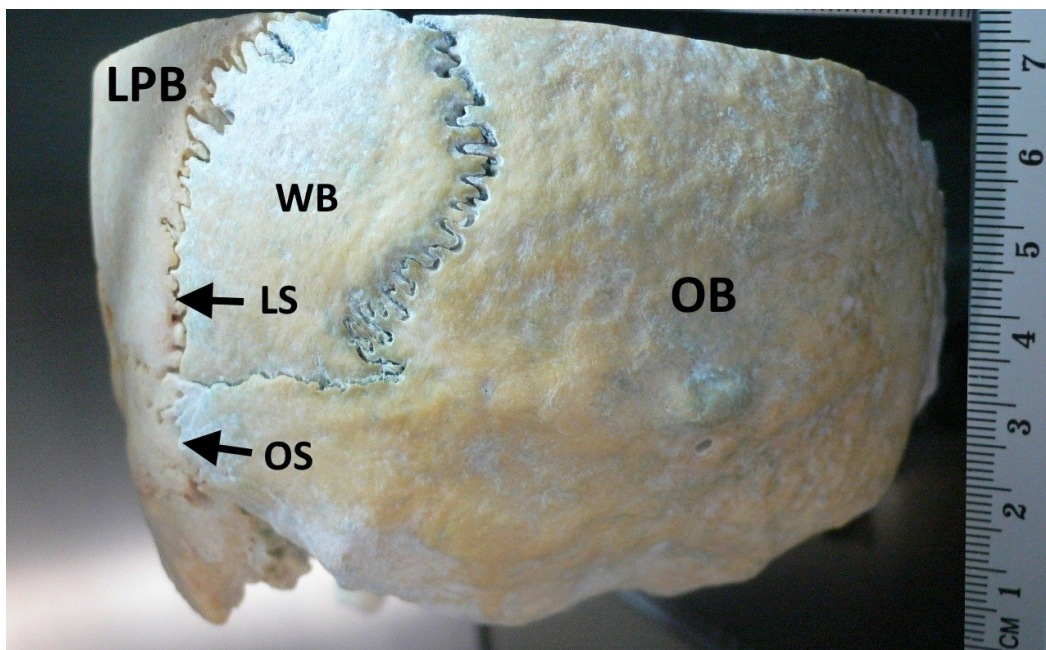


Figure 3. Posterior view of the skull with the presence of the sutural bone. WB – Wormian bone, LS – lambdoid suture, OS – occipitmastoid suture, OB – occipital bone, LPB – left parietal bone (photographed by Grzegorz Wróbel)

### 3. Discussion

WB connects with the surrounding bones with sutures and their recesses are more complex outside than on the inner surface of the skull. Morphologically, these bones have different shapes (oval, oblong, round, quadrilateral, polygonal, triangular) and sizes that may have a diameter of less than 1 mm to 5 x 9 cm [8]. There is a moderate degree of sexual dimorphism among the bone wormian with respect to overall frequency, number and location [9]. The prevalence of wormian bones was reported by various authors. For example, Patil and Sheelavant [10], analyzing 180 dry human skulls, showed that the total incidence of bone wormian was more in women (64.80%) than in male skulls (40.20%). Wb occurred more often at lambdoid suture (60%). WB are more common in the human skull than previously reported, therefore doctors or radiologists should know about this anatomical variant not to confuse it with the clinical aspect during surgery or imaging the skull [11].

### References

1. Nayak SB. Multiple Wormian bones at the lambdoid suture in an Indian skull. *Neuroanatomy* 2008; 7:52–53.
2. Bellary SS, Steinberg A, Mirzayan N, Shirak M, Tubbs RS, Cohen-Gadol AA, Loukas M. Wormian bones: a review. *Clin Anat.* 2013 Nov;26(8):922-7. doi: 10.1002/ca.22262.
3. Vasanthi A, Adinarayana KPS, Pujitha S. Morphological study of wormian bones in cadaver skulls. *Journal of Evidence based Medicine and Healthcare.* 2015; 2(12): 1757-1762
4. Jeanty P, Silva SR, Turner C. Prenatal diagnosis of wormian bones. *J Ultrasound Med* 2000; 19:863–869.
5. Murlimanju BV, Prabhu LV, Ashraf CM, Kumar CG, Rai R and Maheshwari C. Morphological and topographical study of Wormian bones in cadaver dry skulls. *J. Morphol. Sci.* 2011; 28(3): 176-179.
6. Hernandez FG, Echeverria GM. Frequency of skull bones with lambdoid in artificial deformation in Northern Chile. *Int J Morphol.* 2009;27:933-8.
7. Raja SK, Siva NR, Sundara S. Incidence of sutural bones at pterion south Indian dried skulls. *Int J Anat Res.* 2016;4:2099-101.
8. Reveron RR. Anatomical Classification of Sutural Bones. *MOJ Anat&Physiol.* 2017;3:101. Khan AA, Asari MA, Hassan A. Unusual presence of wormian (sutural) bones in human skulls. *Folia Morphol.* 2011; 70(4): 291-294.

9. Khan AA, Asari MA, Hassan A. Unusual presence of wormian (sutural) bones in human skulls. *Folia Morphol.* 2011; 70(4): 291-294.
10. Patil M, Sheelavant S. Sexual Dimorphism among the Wormian Bones In Adult Human Skulls. *J Indian Acad Forensic Med.* 2012; 34(2):124-127.
11. Kaplan SB, Kemp SS, OH Ks. Radiographic manifestations of congenital anomalies of the skull. *Radiol Clin North Am* 1991; 29:195-218.