

Chromińska Karolina, Bąk Tomasz,
Wojciechowicz Jolanta, Gawęda Anna,
Tomaszewski Tomasz. Orbital trauma with a large
wooden foreign body: a case report. *Journal of Education,
Health and Sport*. 2018;8(7):629-632. eISSN 2391-8306.
DOI <http://dx.doi.org/10.5281/zenodo.1436052>
<http://ojs.ukw.edu.pl/index.php/johs/article/view/6121>

The journal has had 7 points in Ministry of Science and Higher Education parametric
evaluation. Part B item 1223 (26/01/2017).
1223 Journal of Education, Health and Sport eISSN 2391-8306 7

© The Authors 2018;

This article is published with open access at Licensee Open Journal Systems of Kazimierz
Wielki University in Bydgoszcz, Poland

Open Access. This article is distributed under the terms of the Creative Commons
Attribution Noncommercial License which permits any noncommercial use, distribution,
and reproduction in any medium, provided the original author (s) and source are credited.
This is an open access article licensed under the terms of the Creative Commons Attribution
Non commercial license Share alike.

(<http://creativecommons.org/licenses/by-nc-sa/4.0/>) which permits unrestricted, non
commercial use, distribution and reproduction in any medium, provided the work is
properly cited.

The authors declare that there is no conflict of interests regarding the publication of this
paper.

Received: 14.07.2018. Revised: 20.07.2018. Accepted: 30.07.2018.

Orbital trauma with a large wooden foreign body: a case report

Karolina Chromińska¹, Tomasz Bąk²,
Jolanta Wojciechowicz², Anna Gawęda²,
Tomasz Tomaszewski²

¹ Student's Research Circle, Chair and Clinic of
Maxillofacial Surgery, Medical University of
Lublin

² Chair and Clinic of Maxillofacial Surgery,
Medical University of Lublin

Abstract

Introduction: Injuries caused by a foreign
bodies in the craniofacial region constitute
a significant percentage of accidents during
the work. The most serious problem is
to determine the exact location and extent
of damage caused by a foreign body. The aim

of work is to present a scheme of conduct
in case of a foreign body inside the eye socket.

Materials and methods: Describes a case
of a patient with an injury caused by a wooden
foreign body. The circumstances of occurrence,
ophthalmic and surgical actions taken in order
to remove it were included. A lot of attention has
been paid to prevention of intraocular
infections.

Results: Patient did not find both post-traumatic
and postoperative ophthalmic nerve injuries.

Summary: The most important for healing
process is exact removal of the foreign body
and prophylaxis of infections. In addition
to treatment, it is important to educate the
patient in the prevention of this type of injury.

KEY WORDS: wooden foreign body, orbital
trauma, orbital injury

Introduction:

Foreign objects inside the eye socket are
a big diagnostic problem for both
ophthalmologists and maxillofacial surgeons.
The type of foreign bodies can be divided due
to the material they are made of: metallic, e.g.
lead, non-metallic, e.g. glass, and organic, e.g.
wood. Unless the metallic and non-metallic
foreign bodies are well tolerated, the organic
ones cause an intense inflammatory reaction,
which is why they must always be removed [1].
Often, in cases where the nerve and eyeball are
not damaged, foreign body may remain
a symptomatic in the orbit for a long time [2,3].
In other cases, foreign body may cause intra
orbital hematoma.

The presence of foreign bodies inside the eye
socket is usually associated with accidents
at work. Due to the performance of manual
work, men are more likely to suffer injuries
than women [1]. The reason is lack proper
preparation of employees to operate machines,
not using basic protective tools in the form
of glasses or visors, routine activities and non-
compliance with health and safety rules.
Unfortunately, there is still a high percentage
of accidents in people under the influence
of alcohol. The analyzes show some
dependencies as to the frequency of accidents
and the age of employees [1]. Younger people
are more likely to suffer from injuries due to

little work experience, poor knowledge of machine operation and youthful bravado. Injuries in the eyes are a serious social and economic problem, because they are experienced by young and healthy men, who often lose sight due to an accident [4].

Case report:

On 09/10/2015, a 48-year-old man, while working on woodworking, suffered an injury without losing consciousness. A fragment of branch drove into the right eye socket and damaged the lower eyelid. The patient came to the nearest center (local casualty department) where head CT and basic blood tests were performed.

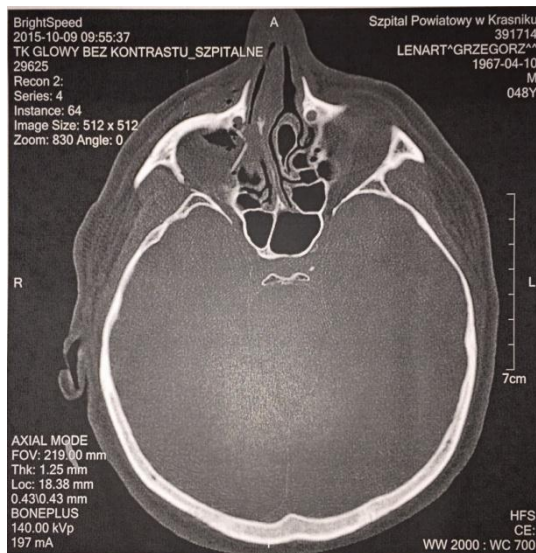


Fig. 1 Computed Tomography of the head without contrast

In CT (Figure 1), a multi-fracture of right orbital bottom wall of the right orbital sinus was found. A foreign body in right eye socket. Blood in bay, curvature of the nasal septum in the right direction, rejection of right and subcutaneous socket of the surrounding soft tissues. Parameters of morphology, biochemistry and coagulation were normal.

Patient was transported to the reference hospital-Clinic of Maxillofacial surgery in Lublin.

In order to exclude eye injury and supply the lower eyelid wound, he was referred for consultation to the Ophthalmology Clinic. On the same day, the procedure of reconstruction of tear ducts and stitching of lower eyelid of the right eye were performed under

the general anesthesia. Immediately before the procedure, Oftaquix drops were given to the eye operated as part of perioperative prophylaxis. After the procedure, gentamicin was subconjunctival, and Betadina, Oftaquix and Dexamytrex were given to the eye. Ophthalmologic consultations were recommended after surgical orbital surgery and anti-bacterial treatment in the form of eye drops with ofloxacin.

Further treatment was carried out in the Maxillofacial Surgery Clinic. On 12.10.2015 an operation was performed to remove the foreign body (wood) from right orbital sinus, the side wall of nose and right maxillary sinus. Operation was performed under the general anesthesia.

From the intra oral incision around 12-17 tooth area, the muco-periosteal flap was cut. In the front wall of right maxillary sinus, a fragment of foreign body was revealed - the wood wedged into the nasal wall of the right maxillary sinus.

After removing the fragment of nasal wall of the bay and cutting the wood, its part was removed. In order to remove the second part to the foreign body, the ligature (fig. 2) was screwed in with help of which it was possible to extract all the rest of the wood. Patient abolished the procedure well.

For antimicrobial prophylaxis, he received intravenous antibiotic therapy with cefazolin and metronidazole.

Postoperative period was without complications. Patient responded well to painkillers and was discharged from the hospital four days after the surgery with recommendations for maintaining oral hygiene.

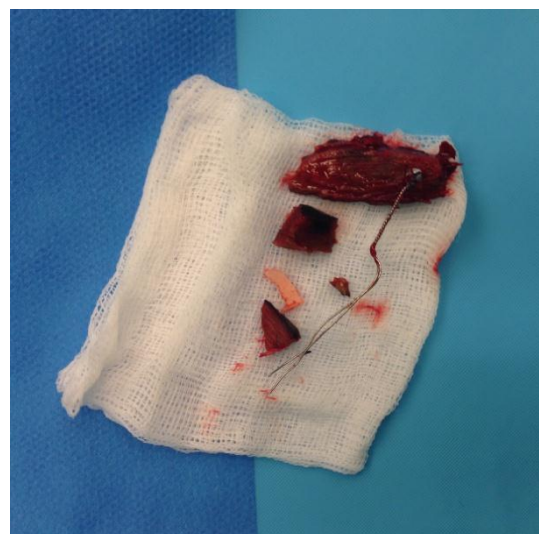

Fig. 2 The wooden twig removed from the right orbit

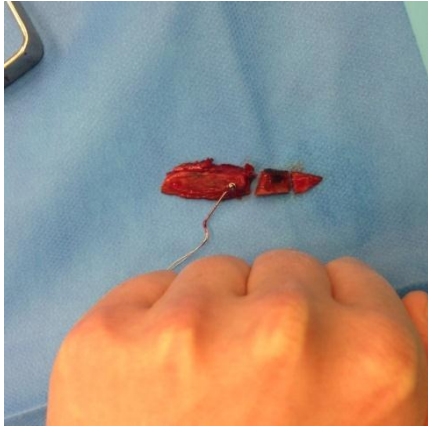


Fig. 3 Comparing the size of a foreign body to the fist

Discussion:

Injuries caused by the chipping of wood fragments into the orbital area are relatively frequent in men working without the use of appropriate protection in form of protective glasses. In order to locate a foreign body, an accurate history of the trauma, physical examination and imaging should be performed [1,2,3]. In case of the patient, CT was used, which is the first choice test, because clinical symptoms may result not only from the presence of a foreign body, but also from bone orbital bone fractures or post-traumatic hematoma. Despite advanced methods, some cases of especially multiple organisms with organic structure pose diagnostic difficulties. [1,2,8]. It is very important for assessment of the diagnostic procedure to assess the extent of injury, way of penetration and the material from which foreign body is built. Examination of fundus, assessment of eye strain, examination of visual acuity, reflexes to light, field of vision, eye mobility and possible double vision assessment. Wounds and injuries that penetrate the eye socket require rapid medical intervention, because even a small foreign body present in the eye socket can lead to many complications, both acute and chronic. In addition to direct injury to the optic nerve resulting in a sudden loss or visual impairment, chronic inflammation of orbital structures, osteomyelitis and vasculitis may develop [5]. Organic foreign bodies are a greater threat, because a higher percentage of threatening complications and infections was noted than in the case of inorganic foreign bodies [1]. Empirical antibiotic therapy is recommended

because of possibility of rapid spreading of infection, and because of location of the infection near the brain. Depending on size of the foreign body, different methods of its removal are used. In a situation where the foreign body is large, it may become lodged, and it should be fragmented into smaller parts. It should be remembered that wooden foreign bodies are very brittle, therefore they should be removed very accurately, and the cut inside the eye should be kept to a minimum. Always the eye socket should be intensively rinsed with antibiotics [6,7].

Conclusion:

It should be emphasized how important is the multidisciplinary cooperation of maxillofacial surgeons together with an ophthalmologist. The only effective method of treatment is careful surgical removal of the foreign body. All patients should receive post-operative antibiotic therapy due to the high frequency of secondary orbital infections. The final outcome and prognosis depend to a large extent on the location of foreign body and on whether there are serious complications. Described case is a confirmation of rule of injuries of the facial part of the skull in men who do not comply with the principles of health and safety at work.

References:

1. Abdullah Al-Mujanini "Intraorbital Foreign Body: Clinical Presentation, Radiological Appearance and Management" Sultan Qaboos Univ Med J. 2008 Mar; 8(1): 69–74.
2. Cartwright M. J., Kurumety U. R., Frueh B. R.: Intraorbital wood foreign body. Ophthal. Plast. Reconstr. Surg., 1995, 11, 44-48.
3. Chen C. S., Davis G. J., Selva D.: Orbital foreign body misdiagnosed as superior orbital rim fracture. Clin. Exp. Ophthalmol., 2002, 30, 295-296.
4. Machamer R, Van Horn D, Aaberg TM: Pigment epithelial proliferation in human retinal detachment with massive periretinal proliferation. Am J Ophthalmol 1978, 85, 181-191.
5. Markowski J, Dziubdziela W, Gierek T, Witkowska M, Mrukwa-Kominek E, Niedzielska I, Paluch J " Intraorbital foreign bodies – 5 own cases and review of literature." Otolaryngol Pol. 2012 Jul-Aug;66(4):295-300.
6. Li J, Zhou LP, Jin J, Yuan HF " Clinical diagnosis and treatment of intraorbital wooden foreign bodies." Chin J Traumatol. 2016 Dec 1;19(6):322-325

7. Tas. S, Top H "Intraorbital wooden foreign body: clinical analysis of 32 cases, a 10-year experience." *Ulus Travma Acil Cerrahi Derg.* 2014 Jan;20(1):51-5
8. Bartkowski S. B., Zapała J., Wszyńska-Pawelec G.: Postępy w diagnostyce i leczeniu chorych z obrażeniami układu wzrokowego. *Okulistyka*, 1998, 4, 3-6.