

## Physiotherapy treatment of patients with perinatal brachial plexus injury

Postępowanie fizjoterapeutyczne u pacjentów z okołoporodowym uszkodzeniem splotu barkowego

**Anna Lewandowska<sup>1</sup>, Dorota Ratuszek-Sadowska<sup>1</sup>, Monika Kuczma<sup>2</sup>,  
Waldemar Kuczma<sup>3</sup>, Mikołaj Kurczewski<sup>4</sup>, Wojciech Hagner<sup>1</sup>**

<sup>1</sup>Chair and Rehabilitation Clinic, Collegium Medicum Ludwika Rydygiera in Bydgoszcz, Nicolaus Copernicus University in Toruń

<sup>2</sup>Faculty of Physiotherapy and Health Sciences, College of Management in Gdańsk

<sup>3</sup>Institute of Physical Culture and Health, State Higher Vocational School in Koszalin

<sup>4</sup>Chair and Department of the Basics of Physical Culture, Collegium Medicum Ludwika Rydygiera in Bydgoszcz, Nicolaus Copernicus University in Toruń

### Streszczenie

Okołoporodowe uszkodzenia splotu ramiennego są zazwyczaj konsekwencją dystocji barkowej podczas porodu, kiedy po urodzeniu główki występują trudności przy rodzeniu barków. W tej sytuacji dochodzi do zatrzymania akcji porodowej, a barki płodu nie rodzą się samoistnie. Rozwój medycyny zapewnia dostęp pacjentom do wielu metody leczenia tego urazu. Potrzebny jest interdyscyplinarny zespół specjalistów aby minimalizować negatywne skutki uszkodzenia, które są odczuwalne dla pacjenta, niekiedy przez całe życie. Wiedza na temat fizjoterapii w okołoporodowym uszkodzeniu splotu barkowego ma duże znaczenie dla przyszłości dziecka, które doznało okołoporodowego urazu splotu barkowego. W związku z tym ten temat powinien być wciąż rozwijany i na nowo badany tak, aby w przyszłości można było zapewnić pacjentom wielospecjalistyczną opiekę.

**Słowa kluczowe:** splot barkowy, okołoporodowe uszkodzenia splotu ramiennego, postępowanie, rehabilitacja

## **Abstract**

Perinatal brachial plexus injury are usually a consequence of shoulder dystocia during childbirth, after the birth of the head there are difficulties with the birth of the shoulders. In this situation, childbirth is stopped and the shoulders of the fetus are not born spontaneously. The development of medicine provides patients with access to many methods of treating this injury. An interdisciplinary team of specialists is needed to minimize the negative effects of damage that are perceived by the patient, sometimes throughout life. Knowledge about physiotherapy in perinatal damage of the shoulder plexus is of great importance for the future of a child who suffered perinatal trauma to the shoulder plexus. Therefore, this topic should be constantly developed and re-examined so that in the future we can provide patients with multi-specialist care.

**Key words:** brachial plexus, perinatal brachial plexus injury, treatment, rehabilitation

## **Introduction**

Continuous development of medical sciences, increases the standards of treatment and care for the mother and child during the perinatal period. Despite this, one of the frequent complications of prolonged labor - mainly the forceps birth or gluteus birth, there is still a high risk of damage to the plexus of the newborn.

Brachial plexus is one of the components of the peripheral nervous system of a very complicated structure in which there are individual differences. Damage to the shoulder plexus is classified at different levels and in different sections. Therefore, the clinical picture of the same type of damage can be vary. In addition, diagnosis of infant paralysis is complicated by hematomas and swelling that occur after a childbirth. However, the assessment of this damage is very important because it determines the entire course of further physiotherapy. Therefore, apart from specialized medical tests, very limited in the case of newborns due to invasiveness, the Suderland, Seddon or other scales are used in the diagnosis.

The main mechanisms of perinatal damage of the shoulder plexus are traction or pressure. In the first case the forces acting indirectly on the plexus by stretching the surrounding structures. Such a mechanism takes place when during delivery, there is a dynamic stroke behind the head,

shoulder or arm of the newborn. The second of the compression mechanisms arises as a direct result of the forces of crushing or squashing nerve structures. This is mainly the reason for neck support to the mother's womb, the wrapping of the umbilical cord around the neck of the child, erroneous attachment of the ticks by the doctor.

In the case of diagnosis of perinatal brachial plexus injury it is extremely important for the patient to start long-term, systematic and comprehensive treatment as early as possible. It is important to bring to the functionality of the upper limb as far as possible and to protect it from further, possible deformations [1]. Therefore, the patient requires multidisciplinary treatment, which will involve the whole team of specialists: pediatrician, neurologist, orthopedist, neurosurgeon, rehabilitator, physiotherapist, psychologist, occupational therapist, orthotist and social assistant. In addition, it is important to monitor the course of treatment (in order to make possible neurosurgical and orthopedic intervention) and its progress in the frequency depends on the age of the child, e.g. a six-month child – check carried out once a month, a child up to two years - check every three months, older child - control once every six months [1]. In addition, it should be remembered that treatment of plexus injury includes not only physiotherapeutic treatment (conservative), but also surgical intervention (surgical treatment). The specialist chooses the method of treatment based on the results of the clinical trial.

### **The treatment and therapy**

Kinesitherapy (gr. kinesis - movement) is knowledge about the use of movement as a healing method. Most often this form of physiotherapy is used in the rehabilitation of the locomotor system. Before starting the kinesitherapy the patient should be diagnosed in detail. Research in this case resembles orthopedic examination, except that a greater emphasis is places on evaluation of multiple functions in the sense of the term. Kinesitherapy aims to reduce the patient's physical disability as much as possible and prepare it for further rehabilitation [2].

Treatment by kinesitherapy in perinatal damage of the shoulder plexus is made up from several stages matched to the child's development and his state of health. The following are all stages from birth to the age of sixteen.

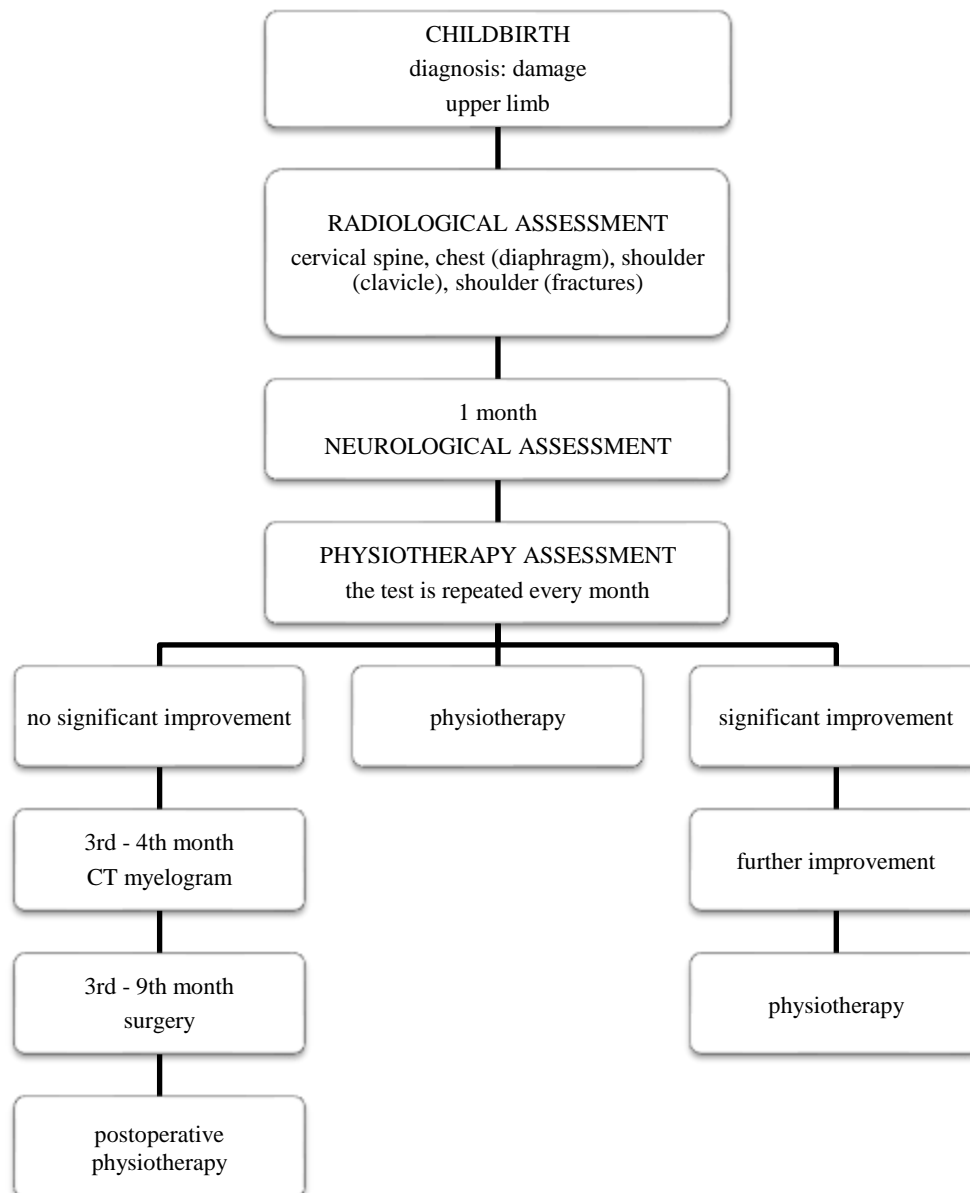


Fig.1. Currently used diagnostic and therapeutic procedures proposed by Children Hospital in Houston [3].

The initial movement improvement takes place in the neonatal unit, and then in the rehabilitation or outpatient ward, under the supervision of parents, in accordance with the instructions received from the physiotherapist. Regardless of the adopted plan of conduct, in the first days of the child's life attention is focused mainly on the proper protection of the affected limb, in order to avoid possible injuries (it is called positional therapy). It consists in placing the arm at rest, at the level of the lower ribs, in the attachment and slight flexion in the elbow (up to about 70%), which can be obtained by attaching the sleeve from the child's clothes to his diaper. However, this position should be changed from time to time to avoid contracture

[4]. Using positional therapy, we immobilize the upper limb in the abduction and external rotation. This arrangement causes stretching of the brachial plexus, contractures of the posterior capsule, protruding of the humeral head from the shoulder of the shoulder joint and dysfunction of the elbow joint. Instead, the affected limb is placed in an intermediate position, lifting it to the height of the head with a slight external rotation in the shoulder joint and slight flexion in the elbow joint [4,5].

In the first days of the child's life only tactile (sensory) stimulation is used, based on a gentle massage, due to providing the patient with a post-traumatic state of calmness, promoting swelling and hematoma absorption, reducing pain after childbirth, and to raise the awareness of the child about having an affected limb [6,7]. After the sixth day of life, the limb can be positioned along the torso, allowing the child to perform spontaneous movements. However, it should be remembered that the affected limb is exposed to vegetative disorders and related to temperature regulation. Therefore, it is protected with a woolen sleeve or a warm quilt. When placing the patient's trunk, you can support it by so-called sockets, it means thin cotton rollers, filled with cotton and polyurethane balls. They allow for proper positioning and allow for spontaneous movements. They can be appropriately modeled to protect the hips and shoulders, maintain the correct position of the head (in the centerline relative to the body). Sockets also play an important role in stimulating psychomotor development and body awareness. They support the work of the diaphragm, which reduces the child's breathing effort.

When the shoulder plexus is paralyzed, it is also important to remember that the basic functions should be performed correctly. For example, an infested arm should not hang loosely when worn. Dressing up the child must be started from the inaccurate side, and the undressing from the healthy side. During the bath, one hand should support the shoulder and blade, changes sides while feeding, and place the inaccurate limb on the child's chest. The affected limb must be also kept clean and dry [4].

During the first three months of the newborn's life, spontaneous regeneration of nerve fibers should occur. Neural signals do not reach muscles, so physiotherapy has an important function of delaying muscle wasting. From the sixth day after the birth of the child, the upper limb massage is carried out towards the torso, which improves blood circulation and reduces swelling of the tissues. Passive exercise is also performed and stimulates the positioning of the torso and the head [4,5]. Passive exercises consist in performing movements in the elbow and shoulder joint in all planes and in the full range. Exercise should be carried out with extreme caution so as not to damage the shoulder joint. In the case of damage to the lower part of the brachial plexus, passive exercises involve bending the hand in the wrist joint in the dorsal, palmar, radial

and ulnar directions. It is also necessary to abduct the fingers from the second to the fifth and to abduct and adduct the thumb. In addition, it should be used to relieve the affected limb while immersed in water, so as to encourage the child to make independent movements [7,8].

In the second week, we can also gradually give up the passive alignment paretic limb. At this stage, it is recommended to start Vojta therapy. This is one of the specialist kinesitherapeutic methods. The goal here is to increase the stimulation (temporal and spatial) of the perceptual part of the central nervous system. Thanks to this it is possible to activate the neuromuscular patterns stored in the genotype (creeping and rolling) [8]. In Vojta therapy, it is important to stimulate the serratus anterior muscle responsible for lifting the arm above the shoulder, as well as stimulating bone points. In the early months, support activity and torso verticalization are also important. The baby should be placed as often as possible so that, lying on his stomach, he supports himself on his elbows. It is important to correct the spine and avoid asymmetry in the child's arrangement. They should be taught to put their hands in their mouths, reach for toys to practice body coordination. In the case of older children who have contractures and body deformities, a painful reaction may occur during exercise. Then it should be determined what pain the child can withstand without straining the body [4].

The next stage is the third - fourth month of the child's life. The treatment taken at this time depends on the clinical condition of the affected limb and any surgical procedures carried out. At this stage, usually active exercises, periarticular joints mobilizations, exercises in unloading, active with the use of tools, locomotion with the longest possible time of crawling are used [4]. At this stage, active exercises may involve provoking movements, e.g. by tickling the child during play. During active exercises, when the lower part of the brachial plexus is damaged, attention should be paid to stimulating the wrist and back [7, 9].

At the stage of the third - fourth month of the child's life, exercises are started according to the Bobath Neuro Developmental Treatment (NDT - Bobath). Their goal is to achieve the highest efficiency and independence of movement by the patient, including:

- normalization of muscle tone;
- restoration of the full range of movement in the joints;
- sensory preparation, i.e. reinforcement of areas of special sensitivity;
- blocking abnormalities and supporting good physiological reactions [8].

Working with this method, the aim is to lower the shoulder girdle, to develop the mobility between her and the humerus, to open the hand (allowing the patient to support and grip), correct weight transfer with simultaneous shortening of the unloaded side, lengthening of the load and lateral head lifting, which allows the development of straightening reactions [4].

<b>CHILD'S AGE</b>	<b>UNDERTAKEN ACTIVITIES</b>
The first days of life	performing basic research, proper positioning of the limb
Until the 4th week	performing passive exercises in a rehabilitation or outpatient ward, carried out under the supervision of parents, according to the instruction received in the hospital
5th week	introduction of regular and intensive physiotherapy, kinesitherapeutic and physiotherapeutic procedures in the rehabilitation or outpatient ward
3 - 4 months	neurophysiological examination, assessment of conditions for possible neurosurgical surgery, then possible to perform necrolysis (nerve release or excision of fibrous lesions on the nerve) or necrotization (nerve transplantation and dislocation)
1st year of life	in the absence of satisfactory results - another neurosurgical operation
2nd year of life	in the absence of satisfactory results, low functionality of the hand - a second operation involving the transplantation of muscles or tendons

Tab.1. Diagram of the procedure for perinatal brachial plexus injury (own study based on M.R. Grodner)

At the stage of the eleventh to eighteenth month of the child's life, exercises involving the Proprioceptive Neuromuscular Facilitation (PNF) method are included. In this case, the phenomenon of irradiation is used [8]. When selecting the correct position, the motor and the resistance pattern is induced indirectly the tension in the weakened muscles. This method uses approximation, allowing stimulation of antigravity muscles and facilitation of equivalent reflexes, as well as stretching, increasing the willingness to contract a specific group of muscles. The PNF method facilitates the commencement, learning and automation of movement, regulates its tempo and rhythm, increases the range of motion, relaxes it, affects the strengthening of stability, strength and control [4].

In the eleventh - eighteenth month introduced the exercises in the water, hippotherapy, manual therapy, occupational and other exercises to improve grip, and the movements of supination and external rotation of the forearm. The correct position of the hand and forearm is stabilized with patches. In the fourth month it is also introduced corrective orthosis, but using them must be prevented circulatory disorders manifested, inter alia, swelling and numbness. In the eighteenth month, after the orthopedic examination, the corrective gymnastics begins, aimed at stretching and conscious control of the attitude. With the adolescence of a child, the physiotherapy should be extended with various activities, e.g. swimming is one of the better methods of exercising with posture defects [4].

Psychomotor development is a close connection between the mental, cognitive and motor development of children. Movement disorders delay the process of experiencing in the immediate environment, and thus have a negative impact on the child's cognitive abilities. Physical defects translate into frustration, and this often causes emotional problems. Therefore, in the rehabilitation of perinatal damage of the shoulder plexus, conservative treatment - physiotherapy - plays such an important role. It is a long and tedious process of restoring mobility in an affected limb. The involvement is therefore necessary in the work of a physiotherapist, patient and his family. Therefore, the physiotherapist should at each stage, cooperate not only with the patient, but also with his caregivers.

### **Summary**

Various data on etiology, epidemiology and clinical symptoms of perinatal shoulder plexus injury are mentioned in the literature. Acquaint with this information is necessary for the proper implement of the physiotherapy process, and thus has an impact on the future functioning of the patient. The physiotherapist's role is therefore very important in restoring the patient to the fullest possible efficiency in the affected upper limb. Physiotherapy should start in the neonatal ward, because in the first year of life, the central nervous system is the most plastic. It is then in the phase of unfinished development and many processes continue in it. It is therefore easier to form a new nerve pathway and activate the spare, healthy brain cells. Physiotherapy is a long and tedious process of restoring mobility in an affected limb, in which it is necessary to involve and cooperate with many specialists, the patient and his family.



## **Bibliography**

1. Grodner M.R., Okołoporodowe uszkodzenie splotu ramiennego. [W:] Kuliński W., Zeman K. (red.), Fizjoterapia w pediatrii. Wydawnictwo Lekarskie PZWL, Warszawa 2012: 57–66.
2. Zembaty A. (red.), Kinezyterapia. T. 1. Wydawnictwo „Kasper”, Kraków 2002.
3. M. Matyja, L. Naziemiec, A. Gogola, Uszkodzenia splotu ramiennego u dzieci – aktualne możliwości leczenia i usprawniania: <http://www.fizjoterapeutom.pl/>.
4. Okulczyk K., Kułak W., Okołoporodowe uszkodzenie splotu ramiennego. [W:] Kułaka W., Okurkowska-Zawada B., Sienkiewicz D., Paszko-Patej G. (red.), Współczesne metody rehabilitacji dzieci i młodzieży. Uniwersytet Medyczny w Białymstoku – Wydział Nauk o Zdrowiu, Białystok 2014: 26–45.
5. Wroński Z., Rehabilitacja w okołoporodowym uszkodzeniu splotu barkowego. Praktyczna Fizjoterapia i Rehabilitacja 2014.
6. Okołoporodowe uszkodzenie splotu ramiennego. O czym warto wiedzieć, gdzie szukać pomocy, broszura Fundacji Splotu Ramiennego, [https://www.wss2.pl/files/dokumenty/broszura\\_internet\\_pg.pdf](https://www.wss2.pl/files/dokumenty/broszura_internet_pg.pdf).
7. Czochańska J., Wczesne rozpoznawanie i metody postępowania w uszkodzeniach układu nerwowego u dzieci. Wydawnictwo Lekarskie PZWL, Warszawa 1997.
8. Kokosz M., Metoda Wojty. [W:] Zembaty A. (red.), Kinezyterapia. T. 2, Wydawnictwo „Kasper”, Kraków 2002: 387–393.
9. Czochańska J. (red.), Neurologia dziecięca. Wydawnictwo Lekarskie PZWL, Warszawa 2010.