

## The problem of divers, aviators and paratroopers - barotrauma of the paranasal sinuses

Katarzyna Adamczyk<sup>1</sup>, Dorota Adamczyk<sup>1</sup>, Rafał Wójcik<sup>2</sup>

<sup>1</sup>Student, Medical University of Lublin

<sup>2</sup>Department of Human Anatomy, Medical University of Lublin

### Abstract

Barotrauma of the paranasal sinuses is a trauma caused by a large difference in air pressure between the sinuses and the environment. It concerns essentially divers, aviators, as well as paratroopers. A characteristic symptom is sudden and piercing pain in the sinus area. The pain begins while the ambient pressure is changing or an instant later. The result of a pressure injury may be an epistaxis. Sinusitis may be also an effect of sinuses' mucosal damage. Drugs used primarily in patients with pressure-related injury are vasoconstrictive medicaments and analgesics. Antibiotics are also applied in some situations. Because the incidence of barotrauma increases in predisposed people, e.g. with anatomical abnormalities, nose surgery, including correction of the nasal septum or paranasal sinuses, i.e. canthotomy, is used to prevent injury.

**Keywords:** barotrauma, paranasal sinuses, ascend injury, descend injury, diving

## **Introduction**

For the first time, sinus barotrauma was described by Campbell in 1944. He noticed that aerosinusitis in the general population is a very rare condition. On the other side, the population which is exposed to pressure changes, such as aviators or divers, has got a high incidence rate. In his conclusion, he pointed out that the responsibility of aviators' health depends on appropriate pressurization of the aircraft. [1][2]

Polish scientists also contributed to disseminate knowledge about barotrauma. Divers were their research group. The studies of Klejman, who was the first person in the world who had described the radiological image of the maxillary sinuses in divers, showed that the reducing sinus's aeration does not reduce the ability to work underwater. Despite the human's body persistence to fluctuations of ambient pressure, the changes in sinuses are very noticeable.[3][4]

The beginning of researches on occupationally exposed groups has contributed to the understanding of the mechanism of injury, the methods of its prevention and treatment.

## **Anatomy**

The paranasal sinuses are pneumatic spaces covered by mucosa. They are inside the cranium's bones and are an extension of the nasal cavity. We distinguish several paranasal sinuses. The largest is the maxillary sinus, located in the shaft of the maxilla. The volume of this sinus is about 15 ml. The sinus connects with the nose through a maxillary hiatus, which is located in the medial wall of the sinus. Because the bottom of the sinus is concave and the hiatus of the sinus opens to the middle nasal meatus, this self-evacuating of the cavity is difficult. In addition, the proximity of the sinus's floor with the roots of the first molar and second premolar is conducting for odontogenic sinusitis. [5][6]

Another paranasal sinus is the frontal sinus, which is half the size of the previous one. The capacity is from 5 to 7ml. In most people, we distinguish two frontal sinuses. Usually they differ in size and shape. From 3 to 5% of the population is completely deprived of frontal sinuses. The frontal sinus connects to the nasal cavity via the nasofrontal duct. The outlet of the duct is located under the head of the middle nasal concha. The bottom of the frontal sinus forms the upper wall of the orbital cavity, which is why this location can be the point of spreading inflammation. Whereas the posterior sinus's wall, which is also the wall of the anterior cranial fossa, is a potential route of nasal complications. [5][6][7]

An ethmoidal labyrinth is also a structure filled with air. It is built of tubal air cells. These are the bone cavities that communicate with each other and are covered by the mucous membrane.

The tubal air cells are arranged in the anterior and posterior groups. Their total volume is about 3 ml. The ethmoidal labyrinth is the only sinus that is formed since human's birth. The ethmoidal cells adhere from the top to the anterior wall of the cranial base, whereas laterally to the orbital cavity. These locations can be the ways of spreading rhinological infections. At the back, the ethmoidal labyrinth connects to the sphenoid bone, in which the sphenoidal sinus is located. It is a paranasal sinus which is characterized by high variability. Its volume varies between 0,5 and 3 ml. On average, 3-5% of the population does not have any sphenoidal sinus. This sinus's ostium is located above and backwards from superior nasal concha. The close proximity of the sphenoidal sinus to the pituitary gland and the optic chiasm is a disadvantage if we consider this in terms of spreading rhinologic complications. However, considering the aspect of operating access to the pituitary gland, this is a significant advantage. [5][6]

Each sinus is covered with the mucous membrane. Around the ostiums of the sinuses there is a cavernosal tissue, which has the ability to expand. This structure and nasal conchas determine the patency of the ostiums and form the ostiomeatal complex. [5]

### **Obstruction - pathomechanism and causes**

The paranasal sinuses, in addition to reducing the cranial bones mass, increase the cranium's size. They can also cause problems because of the ostium's obstruction. The discharge remaining in the sinuses changes the composition and the pH value of the secretions. This cellular revolution has a harmful impact on the epithelium and ciliary apparatus. It leads to inflammation of the lamina propria and thickening of the mucous membrane. The thickened mucosa impedes sinus's drainage. It is difficult to stop this vicious circle. It usually requires the intervention of a doctor who removes the cause of the obstruction, either conservatively or surgically.[5]

The causes of obstruction may be acquired (prolonged nasopharyngeal intubation), congenital (nasal septum deviation) or environmental (toxic fumes). However, the most common causes of barotrauma include inflammation of the nasal mucosa and sinuses. The less frequent are polyps of the nose and sinuses, overgrown mucous membrane and nasal conchas or a nasal septum deviation. A very rare cause of obstruction, and thus a pressure injury, can be tumors. [5]

### **Barotrauma - pathomechanism, types, symptoms**

The location of obstruction plays a relevant role in the pathomechanism of a pressure injury. The duct which connects the sinus to the nasal cavity may be obstructed from the side of sinus

or nasal cavity. In the case of its closure from the sinus's side, trauma's pressure arises during expansion, i.e. pending the diver's ascent or increasing an altitude over flight. If the ambient pressure rises, the pressure in the paranasal sinuses does not decrease. Overpressure develops in the sinus. This is an "ascend" type of injury. Its opposite is the "descend" type of injury. It comes to it during compression (e.g. dipping, landing or parachute jump) in the group of people suffering from the obstruction of the duct from the nasal side. When diver dips, the ambient pressure increases and a negative pressure is generated in the sinus. Because the pressure in the sinus is equal to the atmospheric pressure. [8] According to Fagan's studies the descend type of injury is twice as frequent as the "ascend" barotrauma. [9]

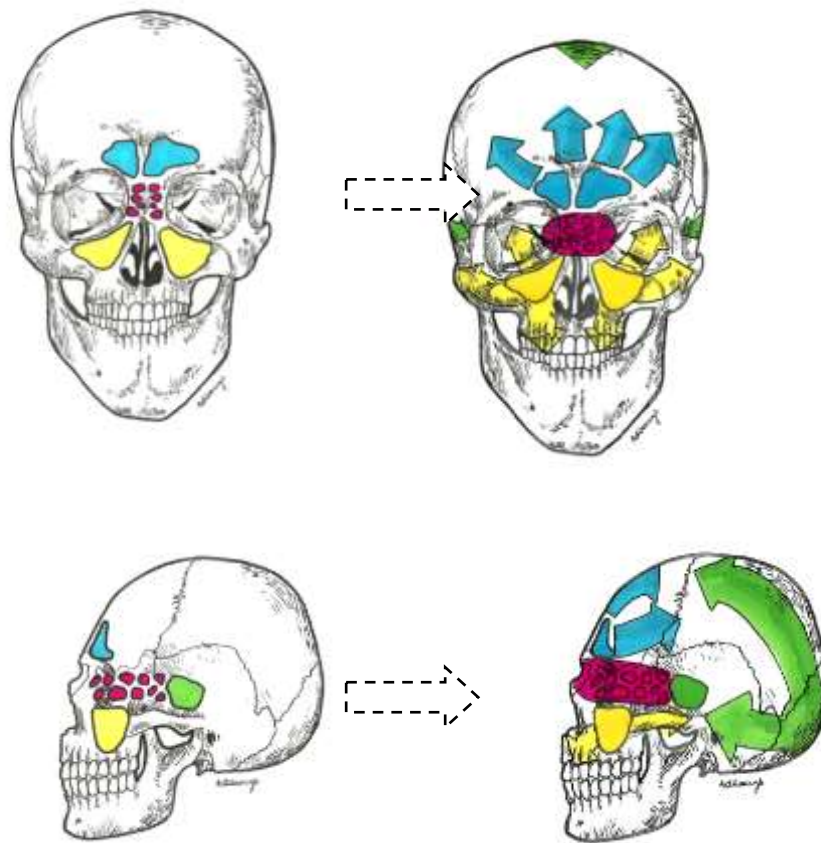
	<b>"Ascend" barotrauma</b>	<b>"Descend" barotrauma</b>
<b>Location of the obstruction of the duct connecting sinuses to the nasal cavity</b>	From the paranasal sinus's side	From the nasal side
<b>Potential causes of the obstruction</b>	Inflammation of the sinus's mucosa, polyps, overgrown mucosa, tumors	Inflammation of the mucous membrane of the nasal cavity, polyps, nasal septum deviation, overgrown nasal conchas, tumors
<b>Pressure inside the sinus (in regard to the ambient pressure)</b>	Overpressure	Negative pressure
<b>Ambient pressure</b>	Decrease	Increase
<b>Frequency</b>	X	2x
<b>Risky situations</b>	Resurface	Immerse, parachute jump, landing

Tab. 1. Comparison between two types of barotrauma.

The pathomechanism of the injury is the clinical manifestation of Boyle-Mariotte law, which states that: "The absolute pressure exerted by a given mass of an ideal gas is inversely proportional to the volume it occupies if the temperature and amount of gas remain unchanged within a closed system." [10][11][12]

A pressure-related injury may also occur during partial occlusion of the duct connecting the sinus to the nasal cavity. Then, the occurrence of barotrauma is more than usually dependent on the velocity of pressure changes. Too fast change makes it impossible to adequately equalize the pressure between sinus and ambient. The resonance of this is pressure injury. [8]

Both types of barotrauma of paranasal sinuses have similar symptoms. The most common is strong and piercing pain of the sinus area. The location of pain often indicates a damaged sinus. The ethmoidal labyrinth's damage is characterized by the occurrence of pain in the area of the medial angle of the eye. Whereas the multifocal or radiating pain of the occipital region may indicate a sphenoid sinus injury. [13] The injury of the largest sinus - the maxillary sinus, is manifested by pain of the area of the cheek, upper teeth or the orbit. The frontal sinus's ache is marked with spreading over the forehead. Fagan's research indicates that the intensity of the ache associated with maxillary sinus's and ethmoidal labyrinth's trauma is less perceptible than pain of the frontal sinus. [8][9][14]



Pic. 1. Radiation of pain in case of nasal sinus's barotrauma.

- Maxillary sinus
- Ethmoidal labyrinth
- Sphenoidal sinus
- Frontal sinus

Another common symptom is epistaxis - bleeding from the nasal cavity. Due to the diagnostic imaging fluid levels, occlusion of the sinus and thickening of the mucous membrane are visible. This arises from the presence of blood and overproduction of mucus. The complication of barotrauma is chronic sinusitis, which causes hypertrophy of the sinus's mucosa. Chronic inflammation mainly affects the maxillary sinus. [15] [16] Yaganawa's surveys have confirmed that divers had a tendency toward hypertrophy of the mucous membrane of paranasal sinuses. [17]

Weissman created a grading system which classifies divers and other people to appropriate group. It is based on the severity of pressure injury. [18]

Grade	X-ray changes	Symptoms from sinuses	Situation
I	Absent or present slight mucosal oedema	Transient discomfort	Squeeze situation or reversed squeeze situation
II	Present (mucosal thickening)	Pain lasts <24 hours, Serosanguinous fluid*	
III	Fluid levels*, Polypoid mass as an expression of submucosal hemorrhage*	Severe pain or a "bee sting" sensation, pain lasting occasionally >24hours	Result of the squeeze

Tab.2. Weissman's grading system of sinus barotrauma.

The imaging plays a relevant role in protecting against barotrauma. The X-rays, CT (Computed Tomography) scans and MRI (Magnetic Resonance Imaging) scans together with a laryngological consultation enable to exclude or confirm obstruction of the duct connecting the sinuses to the nasal cavity. In the case of obstruction, fast removal of the obstacle prevents barotrauma. [19] Barotrauma can be eliminated by effective treatment of sinusitis. Moreover, as a part of the prophylaxis some divers use drugs that anemizes the nasal mucosa. However, it should be remembered that long-term use of sympathomimetic amines, i.e. xylometazoline, increases the hyperemia of the nasal mucosa, causing the opposite effect to the expected one.[20]

In the case of appearing symptoms of barotrauma, the diver should returned as far as possible to the depth on which the symptoms are absent. If we do not have such a possibility, for example during a parachute jump, it is recommended to use analgesics, anti-inflammatory agents and vasoconstrictive medicaments. In some cases, applying antibiotics is indicated. [14] It is advised also to use by divers positive pressure middle ear equalisation. A Valsalva

maneuver can aerate the sinuses and prevent them against pathology called barotrauma. We should remember that about 10% of repetitive incidents is caused by inappropriate diving and equalisation techniques. The feet first descent and frequent positive-pressure middle ear equalisation can successfully protect diver's sinuses.

[21][22]

### **Conclusion**

Knowledge of paranasal sinus barotrauma is significant in such professions as: aviator or diver. To reduce the likelihood of accidents, these people should get to know how to minimize a risk. The most important is regular medical appointment. Imaging allows to detect thicken mucosa of the sinus/ nasal cavity, polyps or another reasons of ductal obstruction. Physiological architecture of the mucosa and awareness safe diving technique protect the sinuses against pressure injury. In case of barotrauma, quick treatment apply can prevent from serious and chronic complications.

## References:

1. Campbell PA. Aeroinusitis - Its causes, course and treatment. *Ann Otol.* 1944; 53: 291-301
2. Campbell PA. Aeroinusitis - a resume. *Ann Otol.* 1945; 54: 69-83
3. Klajman S, Dęga K, Torbus J, Wlazłowski Z. Wpływ wysokich ciśnień na obraz radiologiczny zatok szczękowych u nurków. *Rocznik Sł. Zdr. Mar. Woj.* 1964; 74-81
4. Węglewski M. IX KONFERENCJA POLSKIEGO TOWARZYSTWA MEDYCYNY I TECHNIKI HIPERBARYCZNEJ.
5. Becker, Walter, et al. Choroby uszu, nosa i gardła. 1999; 175-181
6. Bochenek A, Reicher M. *Anatomia człowieka, tom I.* 2002.
7. Łasiński W. *Anatomia głowy dla stomatologów.* 1993.
8. Siermontowski P, Spalek E. Uraz ciśnieniowy zatok obocznych nosa u nurków. *Polish Hyperbaric Research* 2005; 30-35
9. Fagan P, McKenzie B, Edmonds C. Sinus barotrauma in divers. *Annals of Otolology, Rhinology & Laryngology.* 1976; 61-64
10. Edmonds C, Lowry C, Penefather J, Walker R. *Diving and Subaquatic Medicine, Fourth edition.* 2002
11. Webster C. The Discovery of Boyle's Law, and the Concept of the Elasticity of Air in the Seventeenth Century. *Archive for history of exact sciences* 1965; 441-502
12. [https://en.wikipedia.org/wiki/Boyle%27s\\_law](https://en.wikipedia.org/wiki/Boyle%27s_law)
13. Lawson W, Reino AJ. Isolated sphenoid sinus disease: an analysis of 132 cases. *The Laryngoscope* 1997; 1590-1595
14. Slavin RG, et al. The diagnosis and management of sinusitis: a practice parameter update. *Journal of Allergy and Clinical Immunology* 2005; S13-S47
15. Garges LM. Maxillary sinus barotrauma: case report and review. *Aviat Space Environ Med.* 1985; 56: 796–802
16. Yoram S, Landsberg R, Fliss DM. MR imaging appearance of frontal sinus barotrauma. *American journal of neuroradiology* 2003; 346-347
17. Yanagawa Y, Okada Y, Ishida K, et al. Magnetic resonance imaging of the paranasal sinuses in divers. *Aviat Space Environ Med.* 1998; 69: 50-2
18. Weissman B, Green RS, Roberts PT. Frontal sinus barotrauma. *Laryngoscope* 1972; 82: 2160–2168
19. Zinreich SJ, et al. Paranasal sinuses: CT imaging requirements for endoscopic surgery. *Radiology.* 1987; 769-775
20. Jackson RT. Mechanism of action of some commonly used nasal drugs. *Otolaryngology—Head and Neck Surgery.* 1991; 433-440
21. Edmonds C. Sinus Barotrauma: A bigger picture. 1994
22. Edmonds C, Mckenzie B and Thomas R. *Diving medicine for scuba divers.* Melbourne: J. L.Publications. 1992