

Zaiats L.M., Kuz U.V., Zukow W. Correction of the ultrastructural changes of the respiratory department of the lungs by phosphatidylcholine liposomes due to multiple skeletal trauma with osteosynthesis in the experimental study. *Journal of Education, Health and Sport*. 2018;8(8):293-301. eISSN 2391-8306. DOI <http://dx.doi.org/10.5281/zenodo.1308228>
<http://ojs.ukw.edu.pl/index.php/johs/article/view/5642>

The journal has had 7 points in Ministry of Science and Higher Education parametric evaluation. Part B item 1223 (26/01/2017).
1223 Journal of Education, Health and Sport eISSN 2391-8306 7

© The Authors 2018;

This article is published with open access at Licensee Open Journal Systems of Kazimierz Wielki University in Bydgoszcz, Poland
Open Access. This article is distributed under the terms of the Creative Commons Attribution Noncommercial License which permits any noncommercial use, distribution, and reproduction in any medium, provided the original author (s) and source are credited. This is an open access article licensed under the terms of the Creative Commons Attribution Non commercial license Share alike.
(<http://creativecommons.org/licenses/by-nc-sa/4.0/>) which permits unrestricted, non commercial use, distribution and reproduction in any medium, provided the work is properly cited.

The authors declare that there is no conflict of interests regarding the publication of this paper.

Received: 25.06.2018. Revised: 28.06.2018. Accepted: 09.07.2018.

Correction of the ultrastructural changes of the respiratory department of the lungs by phosphatidylcholine liposomes due to multiple skeletal trauma with osteosynthesis in the experimental study

L.M. Zaiats¹, U.V. Kuz¹, W. Zukow²

¹State institution of higher education «Ivano-Frankivsk National Medical University», Ivano-Frankivsk, Ukraine

e-mail: patfisiology@ifnmu.edu.ua

²Faculty of Earth Sciences, Nicolaus Copernicus University, Torun, Poland

e-mail: w.zukow@wp.pl

Abstract

It was made the experimental study on white male rats by an electron microscopic method in dynamics (6, 24, 72, 168 h) and was studied the possibility of correction of ultrastructural changes of the respiratory department of the lung by phosphatidylcholine liposomes ("Lipin" medium) due to multiple skeletal trauma with the use of intramedullary osteosynthesis. It is defined that intraperitoneal Lipin administration in dose 50 mg/kg body weight during the first 24 hours after beginning of the study case decrease the expressiveness and prevalence of damage alveolar cells I and II type, haemocapilari endothelial cells and alveolar macrophages. The Lipin administration does not influence on the character of ultrastructural changes of the

respiratory department of the lung while increasing time of the experiment (72-168 hours).

Key words: lungs, multiple skeletal trauma, intramedullary osteosynthesis, Lipin.

Introduction

Nowadays it is known that polytrauma despite of sustain achievements in medicine is complicated by acute lung injury syndrome (ALIS) [1, 2, 6, 9, 11]. During the last years in the literature sources meet more and more reports about effectiveness of exogenous surfactants to treat this syndrome. The results of many trials have proved that administration of exogenous surfactants increase activity of antioxidant enzymes, improve gas exchange, blood oxygenation, ventilation parameters of lung function, qualitative composition of phospholipids surfactant [3, 8, 10, 13].

The special interest is concentrated on experimental and clinical studies of the biospecific activity the «Lipin» medium designed in Ukraine, the chemical base of it consists of хімічну phosphatidylcholine liposomes [7, 11, 12]. The number of researches showed antihypoxic, antioxidant and membrane-protective effect of this medium. The administration of Lipin improved ventilation parameters of lung function, lung haemodynamics, functional condition of alveolar macrophages and reduction of arterial hypoxemia [4, 5, 7, 12].

The aim of this study was define the possibility of correction by Lipin the ultrastructural changes of the respiratory department of the lungs due to multiple skeletal trauma with osteosynthesis in the experimental study.

Materials and methods

Study was made on 50 white male Vistar rats with bodyweight 180-230 g. Animals were distributed on three groups: I – modeling of multiple skeletal trauma + intramedullary osteosynthesis (40 animals), II - modeling of multiple skeletal trauma+ intramedullary osteosynthesis +Lipin® (40 animals) and III – intact (10 animals). All animals in group I and II were done modeling of multiple skeletal trauma – osteotomy of the both femur bones in the middle part according to the own technique [2]. Accept of modeling of multiple skeletal trauma was done intramedullary osteosynthesis by Kirschner wire 3 hours after trauma modeling. All manipulations were done under Tiopental anesthesia 60 mg/kg. All animals in I and II group received appropriate analgesia by Diclophenac sodium 10 mg/kg 3 times per (in the day of surgery 2 times). Animals of the II group also received Lipin ® (“Biolec” Kharkiv) in dose 50 mg/kg three times (just after trauma, before and just after osteosynthesis), the Lipin is the membrane protection medium based on the diphosphatidylcholine group.

Lung tissue sampling for light microscopic and electron microscopic study was made under Tiopental anesthesia 6, 24, 72, 168 hours after trauma by general methods. Lung tissue samples for electron microscopic study were fixed in the Glutarformaldehyde 2,5% solution and further postfixation by Osmium tetroxide 1% solution. Samples after dehydration were embed in the epon-araldit. Sections were done by ultramicrotome "Tesla BS-490" and studied by electronic microscope "IEM-125K".

Results and discussion

The results of electronmicroscopic study showed that animals of I group after 6 hours after beginning of the experiment had mainly reactive changes of the components of the respiratory department of lungs. It was found the hypertrophy of the Golgi complex (GC), rough endoplasm reticulum (RER) and moderate electronic-optical density of the mitochondria in the alveolar cells I and II types (A-I and A-II), endotheliocytes of the hemocapillaries, alveolar macrophages (AM). At the

same time in some haemocapilari were detected endothelial cells with light cytoplasm, enlarged components of smooth endoplasm reticulum (SER) and RER, mitochondria swelling and locally thickened base membrane.

The ultrastructural changes during 24 hours after beginning of the study in the alveolar cells, endotheliocytes and AM had severe hyperhydratation events. The number of lamellar bodies in the alveolocytes II is decreased. The erythrocytes' clots and aggregation and adhesion of leukocytes and platelets were in the haemocapillary space.

The intracellular swelling is still defined in the A-I, A-II, endotheliocytes and alveolar macrophages on the 72 hour of the experiment. There are platelets and leukocytes aggregates inside the haemocapillary space.

The expressiveness and prevalence of edema of the components in the respiratory department of lungs on the 168 hour of the study is less than on the previous stage.

The Lipin medium was used to correct above-mentioned submicroscopic disorders of the components in the respiratory department of lungs. The administration of it by intact animals did not influence on the ultrastructural organization of the A-I, A-II, endotheliocytes and AM. Whatever it was significant difference of the character and extension of changes of the structural elements in the respiratory department of lungs between treated and not-treated animals.

The ultrastructural analysis showed that alteration of AM, A-I, A-II and haemocapillary endotheliocytes on the background of Lipin administration had been spotted less often compared with not-treated animals during 6 hours after beginning of the study.

We would like to admit that the structural organization of lamellar bodies of alveolocytes II type was better saved (Fig. 1).

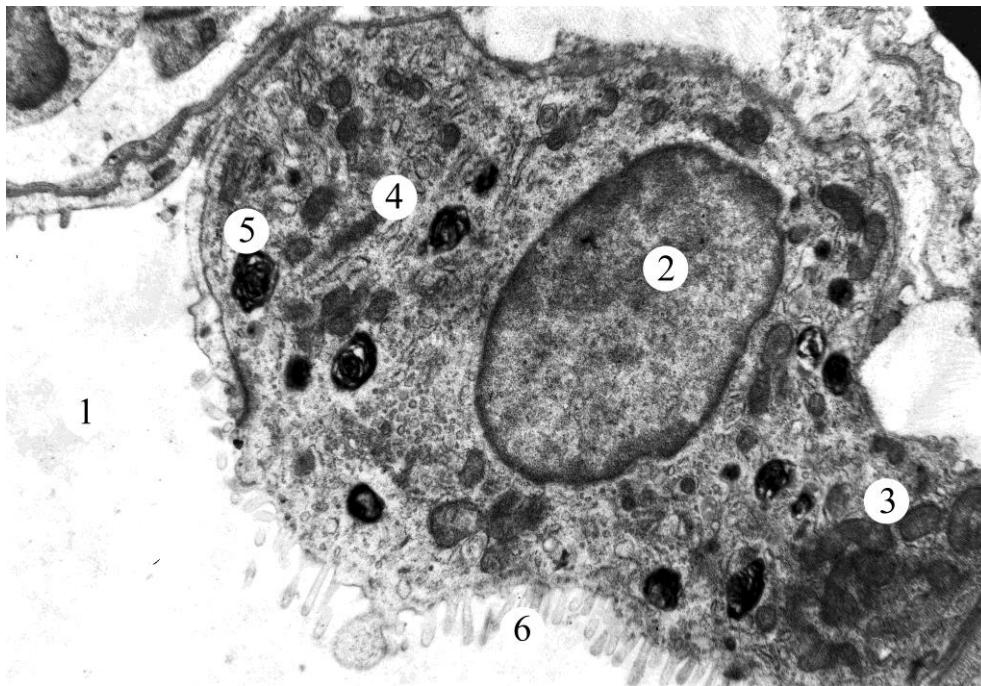


Fig. 1. Submicroscopic structure of the alveolar cell II type during 6 hours after the beginning of the experiment on the background of Lipin administration.

1 – alveolar space; 2 – nucleus; 3 – mitochondria; 4 – rough endoplasmic reticulum; 5 – lamellar body; 6 - microvilli.

Microelectronic picture. x6400.

Lamellar bodies (LB) are distributed along whole cytoplasm, but most of them are in the perinuclear zone and apical part of the cytoplasm. At the same time in the cytoplasm of A-II were detected multivesicular bodies, which are the group of vesicles covered by single membrane. There were lots of microvilli on the apical side of A-II. Some A-II had signs of increased functional activity. It was found a fusion of outer part of the LB membrane and inner part of the apical plasmalemma following relieve of the osmiophilic material in the alveolar space in these cells.

Inside the most haemocapillary of the alveolar wall it was defined the endothelial cells with ultrastructure typical for intact animals. It was not found the leukocytes and platelets clots in the haemocapillary space (Fig 2).

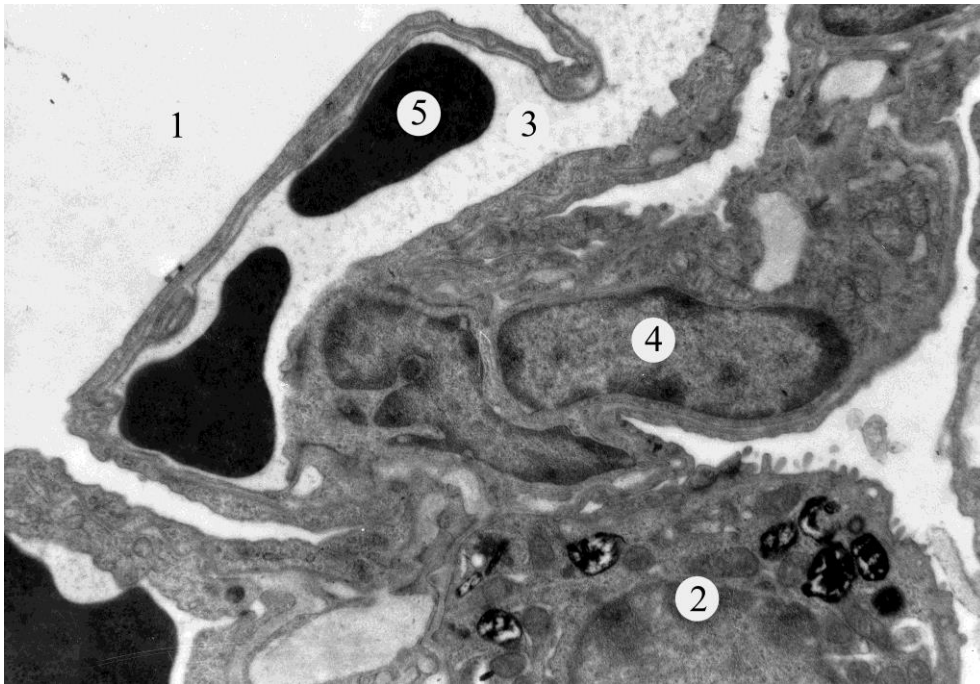


Fig. 2. Ultrastructural organization of the respiratory department of the lung during 6 hours after the beginning of the experiment on the background of Lipin administration.

1 – alveolar space; 2 – alveolar cell II type; 3 – haemocapillary space; 4 – fibroblast; 5 – red blood cell.

Microelectronic picture. x6400.

The ultrastructural findings during 24 hours after beginning of study on the background of Lipin treatment proved less manifested of damage as intracellular swelling with disorders of ultrastructural organization of organelles. We noticed that not just an expressiveness and prevalence of damages of the components of the respiratory lung department as well, were substantially less in the treated animals compared with not-treated ones. Lipin administration improves also rheological properties of blood. During this timeframe of the study platelets and leukocytes aggregation were found just in few haemocapillaries.

The results of electron microscopic study after 72-168 hours proved the absence of positive effect of Lipin® on the components of the respiratory department of lungs.

Our study has showed that intramedullary osteosynthesis of the femur fractures case the sustain ultrastructural changes of the alveolar cells I and II type, haemocapilari and alveolar macrophages. Intraperitoneal Lipin administration during first 24 hours after the beginning of the experiment is getting the decrease of expressiveness and prevalence of damages of the components of the respiratory lung department. Cell organelles are better saved on the background of Lipin administration due to different pathological conditions as phosphatidylcholine liposomes have properties restore damaged areas of the membrane because of lipid metabolism between liposomas and cell. The results of our study are consistent with the data of other researchers and proved membrane-protective effect of the Lipin [11, 13, 14].

Conclusion

1. Our study showed that intramedullary osteosynthesis taking due to multiple skeletal trauma cause significant disorders of submicroscopic structure of the respiratory department of the lungs.

2. The intraperitoneal Lipin administration helps to significantly reduce ultrastructural changes of cytoplasm organelles of the alveolar cells I and II type, haemocapillary endothelial cells and alveolar macrophages.

3. The efficacy of Lipin is the most significant during the early (first 24 h.) after beginning of the experiment.

REFERENCES

1. Alipbekova AS. Clinical and physiological aspects of the formation of «Shocked lung» (Literature review). *Medicine*. 2013; 9: 65–8. [in Russian]
2. Chen X, Song Y, Liu Z, Zhang J, Sun T. Ultrastructural lung pathology following brain injury combined with femur shaft fracture in a rat model. *Journal of Trauma and Acute Care Surgery*. 2015; 78(3): 558–64.

3. Dobryanskiy DO. The course of respiratory distress-syndrome in newborns treated with exogenous surfactant "alveofact". Ukrainian pulmonology journal. 2001; 1: 43-7. [in Ukrainian]
4. Gerasymchuk MR, Zayats LM. Ultrastructure of alveolar macrophages in experimental acute generalized peritonitis in the conditions of lipin correction. Galician medical journal. 2011; 18(1): 17-20. [in Ukrainian]
5. Horoshko OM. Effect of lipin as a basis of liposomal lipoflavon on the functional state of kidneys in rats under a model of pathology. Bukovinian Medical Herald Journal. 2014; 18(3): 49-52 [in Ukrainian]
6. Howard BM, Kornblith LZ, Hendrickson CM, Redick BJ, Conroy AS, Nelson MF et al. Differences in degree, differences in kind: characterizing lung injury in trauma. J. Trauma Acute Care Surg. 2015; 78(4): 735–41.
7. Khromov AS, Ivanova IV, Stefanov AV. Resolution with lipin of circulation heavy disturbances in animals with septic shock model. Medix. 2004; 3-4: 63-9. [in Ukrainian]
8. Kirillov Ju A, Dubrovskaja VF, Seiliev AA, Shulda AE, Loshakova LV, Danilov LN et al. Influence of bovine surfactant on development of bleomycin-induced rat lung disturbances. Pulmonology. 1998; 3: 51-5.[in Russian]
9. Matthay MA, Zemans RL. The acute respiratory distress syndrome: pathogenesis and treatment. Annu. Rev. Pathol. 2011; 28(6): 147-63.
10. Nebesna ZM, Volkov KS, Lisnychuk NYe, Demkiv IYa, Yavorska S. The efficacy of substitutive surfactant therapy for correction of oxidative stress manifestations in lung tissue after experimental thermal injury in dynamic. Medical and clinical chemistry. 2015; 17(2): 14-8. [in Ukrainian]
11. Yelsky VN, Kolesnikova SV, Bogatyreva EV. Effect of lipin on lipid peroxidation processes in various organs at crash-syndrome. Journal AMS of Ukraine. 1997; 3(4): 643-55. [in Ukrainian]
12. Yukhimets V, Steschka V. The influence inhalation of Lipin and its medicinal mixture with b₂-adrenomimetics on the condition of oxidation and structural-

functional homeostasis by the patients with bronchoobstructive diseases. Ukrainian pulmonology journal. 1996; 1: 24-9. [in Ukrainian]

13. Zagoruiko AK, Babanin AA, Potapov AL, Nesterov EN, Safronova LG. Pathogenetic proof of exogenous surfactant application in patients with acute lung injury syndrome. Ukrainian pulmonology journal. 2000; 2: 39-41. [in Ukrainian]

14. Zayats LM. Lipin influence on hemomicrocirculatory bed of the lungs under sulfur dioxide action. Reports of Vinnytsia national medical university. 2003; 7(2/2): 667-8. [in Ukrainian]

15.