

The journal has had 7 points in Ministry of Science and Higher Education parametric evaluation. Part b item 1223 (26/01/2017).

1223 Journal of Education, Health and Sport eissn 2391-8306 7

© The Authors 2018;

This article is published with open access at Licensee Open Journal Systems of Kazimierz Wielki University in Bydgoszcz, Poland

Open Access. This article is distributed under the terms of the Creative Commons Attribution Noncommercial License which permits any noncommercial use, distribution, and reproduction in any medium, provided the original author (s) and source are credited. This is an open access article licensed under the terms of the Creative Commons Attribution Non commercial license

(<http://creativecommons.org/licenses/by-nc/4.0/>) which permits unrestricted, non commercial use, distribution and reproduction in any medium, provided the work is properly cited.

This is an open access article licensed under the terms of the Creative Commons Attribution Non commercial License (<http://creativecommons.org/licenses/by-nc/4.0/>) which permits unrestricted, non commercial use, distribution and reproduction in any medium, provided the work is properly cited.

The authors declare that there is no conflict of interests regarding the publication of this paper.

Received: 05.03.2018. Revised: 10.03.2018. Accepted: 21.04.2018.

CAVERNOUS HEMANGIOMA OF THE KNEE - CASE REPORT

Marcin Weiss¹, Tomasz Dolata¹, Waldemar Weiss¹, Martyna Maksymiak²,
Krystian Kaluźny³, Anna Kaluźna³, Walery Żukow⁴, Magdalena Hagner-Derengowska⁵

- 1) **Ward of Orthopaedic and Traumatology with Center of Complex Treatment of Sports Injuries, Jan Biziel University Hospital No. 2 in Bydgoszcz**
- 2) **Jan Biziel University Hospital No. 2 in Bydgoszcz**
- 3) **Chair and Clinic of Rehabilitation, Faculty of Health Sciences, Nicolaus Copernicus University in Toruń, The Ludwik Rydygier Collegium Medicum in Bydgoszcz**
- 4) **Department of Spatial Management and Tourism, Faculty of Earth Sciences, Nicolaus Copernicus University in Toruń**
- 5) **Chair of Clinical Neuropsychology, Faculty of Health Sciences, Nicolaus Copernicus University in Toruń, The Ludwik Rydygier Collegium Medicum in Bydgoszcz**

Keywords: Cavernous hemangioma; Knee

Abstract:

Introduction: Cavernous hemangiomas are uncommon lesions and, as such, may enter the differential diagnosis of other lesions encountered more frequently in clinical practice, including pigmented villonodular synovitis and traumatic hemarthrosis.

Case report: A 21 year old single Polish woman who presented a non specific chronic knee

tumefaction secondary to cavernous angioma confirmed radiologically and histologically, with a quite good evolution after surgery.

Summation: Cavernous hemangioma of the knee is a frequently misdiagnosed lesion. MRI is the exploration of choice for this vascular tumor of the synovial membrane, although a pathology study is needed to confirm the diagnosis. Early surgical treatment with excision of the tumor within wide margins of uninvolved normal synovial tissue as partial or total synovectomy is the therapy of choice.

Introduction

Cavernous hemangioma of the synovium is an uncommon benign vascular tumor. It occurs in the knee more frequently than other joints [1–3]. This cavernous malformation has traditionally been considered to be congenital lesion. Familial occurrence has been reported and recently, a gene responsible for the autosome-dominant inheritance pattern with incomplete penetrance was mapped to human chromosome 7q11-21 [4]. Frequently is seen in infancy and childhood, described for the first time in 1856 by Bouchut. These vascular lesions are slowly growing. It is a rare cause of pain and spontaneous hemarthrosis, often seen as an internal derangement of the joint in children and young adults. The tumor is observed in two different forms: the synovial hemangioma or the arteriovenous malformation named also as hemangiohamartomas. They may cause hemorrhagic synovitis and arthropathy, probably as a result of recurrent episodes of intra-articular bleeding and mechanical irritation [5], they may be also relatively painless tumors [6].

Cavernous hemangioma may enter the differential diagnosis of other lesions encountered more frequently in clinical practice, including pigmented villonodular synovitis and traumatic hemarthrosis [7]. Magnetic resonance imaging is of a big contribution for diagnosing this lesion, which allows to put the diagnosis and to specify the extension of the hemangioma [1–3].

Different therapeutic strategies were proposed; injection of sclerosing fluids-various chemical sclerosants has been tried

but reports have not been encouraging. Some authors have preference, based on the experience of the usual types of cavernous hemangioma [8,9], for thermal sclerosis by the injection of boiling water [10].

Surgical excision is the ideal treatment in the pedunculated type. In the diffuse type it is difficult and the result is uncertain [11]. Successful results have been claimed after synovectomy [12].

Case report

A 21 year old single woman, student in University in Bydgoszcz, practicing no sport, with pathological history of the skin called skin hemangiomatoses of the left knee, consulted for persistent left knee pain and swelling. Several years previously she had pain and swelling in a similar location evolving by spontaneous episodes of pushes and forgiveness, with no history of trauma and was managed by symptomatic treatment. Physical examination found an afebrile patient with flexion of 60° of the left knee, intra-articular effusion without inflammatory signs. There was slight wasting of the thigh and calf. Laboratory tests, including a complete coagulation profile, an hemogram and a blood cholesterol were normal. Plain radiographs (Fig. 1) demonstrated diffuse articular plucking with subchondral geodes out of zones of hyperpressure. Echography of the knee showed isoechogenic mass with a posterior intensification and a venous signal inside. MRI (Fig. 2) revealed hyperplasia of the synovium especially within the sub quadricipital pouch which is the seat of images of high signal T1 and T2 fading on sequences FAT/SAT. Cavernous hemangioma of the knee was suspected. The patient underwent an arthroscopic synovial biopsy for diagnostic purposes; arthroscopic findings show a synovial lesion in the suprapatellar pouch embedded in synovium, the lesion takes the color of bright strawberry with moderate bloody effusion and the histological result objectified a cavernous hemangioma (Fig. 3). Our patient was operated for synovectomy, at operation, a diffuse cavernous hemangioma was found bulging into the suprapatellar pouch and holding the patella away from the femur. Since the operation the patient has been free from symptoms and no relapse was noted until last consultation.

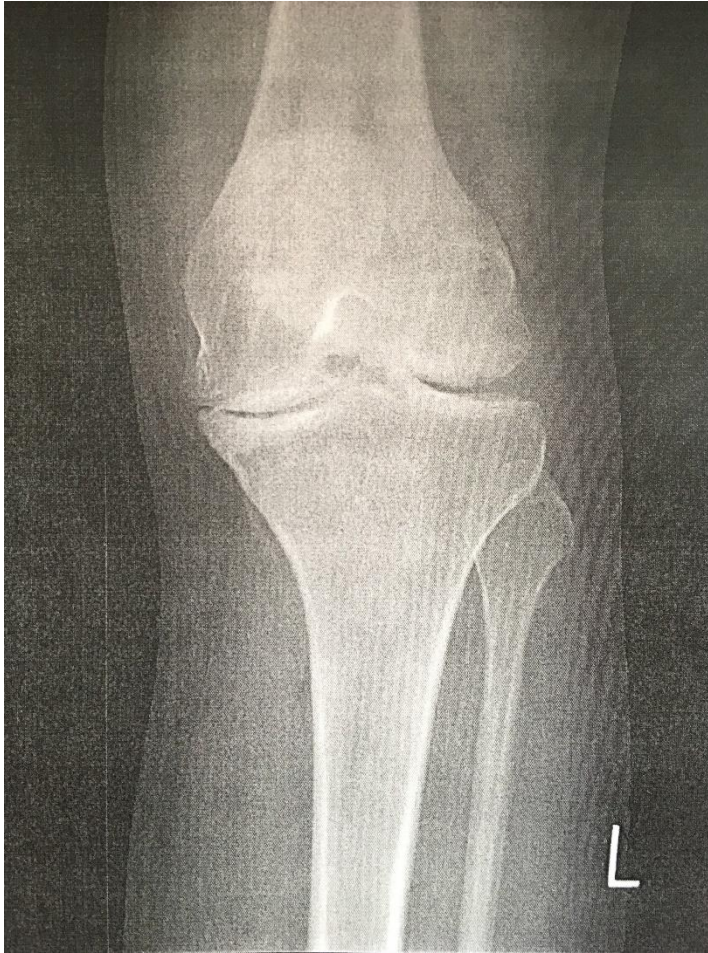

Figure 1

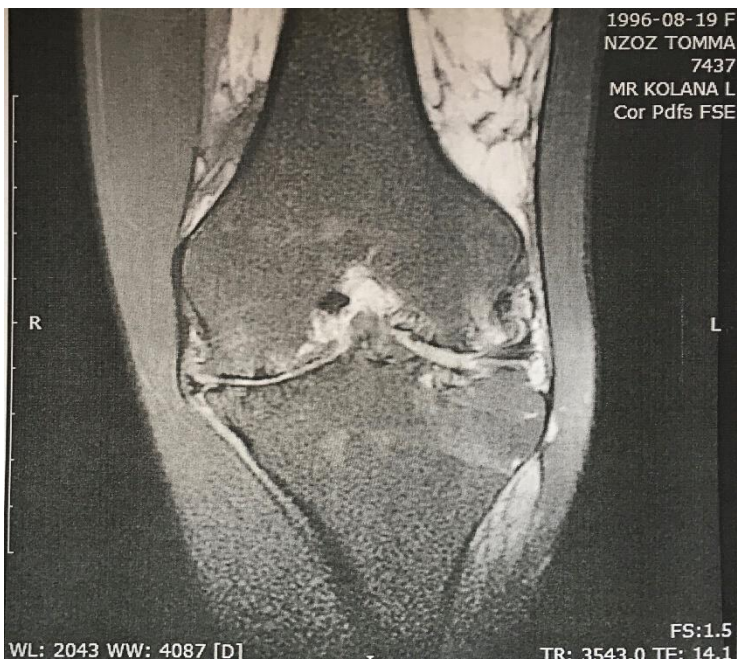


Figure 2

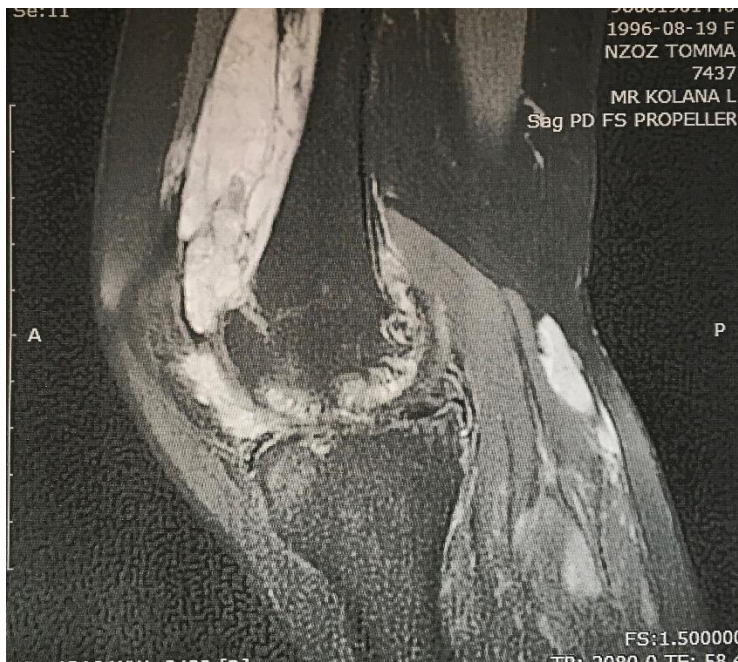

Figure 3

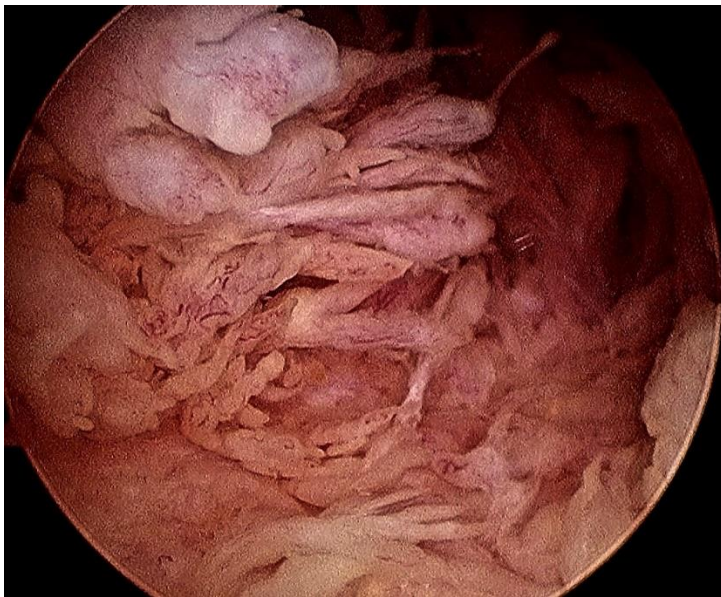

Figure 4

Discussion

Cavernous hemangiomas are benign, non infiltrative and low-flow. Synovial localization is rare, under 1% of all hemangiomas [6]. The localization in the knee, elbow, ankle, temporo-mandibular joint and tendons was described [6,7]. It affects in general children before 16 years, with a net feminine ascendancy [13,14].

It can also be seen in the adults and sometimes in an advanced age. According to its localization, it can be juxta articular; when it is localized out of the articular capsule; synovial

when it is intra capsular, on both sides of synovial in the intermediate forms; most of the cases are juxta articular or intermediate [6]. The classical presentation is not specific and insidious, which explains that synovial hemangiomas are frequently misdiagnosed leading to a diagnostic delay of many years especially in the extra articular forms [6]; there are even reports of delays of up to 20 and 40 years [15,16]. Usually, a patient presents in childhood with a history of recurrent atraumatic painful bloody knee effusions [17,18].

These recurrent spontaneous hemarthrosis of the knee joint and normal coagulation parameters should direct attention to the possibility of a synovial hemangioma [19].

The standard X-rays are often of poor diagnostic value because they are mostly normal, the sometimes found phléboliths is very suggestive, and the other not specific signs such as a thickening of mild parts, an osseous demineralization are described. In less than 5% of patients they show periosteal reaction, cortical destruction, osteoporosis, advanced maturation of the epiphyses and a discrepancy in leg length or even arthropathy simulating hemophilia [20].

Echography with Doppler is of a big contribution when it shows a signal of venous type within isoechogenic or hyperechogenic mass with a posterior intensification [1,6,21]. MRI is a useful non-invasive means of diagnosis and the current investigation of choice, these lesions are usually iso intense on T1-weighted images and high signal intensity of T2-weighted images. T2 sequences also show an increased vascularity in the area of the lesion with serpiginous structures corresponding to veins. Differential diagnosis on MRI includes villonodular synovitis, synovial osteochondromatosis, synovial sarcoma and the cystic hyperplasia of the synovial or lipoma aborescens usually being distinguished clinically or after MRI interpretation [6]. The utility of MRI in determining the distribution of abnormal tissue is crucial in the subsequent surgical planning and decision making process. The diagnosis of certainty is histological through the open synovial biopsy or under arthroscopy; it confirmed vascular malformation with a predominantly venous component. The presence of flat endothelium without any increase in cell turnover, helps to distinguish cavernous angioma from other lesions [1,2,6].

Angiography should be part of the diagnosis; it can define the size and location of the lesion and can identify feeder vessels or an associated arteriovenous malformation [22,17].

Synovial hemangiomas should be treated early because they can cause arthropathy, probably because of the recurrent episodes of intra-articular bleeding and they can even infiltrate muscles, fat and cortical bone [23,24].

Several therapeutic strategies were proposed in the past, including embolization, open surgery

or resection by arthroscopy, radiotherapy and sclerotherapy [16,23,25]. Some authors consider that arthroscopy is the gold standard in detecting and treating hemangioma of the knee [16].

In the localized forms, the surgical resection is the method of choice. However, in the diffuse forms open surgery for synovectomy is necessary to avoid recurrences [1,6].

Cavernous hemangioma is an uncommon lesion; synovial localization is rare which can affect mostly children before 16 years. Symptomatology is not specific and the evolution is insidious. Recurrent bloody effusions without a history of trauma should alert the practitioner to this diagnosis. It should also be considered in cases with nonspecific presentations and longstanding knee pain. The diagnosis is confirmed by MRI and synovial biopsy. In any event, treatment should be initiated as early as possible to reduce the risk of damage to the cartilage. Several treatment methods have been proposed and the treatment of choice in our opinion is essentially surgical resection with recurrence risk especially after localized resection.

References

- 1) Barakat MJ, Hirehal K, Hopkins JR, Gosal HS: Synovial hemangioma of the knee. *J Knee Surg*, 2007, 20(4):296-8.
- 2) Elliot AJ, Fulkerson JP: Skeletal muscle hemangioma: a cause of unexplained pain about the knee. *Arthroscopy*, 1989, 5(4):269-73.
- 3) Nasser K, Hayashi N, Kurosaki K, Hasegawa S, Kurimoto M, Mohammed A, Endo S: Intraosseous cavernous hemangioma of the frontal bone. *Neurol Med Chir*, 2007, 47(11):506-8.
- 4) Rosahl SK, Vorkapic P, Eghbal R, Ostertag H, Samii M: Ossified and de novo cavernous malformations in the same patient. *Clin Neurol Neurosurg*, 1998, 100(2):138-43.
- 5) Akgun I, Kesmezacar H, Ogut T, Dervişoğlu S: Intra-articular hemangioma of the knee. *Arthroscopy*, 2003, 19(3):E17.
- 6) Benameur M: Hemangiome synovial, cause rare de tumefaction du genou: imagerie et revue de la litterature. *Feuillets de Radiologie*, 2007, 47:244-8.
- 7) Devaney K, Vinh TN, Sweet DE: Synovial hemangioma: a report of 20 cases with differential diagnostic considerations. *Hum Pathol*, 1993, 24(7):737-45.

- 8) Cole PP, Hunt AH: The treatment of cavernous haemangiomas and cirosid aneurysms by the injection of boiling water. *Br J Surg*, 1949, 36(144):346-52.
- 9) Hunt A. Cavernous haemangioma of the knee joint: report of a case. *J Bone Joint Surg Br*, 1951, 33-B(1):106-7.
- 10) Wyeth JA. *J Am Med Assoc*, 1903, 40:1778.
- 11) Bennett GE, Cobey MC. *Arch Surg*, 1939, 38:487.
- 12) Harmon PH. *Arch Surg*, 1943, 47:359.
- 13) Gozal D, Soudry M, Arad P, Jaffe M, Boss JH: Arteriovenous haemangioma of the joint capsule of the knee in a child. *Eur J Pediatr*, 1988, 148:198-9.
- 14) Pinar H, Bozkurt M, Baktiroglu L, Karaoglan O: Intra-articular hemangioma of the knee with meniscal and bony attachment. *Arthroscopy*, 1997, 13:507-10.
- 15) Linson MA, Posner IP: Synovial hemangioma as a cause of recurrent knee effusions. *JAMA*, 1979, 242:2214-5.
- 16) Suh JT, Cheon SJ, Choi SJ: Synovial hemangioma of the knee. *Arthroscopy*, 2003, 19:1-4.
- 17) Durieux S, Brugieres P, Voisin MC, Goutallier D, Larget-Piet B, Chevalier X: Radiologic vignette. *Arthritis Rheum*, 1995, 38:559-64.
- 18) Winzenberg T, Ma D, Taplin P, Parker A, Jones G: Synovial hemangioma of the knee: a case report. *Clin Rheumatol*, 2006, 25:753-5.
- 19) Vakil-Adli A, Zandieh S, Hochreiter J, Huber M, Ritschl P: Synovial hemangioma of the knee joint in a 12-year-old boy: a case report. *J Med Case Rep*, 2010, 4:105.
- 20) Resnick D, Oliphant M. Hemophilia-like arthropathy of the knee associated with cutaneous and synovial hemangiomas. Report of 3 cases and review of the literature. *Radiology*, 1975, 114:323-6.
- 21) Huang TW, Lee SC, Chen JC, Hsu HH, Cheng YL: Cavernous hemangioma of the sternum. *Thorac Cardiovasc Surg*, 2008, 56(8): 500-1.
- 22) Akgün I, Kesmezacar H, Oğüt T, Dervişoğlu S: Intra-articular hemangioma of the knee. *Arthroscopy*, 2003, 19(3):E17.
- 23) Ramseier LE, Exner GU: Arthropathy of the knee joint caused by synovial hemangioma. *J Pediatr Orthop*, 2004, 24:83-6.
- 24) Moon NF: Synovial hemangioma of the knee joint. A review of previously reported cases and inclusion of two new cases. *Clin Orthop*, 1973, 90:183-90.
- 25) Price NJ, Cundy PJ: Synovial hemangioma of the knee. *J Pediatr Orthop*, 1997,17:74-7.