

Białkowska-Głowacka Jolanta, Pińkowska-Prasał Małgorzata, Osica Piotr, Janas-Naze Anna. The significance of performing the OPGs in the detection of dentigerous cyst and mesiodentes - a case report. Journal of Education, Health and Sport. 2017;7(11):129-140. eISSN 2391-8306. DOI <http://dx.doi.org/10.5281/zenodo.1044113>  
<http://ojs.ukw.edu.pl/index.php/johs/article/view/5020>  
<https://pbn.nauka.gov.pl/sedno-webapp/works/836807>

The journal has had 7 points in Ministry of Science and Higher Education parametric evaluation. Part B item 1223 (26.01.2017).

1223 Journal of Education, Health and Sport eISSN 2391-8306 7

© The Authors 2017;

This article is published with open access at Licensee Open Journal Systems of Kazimierz Wielki University in Bydgoszcz, Poland

Open Access. This article is distributed under the terms of the Creative Commons Attribution Noncommercial License which permits any noncommercial use, distribution, and reproduction in any medium, provided the original author(s) and source are credited. This is an open access article licensed under the terms of the Creative Commons Attribution Non Commercial License

(<http://creativecommons.org/licenses/by-nc/4.0/>) which permits unrestricted, non commercial use, distribution and reproduction in any medium, provided the work is properly cited.

This is an open access article licensed under the terms of the Creative Commons Attribution Non Commercial License (<http://creativecommons.org/licenses/by-nc/4.0/>) which permits unrestricted, non commercial use, distribution and reproduction in any medium, provided the work is properly cited.

The authors declare that there is no conflict of interests regarding the publication of this paper.

Received: 20.10.2017. Revised: 21.10.2017. Accepted: 09.11.2017.

## **THE SIGNIFICANCE OF PERFORMING THE OPGs IN THE DETECTION OF DENTIGEROUS CYST AND MESIODENTES- A CASE REPORT**

Jolanta Białkowska-Głowacka PhD, Małgorzata Pińkowska-Prasał Dr, Piotr Osica PhD, Anna Janas-Naze PhD Assoc. Prof.

Jolanta Białkowska- Głowacka ORCID ID:0000-0002-8453-3503,e-mail: j.bialglow@gmail.com

Małgorzata Pińkowska- Prasał ORCID ID:0000-0002-8235-1503

Piotr Osica ORCID ID:0000-0002-6436-5442

Anna Janas- Naze ORCID ID:0000-0001-6885-4457

**Department of the Oral Surgery, Central Clinical Hospital, Medical University of Lodz**  
**Head of the Department: Anna Janas- Naze, PhD, Assoc. Prof.**

Corresponding author: Jolanta Białkowska-Głowacka

Department of Oral Surgery, Medical University of Lodz

92-213 Łódź, ul. Pomorska 251, tel. 42 675 75 29

The article is financed by Medical University of Lodz as a part of statutory activity nr 503/2-163-01/503-01

## **Summary**

The article describes a case of a maxillary dentigerous cyst with mesiodens in a 60-year-old patient, which was discovered accidentally on an OPG.

**Key words:** dentigerous cyst, mesiodens, OPG

## **Introduction.**

A cyst is the most common pathologic lesion in the hard and soft tissues of the oral cavity. According to the Kramer's definition it is a loss of tissue filled with fluid, less often-semisolid material or gas [1]. In the maxillo-facial region different types of cysts can develop, such as cyst-like lesions or true cysts. The true cyst is a closed sac with distinct membrane that consists of epithelium and is usually filled with cholesterol crystals and fluid. Less common oral cavity cyst is a cyst-like lesion, which has a sac deriving from connective tissue, filled with fluid or semisolid material, however has no epithelium [1].

The basic classification of the cysts is strictly connected to the derivation of their epithelium.

A cyst is qualified as odontogenic, if the membrane derives from the rests of odontogenic epithelium. Non-odontogenic cysts derive from the ectoderm that participates in the development of maxillo-facial tissues. Among cysts of differentiated etiology, the dentigerous cysts can be found.

According to the pathogenesis, two types can be distinguished: developmental or of inflammatory origin [1].

Vast majority of dentigerous cyst cases concern lower third molar [5, 7], following the upper canines, lower premolars and upper third molars. Such location of dentigerous cysts is characteristic for developmental cyst in patients between the second and fourth decade of life [1].

The cyst of inflammatory origin predominates in children, in their first decade of life and its development is most often in the region of premolars. The dentigerous cyst is also exceptionally often developing in the region of central incisors and connected to the mesodentes. In almost 90% of cases, the mesiodentes are accompanied with dentigerous cyst [4, 5]. Most mesiodentes are located palatally to the central incisors [5], and their prevalence rate is around 0,15 to 1,9%. They are usually impacted, and characterized by male predilection [4].

Diagnosis of such cysts is based mainly on the radiological and clinical examination, due to highly non-specific image of epithelial stroma in the histopathological examination [2]. The aim of the study was to underline the significance of OPGs in the detection of asymptomatic pathological lesions of maxilla and mandible, usually cysts.

### **Case report**

The 60 years-old patient was admitted to the Department of Oral Surgery, Medical University of Lodz, due to surgical dental foci treatment and consultation of a lesion, visible on the OPG in the region of teeth 11-12, before the further planned prosthodontic treatment.

Medical history showed: undergone ischemic stroke, auricular fibrillation, surgery of abdominal aortic aneurysm and anticoagulation therapy. The extraoral examination did not reveal any disproportion in the facial features. The intraoral examination revealed complete crown destruction of teeth 22 and 23 due to caries and tooth 27 in second degree of mobility (fig. 1).

The performed OPG (fig. 2) showed the presence of radiolucency in maxilla, in the region of teeth 12-11 and impacted supernumerary tooth located just above the root of tooth 11 and partially overlapping it (fig. 3). Conical shape with short root observed in radiological picture indicated a mesiodens. Also resorption of teeth 11 and 12 was observed.

Basing on the clinical and radiological examination a diagnosis was made: suspicion of a dentigerous cyst in the region of teeth 12 and 11 and mesiodens. Surgical treatment was planned; the treatment plan and its consequences were described to the patient.

After obtaining the written consent from the patient and his GP, for performing the surgery in outpatient clinic and including the bridging therapy, oral cavity sanitation was performed, before the planned surgery of enucleating the cyst, apex of root 11 resection and mesiodens extraction. Patient was recommended to do a scaling, treat the cavities and perform endodontic treatment of teeth 11 and 12. Surgical extraction of fractured teeth 22 and 23, and tooth 27 was performed. Due to financial reasons patient declined the retreatment of tooth 12, which was qualified for extraction. Tooth 11 underwent endodontic treatment (fig. 4).

All odontogenic foci have been excluded.

In local anaesthesia with 2% Lignocaine, tooth 12 has been extracted (fig. 5), subsequently the flap has been cut from tooth 13 to 22 and prepared (fig. 6). The mesiodens located above the root of tooth 11 has been extracted (fig. 7) and resection of apex of tooth 11

performed.

The lesion has been enucleated and sent for histopathological examination. Bony edges were evened and the operating area was rinsed with 0,02% chlorhexidine solution. The wound was sutured (fig. 8). Antibiotic in the form of Dalacin C 0,3 - 1 tablet every 8 hours, was administered. Tooth 11, due to large loss of bone was preemptively excluded from occlusion. The sutures were removed after a week. The postoperative course was uneventful.

The result of histopathological lesion confirmed the initial diagnosis of dentigerous cyst.

The follow-up examination was carried out after 6 months, unfortunately patient declined performing an OPG due to financial reasons.

## **Discussion**

Cysts of oral cavity most often develop over long periods of time, without any pain [8, 9].

Small lesions, located in maxilla and mandible are usually discovered by accident, basing on a radiological examination, recommended to a patient for subsequent treatment planning.

In radiological image, cysts are usually visible as oval or round radiolucencies, sharply differentiated with prominent osteosclerotic rim.

In case of massive bony cysts, clinical examination shows asymmetry in facial features, painless distention of the alveolar process of the maxilla or alveolar part of the mandible, or translocation or loss of teeth. There is also the case of occasional crunch during palpation, which may suggest the presence of a cyst in maxillo-facial region, and performing a radiological examination confirms that, but in no way describes the type of the lesion [9, 10].

The most common additional examination in oral surgery performed before the surgery is the radiological examination. Proper interpretation of such image, allows to asses the general condition of the oral cavity and provides much additional information regarding the extensity and substance of the disease.

In some cases it allows the differential diagnosis.

The OPG is essential for planning the surgical treatment and very useful during surgery in maxillo-facial area. It is also used for comparing the progress of bone rebuilding after surgeries in maxilla and mandible. [8, 10].

In case of small cysts, the surgical treatment consists of enucleation of the lesion and sending the material for histopathological examination. Whereas in case of extensive lesions,

found by accident on the OPGs, the procedure is more complicated. For treating such lesions, the Drozdowski's method is used (a modified Partsch I method), where first part of treatment consists in excising a fragment of the lesion, initial histopathological verification, and performing an obturator [3, 6, 7, 8]. The acrylic obturator is used for diminishing the size of the lesion and greatly encourages the regeneration of the bone.

Second stage consists of enucleating the lesion, complete closure of the resulting wound and yet again sending material for histopathological examination. It is worth mentioning that this stage is performed in different timeframe, depending on patient's age, and moreover on the proper interpretation of the follow-up OPG.

In our patient, due to characteristic radiological image and relatively small range of the lesion, the surgery was performed according to the Partsch II method, with histopathological examination of the enucleated cyst with simultaneous extraction of the supernumerary tooth [6, 8, 9, 10].

It is worth mentioning that the described above case of dentigerous cyst concerns most often patients in the end of their second decade and third decade of life, and is usually connected to the state or tooth impaction.

In case of a dentigerous cyst with a mesiodens, in case of no visible symptoms, such as: delayed eruption of permanent teeth, their rotation, extensive diastema or edema in the region of central incisors, finding such lesion during intraoral examination is impossible. Such lesions can only be found basing on a radiological image [4, 5, 10].

It should be also pointed out that frequent performing of OPGs and resulting finding of impacted teeth prevents developing of maxillary and mandibular cysts, which is also true for impacted third molars [7]. Very important fact is, that the patient, being in his seventh decade of life, has been treated by prosthodontists and endodontists in the past, but without any OPG.

## References

1. Torbiele obszaru szczękowo-twarzowego pod red. Tomasza Kaczmarzyka Wydawnictwo Kwintesencja
2. AD Dinkar, AA Dawasaz, S Sheony : Dentigerous cyst associated with multipole mesiodens. A case report. Goa Dental College 2007,25,page 56-59
3. Milner P., Grzesiak - Janas G.: Przypadek dużej torbieli resztkowej żuchwy u 60 - letniego pacjenta., Med. Og. Nauk Zdr., 2014, 20 (1), s. 37 - 41.
4. Ji Asami, Y Shibata, Y Yanagi, M Hisatomi, H Matsuzaki, H Konouchi and K Kishi : Radiographic examination of mesiodens and their associated complications Dentomaxillofacial Radiology (2004) 33, 125–127
5. SB GROVER, P SINGH, VP VENKATACHALAM, N HEKHA Mesiodens Presenting As A Dentigerous Cyst: Case Report Ind J Radiol Imag 2005 15:1:69-72
6. Szczepkowska A., Lipczyńska M., Osica P., Janas – Naze A. Rozległa torbiel zapalna żuchwy u 6-letniej pacjentki - opis przypadku Journal of Education, Health and Sport. 2016;6(12):582-592
7. Is radiographic appearance a reliable indicator for the absence or presence of pathology in impacted third molars? Kaushal N  
Indian J Dent Res. 2012 Mar-Apr;23(2):298. Doi: 10.4103/0970-9290.100470.
8. Błochowiak K., Pluskota J., Grajewski S., Sokalski J: Rzadki przypadek olbrzymiej torbieli zębopochodnej żuchwy. Dental Forum, 2, 2013, XLI, 99-102
9. Pawlak W., Kubasiewicz-Ross P., Pałka Ł., Zarzycki R.: Torbiele kości szczęk leczone w Klinice Chirurgii Szczękowo-Twarzowej Akademii Medycznej we Wrocławiu w latach 2004-2007, Dent. Med. Probl., 2009, 1, 49-53
10. Puacz P., Kaczorowski M., Kaczmarek I., Osmola K.: Torbiel zawiązkowa kła górnego jako przyczyna zaburzeń zgryzu- opis przypadku 7-letniego chłopca. Developmental Period Medicine, 2013, VII, 1, 72-76

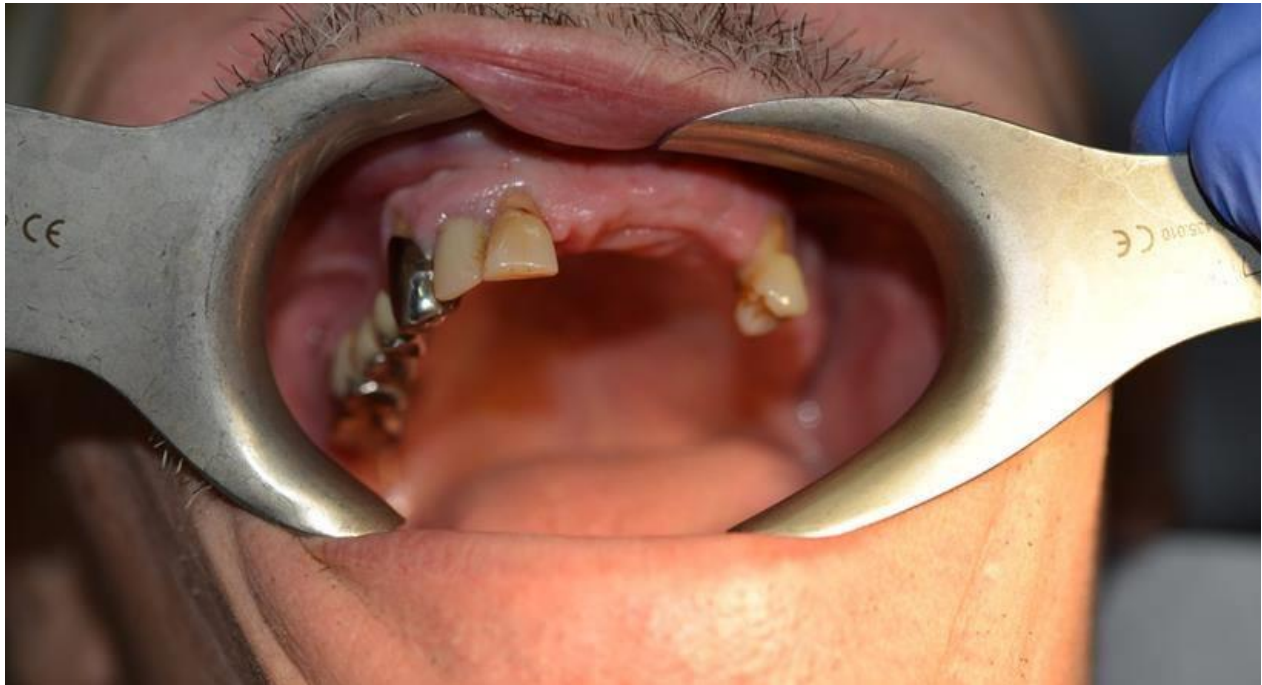

Fig. 1. Oral cavity condition before treatment.

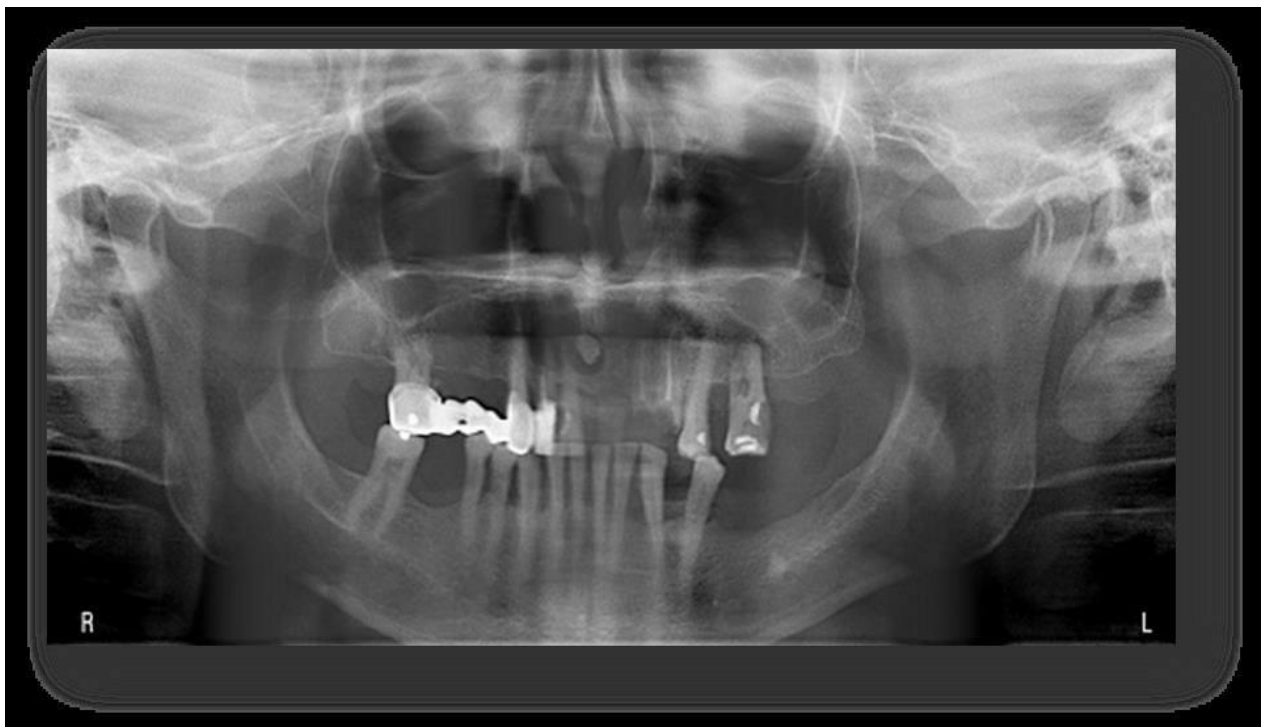


Fig. 2. Patient's OPG.



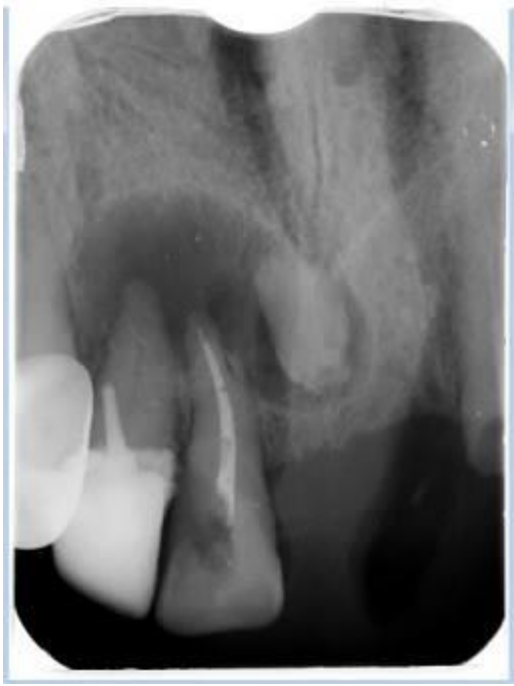

Fig. 3. Radiological image before the endodontic treatment of tooth 11.

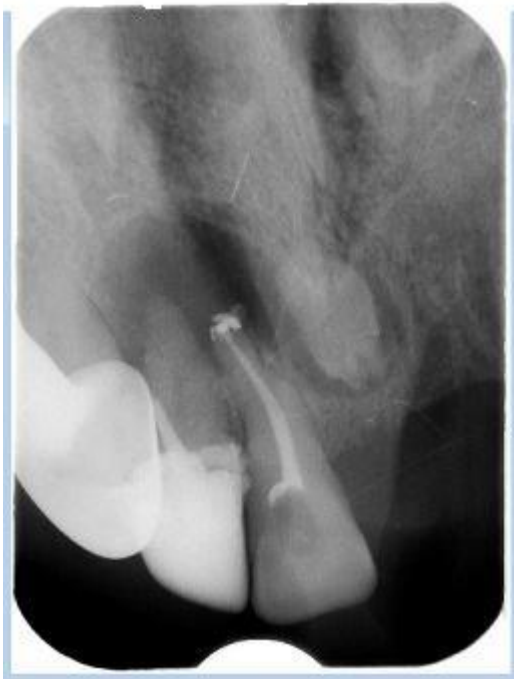

Fig. 4. Radiological image after the endodontic treatment of tooth 11.



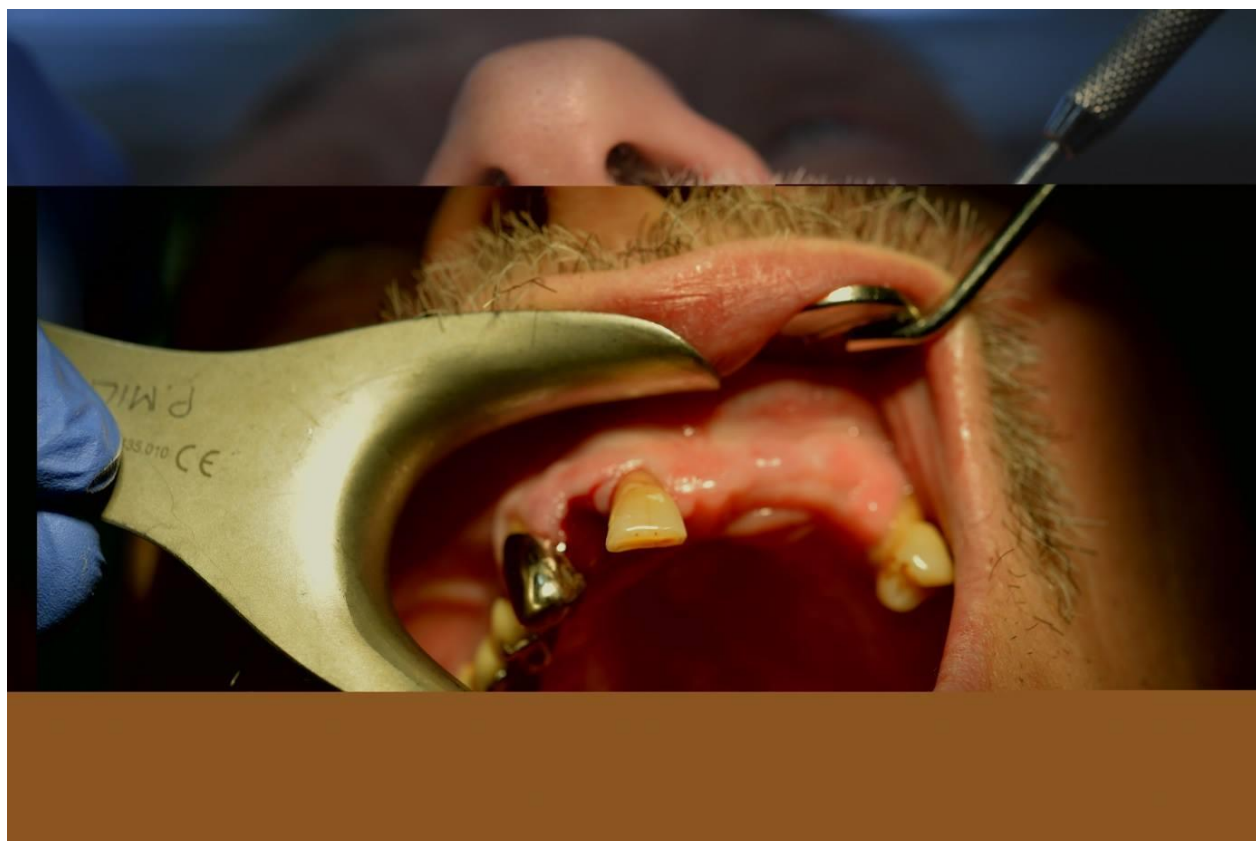


Fig. 5. After extraction of tooth 12.

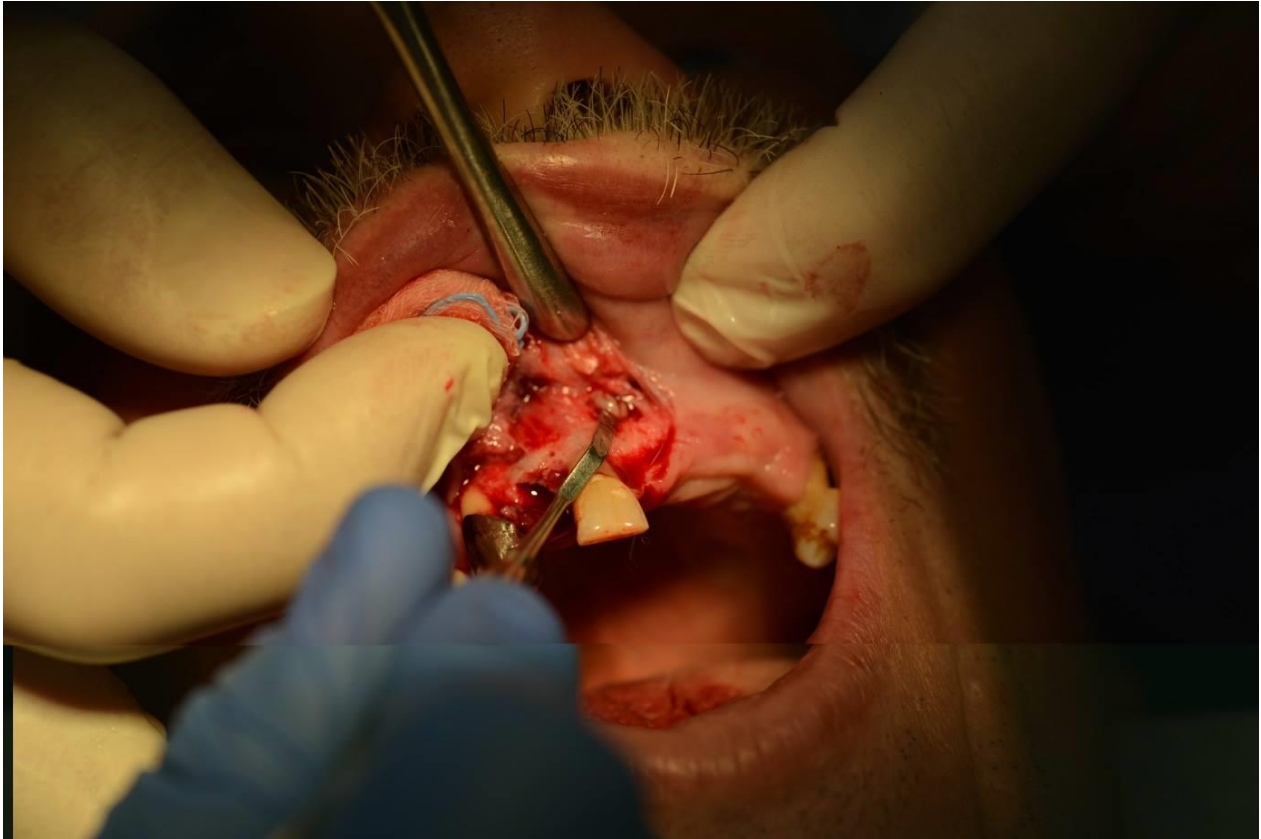


Fig. 6. Preparation of the mucoperiosteal flap.



Fig. 7. Mesiodens after extraction.

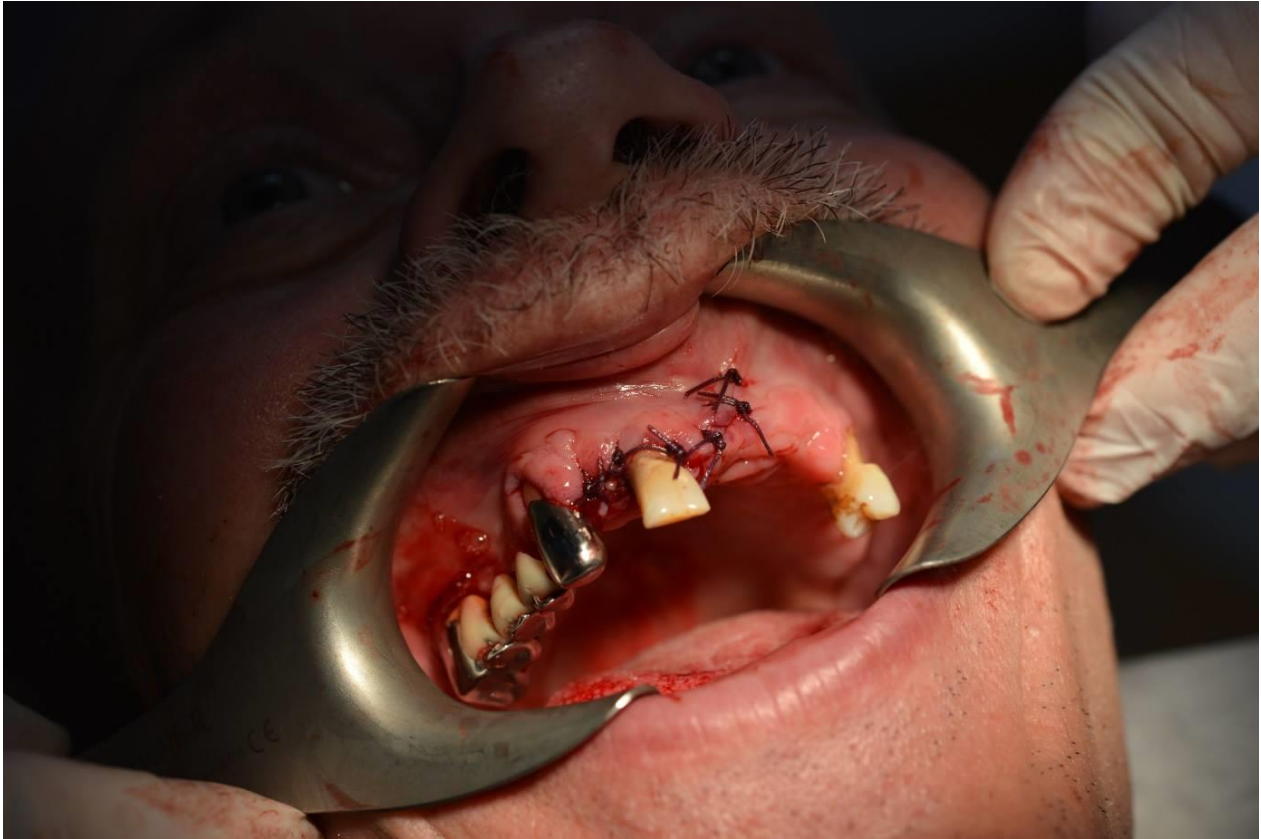

Fig. 8. Wound suturing.