

The journal has had 7 points in Ministry of Science and Higher Education parametric evaluation. Part B item 1223 (26.01.2017).

1223 Journal of Education, Health and Sport eISSN 2391-8306 7

© The Author (s) 2017;

This article is published with open access at Licensee Open Journal Systems of Kazimierz Wielki University in Bydgoszcz, Poland

Open Access. This article is distributed under the terms of the Creative Commons Attribution Noncommercial License which permits any noncommercial use, distribution, and reproduction in any medium,

provided the original author(s) and source are credited. This is an open access article licensed under the terms of the Creative Commons Attribution Non Commercial License

(<http://creativecommons.org/licenses/by-nc/4.0/>) which permits unrestricted, non commercial use, distribution and reproduction in any medium, provided the work is properly cited.

This is an open access article licensed under the terms of the Creative Commons Attribution Non Commercial License (<http://creativecommons.org/licenses/by-nc/4.0/>) which permits unrestricted, non commercial

use, distribution and reproduction in any medium, provided the work is properly cited.

The authors declare that there is no conflict of interests regarding the publication of this paper.

Received: 05.09.2017. Revised 10.09.2017. Accepted: 10.09.2017.

Hydronephrosis – a case report in a 88-year-old man

Grzegorz Wróbel¹

¹ Department of Anatomy, Faculty of Medicine and Health Sciences, Jan Kochanowski University, Kielce, Poland

Correspondence: Department of Anatomy, Faculty of Medicine and Health Sciences, Jan Kochanowski University, Al. IX Wieków Kielc 19A, 25-317 Kielce, Poland.

Tel: 413496965. E-mail: grzegorz.wrobel@ujk.edu.pl

Abstract

Hydronephrosis is a condition where urine overfills, or backs up, into the kidney, which causes the kidney to stretch (dilate), much like a balloon when it is filled with water. Hydronephrosis can be congenital or acquired (functional or anatomical). The aim of the study is to investigate the case of left kidney taken from human corpses (82-year-old man) with morphological changes corresponding to hydronephrosis. In the anatomical aspect, the

hydrogel formation process is as follows: above the obstruction in the ureters (e.g. stone or a tumour) the urinary tracts expand. Followed by impaired blood supply, kidney parenchyma disappears and kidneys transform themselves in a bag filled with urine. Causes are numerous. Various congenital deformities of the ureter may sooner or later produce back pressure. Kidney stones are a common cause. In older men, the continued growth of the prostate gland leads commonly to restricted urine flow out of the bladder. Prostate cancer, and cancer anywhere else along the urine pathways, can obstruct flow.

Keywords: kidney, hydronephrosis, anatomy

1. Introduction

Hydronephrosis disease is a complication of ailments that attacked the urinary tract, specifically the bladder, urethra or ureters. Symptoms include urinary retention in the kidney and appear when properly stored urine is produced in the kidney and cannot be completely expelled. As a result, the kidney is one-sided or two-sided and dangerous enlargement. Hydronephrosis most often has no symptoms and develops over a long period of time. Its detection occurs then accidentally [1]. In adults revealed hydronephrosis pain in the lumbar area, radiating along the ureter, which may be accompanied by loss of appetite, bloating and diarrhoea. Another symptom of the disease is present irregular urination from very frequent to rare or even anuria. They can also appear symptoms of renal colic – if the blockage caused the stones in the ureter. If there was a complete, double-blocked urinary tract - will appear anuria or oliguria. In people suffering from hydronephrosis may also occur a problem with hypertension [1-3].

2. Case presentation

The analyzed case concerns the left kidney taken from a human cadaver (82-year-old man) in the Department of Human Anatomy, Faculty of Medicine and Health Sciences, Jan Kochanowski University. After removal of organs performed washing and fixation in formalin (6%), subsequently the longitudinal exceeded. It has been observed smaller thickness of the renal parenchyma and increased renal pelvis and renal calyces (Figure 1 and 2).

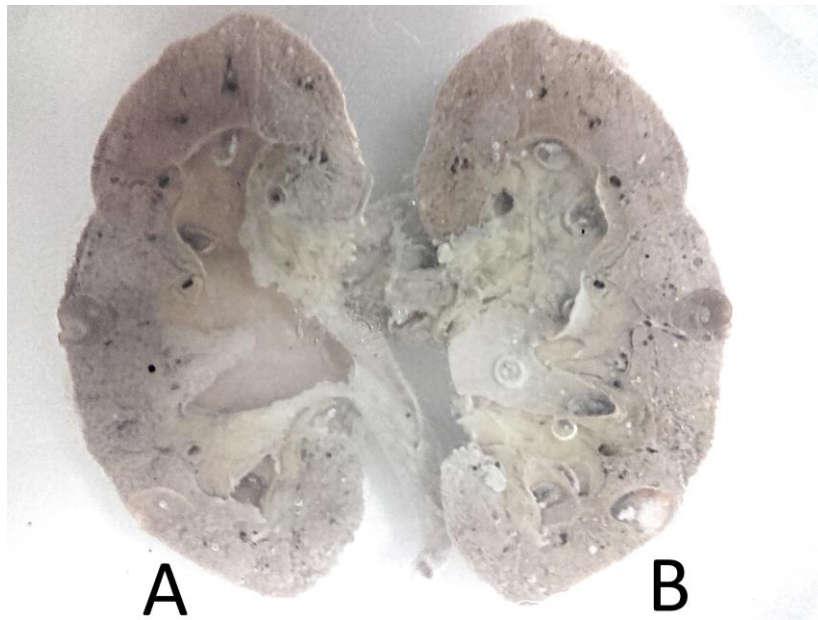


Figure 1. Left kidney cross section. A – front part, B – rear part.
(Photographed by Grzegorz Wróbel)

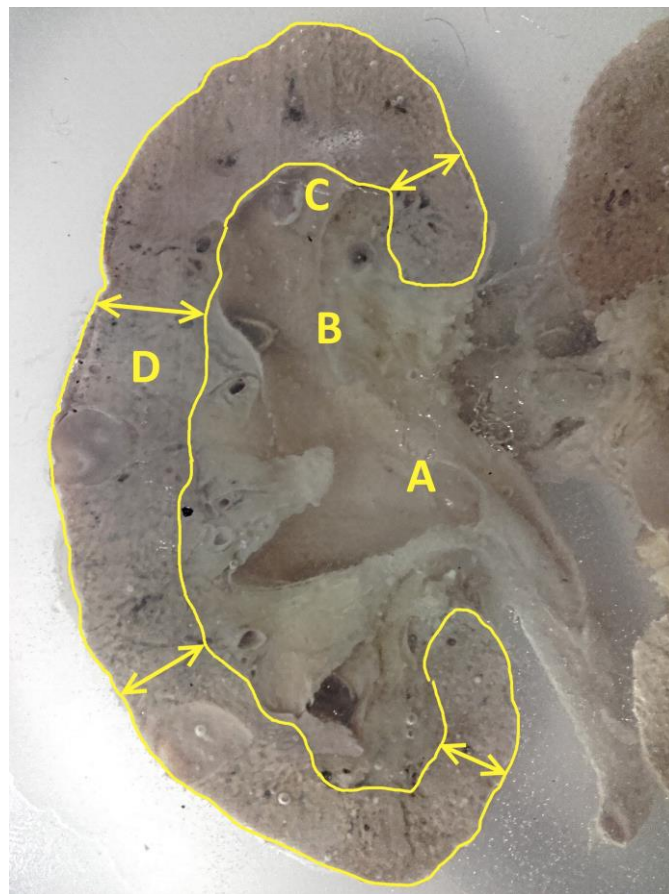


Figure 2. Left kidney cross section. A – Renal pelvis; B – Major calyx; C – Minor calyx; D – Renal parenchyma (reduced) (Photographed by Grzegorz Wróbel)

3. Discussion

Hydronephrosis it can be due to internal and external conditions that affect the kidney and the urinary collecting system. One of the most common of causes of hydronephrosis is acute unilateral obstructive uropathy. This is a sudden development of an obstruction in one of your ureters, which are the tubes that connect your kidneys to your bladder [4]. The most common cause for this blockage is a kidney stone, but scarring and blood clots can also cause acute unilateral obstructive uropathy [4, 5]. A blocked ureter can cause urine to go back up into the kidney, which causes swelling. Causes are numerous. The association between lower polar aberrant vessels and a dilated renal pelvis was appreciated and this, acting in the nature of a physical obstruction to the urine flow, seemed to provide a logical explanation for the condition and clearly displayed the relationship between hydronephrosis and an aberrant renal artery [6] Various congenital deformities of the ureter may sooner or later produce back pressure. Kidney stones are a common cause. In older men, the continued growth of the prostate gland leads commonly to restricted urine flow out of the bladder. Prostate cancer, and cancer anywhere else along the urine pathways, can obstruct flow [7-10].

4. Conclusion

Morphological image of kidney with hydronephrosis showed reduction of renal parenchymal thickness and enlargement of the renal pelvis and renal calyces.

5. References

1. Kumar, Vinay K.; Fausto, Nelson; Fausto, Nelso; Robbins, Stanley L.; Abbas, Abul K.; Cotran, Ramzi S. (2005). Robbins and Cotran Pathologic Basis of Disease (7th ed.). Philadelphia PA: Elsevier Saunders, 1012–4.
2. Tampo, Carol (2011). Fifth Edition: Diseases of the Human Body. Philadelphia, PA: F. A. Davis Company, 441.
3. Robins S. A., Fischmann J. (1948) Hydronephrosis; a radiologic classification based on anatomical variations. *Radiology*. 50 (5), 632-8. doi:10.1148/50.5.632
4. Sandberg J. M., Dyer R. B., Mirzazadeh M. (2017) A rare case report of hydronephrosis and acute kidney injury secondary to gonadal vein thrombosis in a young male, *Journal of Endourology* 3(1), 119–122, DOI: 10.1089/cren.2017.0063.
5. Alraies M. C., Kabach M., Shaheen K., Alraiyes A. H. (2013). Unilateral leg swelling and hydronephrosis. *QJM* 106, 681–683.
6. Park, B. S., Jeong, T. K., Ma, S. K., Kim, S. W., Kim, N. H., Choi, K. C., & Jeong, Y. Y. (2003). Hydronephrosis by an Aberrant Renal Artery: A Case Report. *The Korean Journal of Internal Medicine*, 18(1), 57–60. <http://doi.org/10.3904/kjim.2003.18.1.57>
7. Fitch W. P., Robinson J. R., Radwin H. W. (1976) Metastatic carcinoma of the ureter. *Arch Surg*. 111(8), 874–876.
8. Schneider S., Popp D., Denzinger S., Otto W. (2012). A rare location of metastasis

from prostate cancer: Hydronephrosis associated with ureteral metastasis. *Adv Urol*. 2012;656023. doi: 10.1155/2012/656023.

9. Zhang D., Li H., Gan W. (2016). Hydronephrosis associated with ureteral metastasis of prostate cancer: A rare case report. *Molecular and Clinical Oncology*, 4(4), 597–598. <http://doi.org/10.3892/mco.2016.775>
10. Turner B., Goldstraw E., Pati J., Green, J. (2013), Degarelix relieves hydronephrosis in a patient with prostate cancer: case study. *Int J Urol Nurs*, 7, 166–169. doi:10.1111/ijun.12009