

ŚWIERZ, Krzysztof, WACŁAWIK, Weronika, SZAFRANIEC, Julia, SZCZUREK, Katarzyna, SZCZEPANEK, Dawid, LEWONIUK, Natalia, BIESOK, Mateusz, SZWANCYBER, Julianna, MACHERSKI, Maksymilian and SZWINGE, Anna. Brachial neuralgic amyotrophy, a rare disease with serious diagnostic problems - case report. *Journal of Education, Health and Sport*. 2024;63:155-167. eISSN 2391-8306. <https://dx.doi.org/10.12775/JEHS.2024.63.012>
<https://apcz.umk.pl/JEHS/article/view/48500>
<https://zenodo.org/records/10700805>

The journal has had 40 points in Minister of Science and Higher Education of Poland parametric evaluation. Annex to the announcement of the Minister of Education and Science of 05.01.2024 No. 32318. Has a Journal's Unique Identifier: 201159. Scientific disciplines assigned: Physical culture sciences (Field of medical and health sciences); Health Sciences (Field of medical and health sciences). Punkty Ministerialne 40 punktów. Załącznik do komunikatu Ministra Nauki i Szkolnictwa Wyższego z dnia 05.01.2024 Lp. 32318. Posiada Unikatowy Identyfikator Czasopisma: 201159. Przypisane dyscypliny naukowe: Nauki o kulturze fizycznej (Dziedzina nauk medycznych i nauk o zdrowiu); Nauki o zdrowiu (Dziedzina nauk medycznych i nauk o zdrowiu).© The Authors 2024; This article is published with open access at Licensee Open Journal Systems of Nicolaus Copernicus University in Torun, Poland Open Access. This article is distributed under the terms of the Creative Commons Attribution Noncommercial License which permits any noncommercial use, distribution, and reproduction in any medium, provided the original author (s) and source are credited. This is an open access article licensed under the terms of the Creative Commons Attribution Non commercial license Share alike. (<http://creativecommons.org/licenses/by-nc-sa/4.0/>) which permits unrestricted, non commercial use, distribution and reproduction in any medium, provided the work is properly cited. The authors declare that there is no conflict of interests regarding the publication of this paper. Received: 02.02.2024. Revised: 15.02.2024. Accepted: 23.02.2024. Published: 24.02.2024.

Brachial neuralgic amyotrophy, a rare disease with serious diagnostic problems - case report

Krzysztof Świerz¹, Weronika Waclawik², Katarzyna Szczurek³, Dawid Szczepanek⁴, Julia Szafraniec⁵, Mateusz Biesok⁶, Julianna Szwancyber⁷, Maksymilian Macherski⁸, Natalia Lewoniuk⁹, Anna Szwinge¹⁰

Affiliations

- 1. St. Barbara Specialist Hospital no. 5 in Sosnowiec, Medyków Square 1, 41-200 Sosnowiec, <https://orcid.org/0009-0003-8040-8830>, krzysztofswierz1@gmail.com**
- 2. St. Barbara Specialist Hospital no. 5 in Sosnowiec, Medyków Square 1, 41-200 Sosnowiec, <https://orcid.org/0009-0003-9790-4670> weronika.waclawik98@gmail.com**
- 3. St. Barbara Specialist Hospital no. 5 in Sosnowiec, Medyków Square 1, 41-200 Sosnowiec, <https://orcid.org/0009-0001-7104-4436> katarzyna.szczurek@interia.eu**
- 4. St. Barbara Specialist Hospital no. 5 in Sosnowiec, Medyków Square 1, 41-200 Sosnowiec, <https://orcid.org/0009-0008-8704-8002>, szczepanekdawid@interia.pl**
- 5. National Medical Institute of the Ministry of the Interior and Administration in Warsaw, Wołoska 137, 02-507 Warsaw, <https://orcid.org/0009-0001-5427-2234> juliaszafraniec77@gmail.com**

6. Międzyleski Specialist Hospital in Warsaw, Bursztynowa 2, 04-749 Warsaw
<https://orcid.org/0009-0001-7117-3852>, biesmat77@gmail.com
7. District Hospital in Chrzanów, Topolowa 16, 32-500 Chrzanów
<https://orcid.org/0000-0001-8505-5219> szwancyber.j@gmail.com
8. Bonifrater Medical Center Branch in Katowice, Markiefki 87, 40-211 Katowice
<https://orcid.org/0009-0007-7185-3114>, machm@interia.pl
9. Międzyleski Specialist Hospital in Warsaw, Bursztynowa 2, 04-749 Warsaw
<https://orcid.org/0009-0006-5347-3014> , lewoniukn@gmail.com
10. Bonifrater Medical Center Branch in Katowice, Markiefki 87, 40-211 Katowice,
<https://orcid.org/0000-0001-5772-4059>, aniaszwinge@gmail.com

Abstract

Neuralgic amyotrophy(NA), is a rare and highly variable neurological disorder of unknown aetiology that causes serious diagnostic problems. We described a case of NA with atrophy of the brachialis muscle in order to enrich clinicians' knowledge about this disorder and to help them in the proper diagnosis of NA. A 21-year-old man presented with sudden, severe pain in the right biceps muscle. The man had consultations with several doctors and physiotherapists. Three magnetic resonance imaging (MRI) examinations, a nerve conduction study (NCS) and needle electromyography (EMG) were performed. Only after 6 months, based on medical history, physical examination and ultrasound imaging (USI), the physiotherapist suggested NA, which was later on confirmed by a neurologist. This case description of NA showed a variety of symptoms that made it difficult to establish an accurate diagnosis for a longer period of time. The diagnostic procedure, as well as the prolonged time between the onset of symptoms and diagnosis, indicates the need for further education of clinicians to better understand the symptoms of NA.

Keywords : neuralgic amyotrophy; brachialis amyotrophy; case report; magnetic resonance imaging; needle electromyography; nerve conduction study;

Introduction

Neuralgic amyotrophy (NA) is a rare and highly variable neurological disease of unknown aetiology that poses significant diagnostic challenges [1,2]. The overall incidence of NA is estimated at 1.64–3.00 cases per 100,000. However some authors have suggested that this rate may be underestimated due to serious diagnostic problems [1,3]. The disease affects men more often than women and most commonly occurs between 30 and 70 years of age, although cases have also been reported in children and the elderly [1,3-5]. The aetiology of this disorder is not completely understood, and the possible causes include immunological, environmental and genetic factors [1,6,7]. Autoimmune processes, viral infections (including SARS-CoV-2(severe acute respiratory syndrome coronavirus 2), bacterial infections and vaccination complications are indicated [7-11]. The environmental factors mainly include strenuous exercise and surgical procedures[1,7]. Some researchers suspect that individuals with NA have a genetic predisposition to develop the disease [1,12].

NA is characterised by the acute onset of severe pain localised to the shoulder girdle, arm or elbow, often radiating to the neck area and/or the entire upper limb. Severe pain, often exceeds a 7 on the 10-point Numeric Pain Rating Scale (NPRS) and typically lasts from days to weeks [6]. Over time, the pain subsides, but muscle weakness and atrophy develops in the muscles supplied by the various nerves of the shoulder plexus [1]. The clinical picture depends on the presence of single or multiple neuropathies [13]. The injury usually involves the suprascapular, axillary, long pectoral or musculocutaneous nerves [14]. Less frequently, damage occurs to the phrenic, recurrent laryngeal or intercostal nerves[13-15]. Muscle paresis and atrophy depend on the damaged nerve and most commonly affect the serratus anterior, supraspinatus, infraspinatus, deltoid, triceps, biceps, brachialis, wrist and finger extensors [14,15]. Sensory disturbances in the form of hypaesthesia, paraesthesia and allodynia accompany paralysis and muscle atrophy [16]. Typically, after an acute painful onset of NA, significant muscle atrophy develops, and then the paresis resolves within 2–3 or even up to 5 years [6,17]. In some patients, functional limitation, pain and fatigue persist even beyond this period [18].

Accurate and rapid diagnosis can be difficult for clinicians due to the heterogeneous nature of NA symptoms, large differences in symptom localization, incomplete understanding of the causes of this disease, and relatively rare occurrence. This article presents a chronological description of a patient's case suffering from severe pain in the elbow area with subsequent atrophy of the brachialis muscle, who for many months was unable to obtain the correct diagnosis and treatment. Upon deeper analysis, these symptoms led to the diagnosis of NA.

As these symptoms were atypical, we decided to present this clinical case to expand the knowledge of physicians and facilitate the correct diagnosis of NA.

Case Presentation

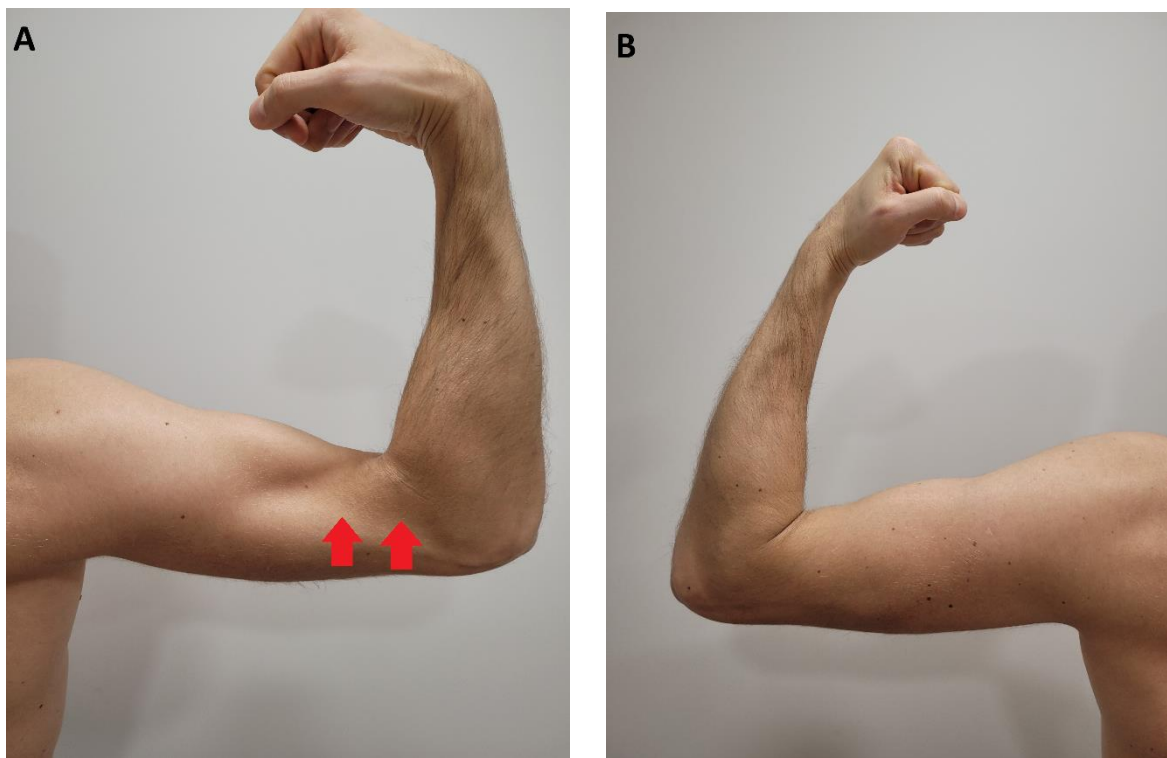
This case study presents a 21-year-old right-handed male. The man was previously healthy, with no chronic diseases, no history of genetic or inherited disorders in the family. In his history, the man reports that he leads an active lifestyle and exercises intensely at the gym in his spare time.

In March 2022, on the 5th of March to be exact, a few hours after waking up, the patient experienced a strong, pulsating, and scattered pain in the biceps muscle of their right arm. The man rated it an 8 on the NPRS scale. He reported that the pain was present at rest and intensified during movement of the limb. It was most intense in the position of arm inversion to 90 degrees and external rotation, during forearm supination, and when attempting to straighten the elbow joint combined with straightening at the radiocarpal joint. The pain was so severe that it practically hindered the execution of these movements. Additionally, the individual suffered from nausea and myoclonus of the right brachial and biceps muscles.

On the day the first symptoms appeared, the patient sought for a consultation with his primary care physician, who, based on the history, diagnosed exercise-related overload at the gym (the result of low electrolyte levels). The doctor prescribed nimesulide (Nimesil) at a dose of 100 mg for 5 days. After two doses, the patient did not experience any improvement. The next day, the patient experienced a reduction in the pain area (more punctual and located in the biceps brachii muscle insertion area). The patient also reported paraesthesia along the arm, forearm, and palmar part of the hand up to the thumb when touching the painful area, as well as positional tremor in the upper limb. After 5 days of prescribed medication, the pain subsided and the patient rated it as a 6 on the NPRS scale, but the paraesthesia and postural tremor persisted and the symptoms remained unchanged.

In April 2022, due to the persistent pain (6 on the NPRS scale) and a sense of increasing muscle weakness prompted the patient to consult a physiotherapist. The consultation took place on April 5, 2022, during which the physiotherapist diagnosed an overuse injury of the biceps muscle in the right upper limb and recommended the application of cold compresses for a duration of 5 days. Regrettably, these recommendations did not yield any positive therapeutic effects. The patient mentioned that only self-massage of the affected area of the upper limb resulted in temporary pain reduction to level 4 on the NPRS scale, which lasted up to 15 minutes.

On May 5, 2022, the man observed atrophy of the brachialis muscle in the right upper limb([Figure 1](#) and [Figure 2](#)). His pain was localised to the lateral side of the arm, near the insertion of the brachialis muscle and reduced to an NPRS score of 4. The concerning loss of muscle mass prompted the individual to seek advice from an orthopaedist. On July 25, 2020, following a medical history review and physical examination, the orthopaedic surgeon confirmed the atrophy of the brachioradialis muscle. Additionally, ultrasound imaging (USI) of the arm region showed no apparent abnormalities, as per the doctor's assessment. As the main diagnosis, the doctor indicated unspecified soft tissue diseases associated with their use, overload and overexertion. Pharmacological treatment was recommended: Cignon shots two times a day for 20 days (one 10 ml vial contains: chondroitin sulfate 415 mg; dry extract of long thistle root 100 mg; turmeric root powder equivalent 1200 mg; hydrolysed collagen 80 mg; hyaluronic acid 25 mg; zinc 1.5 mg; copper 0.15 mg), and Urazym twice a day for 15 days (enteral tablets contain: bromelain, papain, rutoside). Furthermore, the patient was advised to avoid full weight-bearing on the limb and, in case of no improvement, to consider extending the diagnostics with MRI Despite the recommended treatment, there was no observed therapeutic effect.



June 2022: Patient started using diclofenac ointment (Diclofenac lipogel 10 mg/g 4 times a day for 14 days) without consulting a doctor. . Each episode of high physical activity increased the pain, which then decreased the following day. After a training session at the gym, he again felt very intense pain similar to the pain from the initial attack. Pain severity was also rated as 8 on the NPRS scale. After a few days, the pain decreased to a score of 4 on the NPRS scale.

July 2022: On July 5, 2020, the man again visited an orthopaedic surgeon (a different surgeon from the first time), who suggested a rupture of the long head of the biceps brachii muscle and ordered an MRI scan of the right shoulder. On September 5, 2022 MRI scan, without contrast was performed.

August 2022: A follow-up consultation with an orthopaedic surgeon was conducted on August 5. The MRI examination did not confirm any fracture of the long head of the biceps brachii

Figure 2. Shoulder on (A) the right and (B) left sides. Significant atrophy of the brachialis muscle is seen on (A) the right side (Source: Personal)

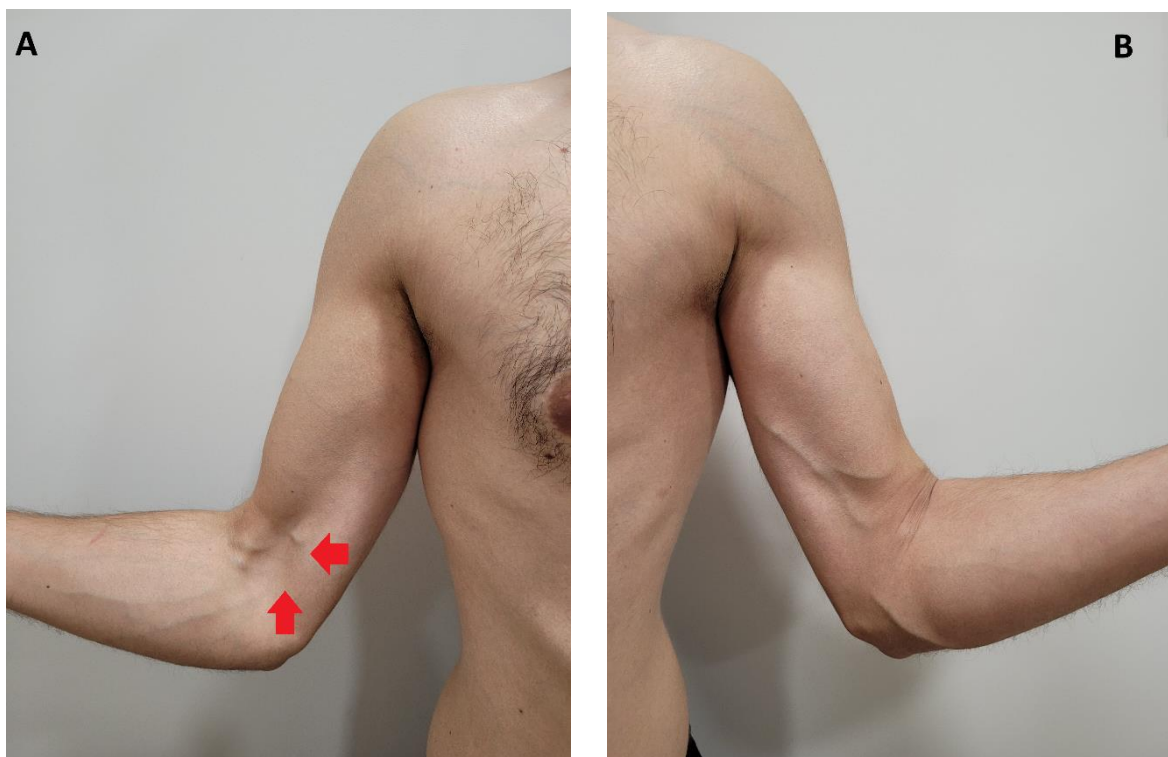

Figure 1. Shoulder on (A) right and (B) left sides. Significant atrophy of the brachialis muscle is seen on (A) the right side. (Source: Personal)

muscle. Later then, an orthopaedics suspected a tear of the brachialis muscle and ordered an MRI scan of the right elbow joint. An examination was performed on August 5, 2022, but no rupture of the brachialis muscle was confirmed, only showing diffuse swelling of the brachialis muscle, a volume reduction and the onset of fat infiltration (**Figure 3**).

During this period, the man rated his average pain as 3 on the NPRS scale, but there were occasional recurrences of more intense pain. Additionally, paraesthesia, manifested as tingling, numbness, and burning sensations, occurred in the palm. The MRI results did not lead to any clinical diagnosis.. The orthopaedic surgeon suggested injecting the area of the nerve with an anaesthetic to relieve the pain. The man did not consent to the proposed treatment, and the continued lack of diagnosis prompted him to see another orthopaedic doctor.

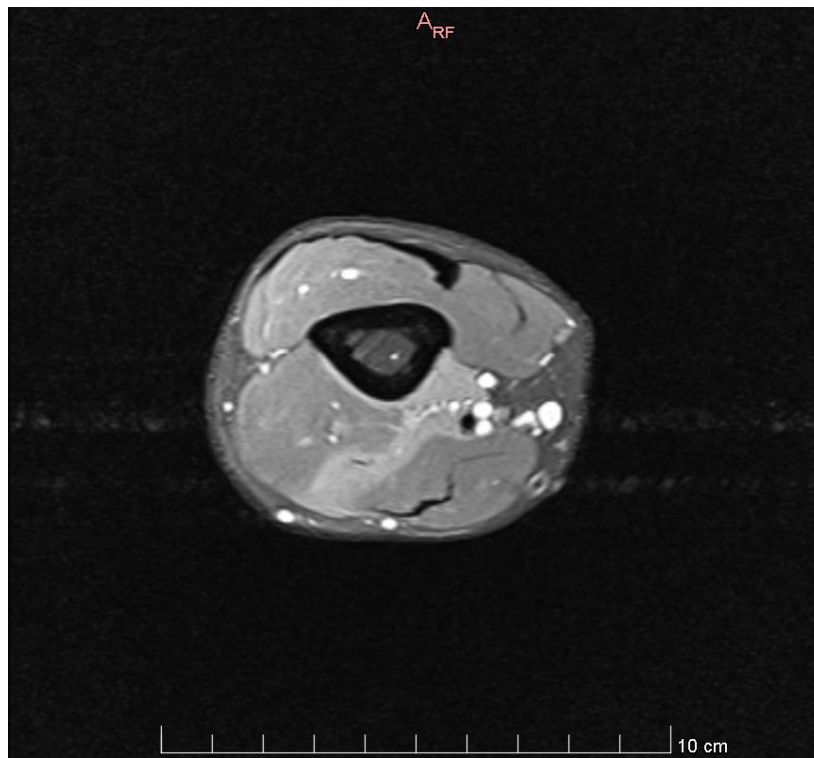


Figure 3. Edema of the brachial muscle, reduction of its volume and beginning of fat infiltration - transverse-section (Source: MRI of right elbow joint 05.08.2022)

On August 20, 2022, another orthopedic consultation took place. After gathering medical history, conducting a physical examination, and reviewing previous tests, the doctor ordered a magnetic resonance imaging of the cervical spine, electromyography (EMG), and nerve conduction study (NCS) ([Table 1](#)). All tests were promptly performed. An MRI, showed no abnormalities. The results of NCS and EMG indicated that the parameters of the conduction of the right ulnar nerve, both distally and proximally, were normal. The conduction of the musculocutaneous nerve to the biceps and brachialis muscles was within the normal range, and the conduction of the radial nerve to the triceps muscle was also normal. After analyzing the previously conducted tests and obtaining the ordered tests in the next visit, the doctor identified several potential causes for the symptoms (musculocutaneous nerve damage, thoracic outlet syndrome and cervical spine discopathy), but none of them were clearly pointed out. As the primary diagnosis, the doctor indicated mononeuropathy of the upper limb, unspecified.

The physician recommended physiotherapy, including massage of the scalenus and trapezius muscles, pectoralis minor, electrostimulation and exercises of the brachialis muscle, and stabilisation of the cervical spine and shoulder blades.

Table 1. Summary of EMG and NCS data

Stimulated points	Latency [ms]	Amplitude [mV]	Duration [ms]	Area [mV x ms]	Stimulation n	Stimulation n	Distance [mm]	Time [ms]	Velocity [m/s]
MCV									
Right, Musculus biceps brachii, nervus musculocutaneus, C5-C6									
Erb's point	4.3	14.1	6.2	43.3	60	0.1	250	-	-
Right, Musculus brachialis, nervus musculocutaneus, C5-C6									
1	5.0	14.5	10.5	37.2	60	0.1	240	-	-
Right, Musculus triceps brachii, nervus radialis, C6-Th1									
1	4.6	18.1	5.6	58.2	60	0.1	250	-	-
Right, Musculus abductor digiti minimi, nervus ulnaris, C8-Th1									
Wrist	2.5	7.0	6.45	20.9	50	0.1	55	-	-
Elbow	7.2	6.6	6.7	23.5	50	0.1	280	4.7	59.6
SCV									
Right, Nervus ulnaris V finger									
Wrist	1.9	14.8	1.8	6.1	21	0.1	100	1.9	52.6

[ms] – milisecond; [mV] – milivolt; [mA] – miliampere ; [mm] – milimetre ; [m/s] – metre per second

The lack of a precise diagnosis, persistent pain and progressive muscle atrophy prompted the man to continue looking for another clinician. He visited a physical therapist on August 29, 2022. Based on the history, functional examination, including sensory static two point discrimination examination in the innervation area of the musculocutaneous, USI examination of the right and left arm (revealing swelling of the musculocutaneous nerve and decreased thickness of the right brachialis muscle) and after analysis of the studies performed to date, NA was suggested.

September 2022: Less than a month after consulting with a physiotherapist, the patient sought a neurologist with all the results of previous tests. During the visit, the patient also mentioned the physiotherapist's suspicion that the cause could be NA. The neurologist ordered a biopsy of the brachial muscle, which the patient did not undergo. However, based on the patient's medical history, physical examination, and the tests conducted so far, the neurologist confirmed NA. He prescribed Nivalin intramuscularly for 10 days (1 ml contains 5 mg galantamine bromide) and Neurovit orally for 30 days (100 mg vitamin B1, 200 mg vitamin B6, 0.2 mg vitamin B12). Unfortunately, there was no improvement after treatment, so the patient decided to start physical therapy. After several therapy sessions of dynamic neuromobilization, the patient noticed an improvement, consisting of reduction of pain, paraesthesia, and the feeling of fatigue and discomfort, which previously appeared after intense physical activity.

3. Discussion

The main aim of this case report was to present a rare case of Neuralgic Amyotrophy (NA) involving musculoskeletal nerve and atrophy of the brachialis muscle. Accurate diagnosis poses a challenge for many physicians, as illustrated by the case of a young man with NA, where it took 7 months from the onset of symptoms to establish a diagnosis. This is likely due to the limited knowledge of many clinicians about NA [19,20]. Jerath and Mahajan highlighted that prompt diagnosis and appropriate treatment of NA are crucial to prevent neuropathy, muscle atrophy, and prolonged disability [21]. This is evident in the clinical case described in this article, as muscle atrophy in the upper limb is visible just one month after the onset of symptoms. Therefore, swift diagnosis and early intervention have a significant impact on the overall physical and mental health of NA patients.

The diagnosis of NA is primarily based on a clinical interview utilizing well-executed symptomatology, physical examination, and muscle examination [7, 21]. This can also be confirmed through clinical neurophysiological tests [22]. Unfortunately, insufficient knowledge about the fundamental symptoms and the disease spectrum leads to an excess of unnecessary tests, which are often costly and stressful for patients [19, 20]. This is also confirmed in this case, the man underwent three MRI scans (shoulder, elbow and cervical spine), two USI examinations, a nerve conduction study, electromyography and had a histopathological examination of the affected muscle ordered, which he ultimately did not undergo. Some researchers believe that MRI of the shoulder girdle region is not very sensitive in the diagnosis of NA [23].

However, Gstoettner et al. [7] stated that imaging peripheral nerves using MRI expands the diagnostic capabilities of NA. Nevertheless, in the described case, the triple MRI examination did not lead to an accurate diagnosis.

Duman et al. highlight the effectiveness of magnetic resonance neurography (MRN) in diagnosing NA[28]. The authors emphasize that MRN should be the preferred imaging method in the diagnosis of acute PTS and can prevent unnecessary tests that do not contribute to the diagnosis of this condition [28]. Unfortunately, a limitation of MRN is that it is not commonly used, and in the described case, this examination was not finalized.

Although NCS is often referred to as the "gold standard" in peripheral neuropathy diagnosis [26], nerve conduction parameters in NA may fall within the normal range, limiting the sensitivity of this technique [20]. This is confirmed by the case described here, where nerve conduction parameters did not deviate from the norm. Feinberg emphasizes that EMG is a useful but invasive test for detecting and confirming muscle denervation [25] However, there is a period (the first weeks after injury) in which changes will not be visible [25]. Unfortunately, in the case described here, no abnormalities were found in the EMG (**Table 1**), even though this examination was also conducted 6 months after the onset of the initial symptoms. In the available literature, no information was found regarding the sensitivity of histopathological examination in the diagnosis of NA. Unfortunately, this test was not conducted in the described case, making it difficult to assess its diagnostic value.

NA is often misdiagnosed as tension muscle pain, traumatic nerve injury, tumour compression, cervical radiculopathy, neurogenic thoracic outlet syndrome, cervical spondylosis, rotator cuff damage, compression neuropathy and many other conditions [2,7,19]. In the described case, one of the doctors made several diagnoses suggesting the possibility of cervical discopathy, thoracic outlet syndrome or musculocutaneous nerve injury, but unfortunately, the correct diagnosis was not established. Recognition tension-type pain should not be a problem since it rarely appears suddenly or reaches a very high level of pain. Thoracic outlet syndrome can be ruled out based on functional and imaging studies[30]. In cervical radiculopathy, unlike NA, symptoms are consistent with the innervation of nerve roots. In contrast, Rotator cuff muscle damage can be diagnosed using functional tests, MRI, and ultrasound [7]. Cervical spondylosis less frequently causes radiating pain to the limbs and is relatively easy to eliminate [7,29]. Tumour compression can be differentiated using MRI [7].

The described case of a patient with NA, who remained undiagnosed for six months despite repeated visits to specialists and a series of investigations, highlights the need to spread awareness of the disease across medical specialities.

The study of van Alfen et al. [30] demonstrated that after specialized training of primary care physicians, the incidence of NA increased to 1/1000 cases, which is 30–100 times higher than reported by previous studies [1,3,30]. Most likely, the main challenges in the diagnosis of NA are high variability and heterogeneity of symptoms and their localisation, the lack of specific diagnostic tools and the limited knowledge among many doctors about this disease.

4. Conclusions

This NA case report reveals diverse symptoms that have long made an accurate diagnosis difficult. The diagnosis was finally made seven months later. This case underscored the crucial role of a thorough physical examination in recognizing NA. No abnormalities were detected in the NCS examination, while changes in the musculocutaneous nerve were identified in the ultrasound examination. The diagnostic procedures and the prolonged time between symptom onset and diagnosis indicate the need for further training of physicians to better understand NA symptoms.

Author Contributions : Methodology, W.W. and J.S.; investigation, K.S. and D.S.; conceptualization, A.S.; writing – review and editing, M.B and N.L.; writing – rough preparation, K.Ś. and M.M.; supervision, J.Sz.. All authors read and agreed to the published version of the manuscript.

Funding Statement: This research received no external funding.

Institutional Review Board Statement: Not applicable.

Informed Consent Statement: informed consent was obtained from all subjects involved in the study.

Data Availability Statement: Not applicable

Conflict of Interest Statement: The authors declare no conflict of interest.

References

- 1 van Alfen N, van Engelen BG. The clinical spectrum of neuralgic amyotrophy in 246 cases. *Brain*. 2006;129(Pt 2):438-50. [[PubMed](#)]
- 2 Kwolek A, Majka-Sibiga M, Zwolińska J, Korab D. Parsonage-Turner syndrome (neuralgic amyotrophy) – case report. *Medical Review of the University of Rzeszów, Rzeszów* 2006, 3, 223–226. [[link](#)]
- 3 Sathasivam S, Lecky B, Manohar R, Selvan A. Neuralgic amyotrophy. *J Bone Joint Surg Br*. 2008;90(5):550-3. . [[PubMed](#)]
- 4 Tsairis P, Dyck PJ, Mulder DW. Natural history of brachial plexus neuropathy: report on 99 patients. *Arch Neurol* 1972;27:109-17. [[PubMed](#)]

- 5 Gaskin CM, Helms CA. Parsonage-Turner syndrome: MR imaging findings and clinical information of 27 patients. *Radiology* 2006;240:501-7. [[PubMed](#)]
- 6 Gupta A, Winalski CS, Sundaram M. Neuralgic amyotrophy (Parsonage Turner syndrome). *Orthopedics*. 2014;37(2):75, 130-33. [[PubMed](#)]
- 7 Gstoettner C, Mayer JA, Rassam S, Hraby SA et al. Neuralgic amyotrophy: a paradigm shift in diagnosis and treatment. *J Neurol Neurosurg Psychiatry* 2020;0:1–10. [[PubMed](#)]
- 8 Debeer P, De Munter P, Bruyninckx F, Devlieger R. Brachial plexus neuritis following HPV vaccination. *Vaccine*. 2008; 26(35):4417-4419. [[PubMed](#)]
- 9 Pellas F, Olivares JP, Zandotti C, Delarque A. Neuralgic amyotrophy after parvovirus B19 infection. *Lancet*. 1993; 342(8869):503-504.[[PubMed](#)]
- 10 Suarez GA, Giannini C, Bosch EP, et al. Immune brachial plexus neuropathy: suggestive evidence for an inflammatory immune pathogenesis. *Neurology*. 1996; 46(2):559-561. [[PubMed](#)]
- 11 Mitry M, Collins LK, Kazam JJ, Kaicker S, Kovanlikaya A. Parsonage-turner syndrome associated with SARS-CoV2 (COVID-19) infection. *Clin Imaging*. 2021;72:8-10.[[PubMed](#)]
- 12 Kuhlenbäumer G, Hannibal MC, Nelis E, et al. Mutations in SEPT9 cause hereditary neuralgic amyotrophy. *Nat Genet* 2005;37:1044–6. [[nature](#)]
- 13 Sallem F, Mozaffar T. Neuralgic Amyotrophy (Parsonage-Turner Syndrome): An Often Misdiagnosed Diagnosis. *J Pak Med Assoc*. 1999;49(4):101-3.[[PubMed](#)]
- 14 Drozdowski W., Baniukiewicz E., Acquired polyneuropathies: aetiology, diagnosis, therapy [in:] Parsonage -Turner syndrome. *Medicine after graduation, Special issue. Training conference 2002*: 76.
- 15 Ishizuka K, Shikino K, Ikusaka M. Anterior interosseous nerve palsy caused by Parsonage-Turner syndrome. *Cleve Clin J Med*. 2021;88(3):155-156.[[PubMed](#)]
- 16 Tomczykiewicz K, Stępień A, Staszewski J. Personage-Turner syndrome – case report. *Pol. Merkur. Lekarski*, 2011, 100-102. [[PubMed](#)]
- 17 Misamore GW, Lehman DE, Parsonage-Turner syndrome (acute brachial neuritis), *J Bone Joint Surg Am* 1996,78(9): 1405. [[PubMed](#)]
- 18 van Alfen N, van der Werf SP, van Engelen BG. Long-term pain, fatigue, and impairment in neuralgic amyotrophy. *Arch Phys Med Rehabil*. 2009; 90(3):435-439. [[PubMed](#)]

- 19 Pessa ME, Verriello L, Valente M, Gigli GL. A rare case of pure sensitive Parsonage-Turner syndrome. *Neurol Sci.* 2019 Jul;40(7):1499-1501.[[PubMed](#)]
- 20 Van Eijk JJJ, Groothuis JT, Van Alfen N. Neuralgic amyotrophy: an update on diagnosis, pathophysiology, and treatment: neuralgic amyotrophy update. *Muscle Nerve* 2016;53:337–50.[[PubMed](#)]
- 21 Jerath VP, Mahajan VK. Parsonage-Turner syndrome: a firsthand experience of an uncommon malady. *Am J Neurodegener Dis.* 2021;10(4):34-37.[[PubMed](#)]
- 22 Rix GD, Rothman EH, Robinson A. Idiopathic neuralgic amyotrophy: an illustrative case report. *Journal of Manipulative and Physiological Therapeutics* 2006;29(1):52–9.[[PubMed](#)]
- 23 Dill-Macky MJ, Song S, Silbert PL. Magnetic resonance imaging features of subacute idiopathic brachial neuritis. *Australas Radiol.* 2000;44:98– 100.[[PubMed](#)]
- 24 Lieba-Samal D, Jengojan S, Kasprian G, et al. Neuroimaging of classic neuralgic amyotrophy: imaging of neuralgic amyotrophy. *Muscle Nerve* 2016;54:1079–85.[[PubMed](#)]
- 25 Feinberg J. Emg: myths and facts. *Hss J* 2006;2:19–21.[[PubMedCentral](#)]
- 26 Johnson EW. Diagnosis of carpal tunnel syndrome. The gold standard. *Am J Phys Med Rehabil.* 1993;72(1):1.[[PubMed](#)]
- 27 Duman I, Guvenc I, Kalyon TA. Neuralgic amyotrophy, diagnosed with magnetic resonance neurography in acute stage: a case report and review of the literature. *Neurologist.* 2007;13(4):219-21.[[PubMed](#)]
- 28 Mamula C, Erhard RE, Piva SR. Cervical Radiculopathy or Parsonage-Turner Syndrome: Differential Diagnosis of a Patient With Neck and Upper Extremity Symptoms. *J Orthop Sports Phys Ther.* 2005;35(10):659-64.[[PubMed](#)]
- 29 Sanders RJ, Hammond SL, Rao NM. Diagnosis of thoracic outlet syndrome. *J Vasc Surg* 2007;46:601–4.[[PubMed](#)]
- 30 van Alfen N, van Eijk JJJ, Ennik T, et al. Incidence of Neuralgic Amyotrophy (Parsonage Turner Syndrome) in a Primary Care Setting - A Prospective Cohort Study. Sommer C, ed. *Plos One* 2015;10:e0128361.[[PubMed](#)]
- 31 MacDonald BK, Cockerell OC, Sander JW, et al. The incidence and lifetime prevalence of neurological disorders in a prospective community-based study in the UK. *Brain J Neurol* 2000;123:665–76.[[PubMed](#)]