

BIELAK, Maciej, BIELAK, Ryszard, KĘDRA, Kamila, MICHALIK, Izabela, ZARAŃSKA, Julia, AAB, Arkadiusz and BIELAK, Karolina. Congenital Pseudoarthrosis of the Clavicle Joint and its impact on sports participation – Description of 2 Cases: diagnosis and treatment. *Journal of Education, Health and Sport*. 2023;21(1):123-134. eISSN 2391-8306. DOI <http://dx.doi.org/10.12775/JEHS.2023.21.01.013> <https://apcz.umk.pl/JEHS/article/view/46100> <https://zenodo.org/record/8400782>

The journal has had 40 points in Ministry of Education and Science of Poland parametric evaluation. Annex to the announcement of the Minister of Education and Science of 17.07.2023 No. 32318. Has a Journal's Unique Identifier: 201159. Scientific disciplines assigned: Physical Culture Sciences (Field of Medical sciences and health sciences); Health Sciences (Field of Medical Sciences and Health Sciences). Punkty Ministerialne z 2019 - aktualny rok 40 punktów. Załącznik do komunikatu Ministra Edukacji i Nauki z dnia 17.07.2023 Lp. 32318. Posiada Unikatowy Identyfikator Czasopisma: 201159. Przynależność dyscypliny naukowej: Nauki o kulturze fizycznej (Dziedzina nauk medycznych i nauk o zdrowiu); Nauki o zdrowiu (Dziedzina nauk medycznych i nauk o zdrowiu).

© The Authors 2023;

This article is published with open access at License Open Journal Systems of Nicolaus Copernicus University in Torun, Poland

Open Access. This article is distributed under the terms of the Creative Commons Attribution Noncommercial License which permits any noncommercial use, distribution, and reproduction in any medium, provided the original author (s) and source are credited. This is an open access article licensed under the terms of the Creative Commons Attribution Non commercial license Share alike. (<http://creativecommons.org/licenses/by-nc-sa/4.0/>) which permits unrestricted, non commercial use, distribution and reproduction in any medium, provided the work is properly cited.

The authors declare that there is no conflict of interests regarding the publication of this paper.

Received: 28.08.2023. Revised: 15.09.2023. Accepted: 02.10.2023. Published: 03.10.2023.

## **Congenital Pseudoarthrosis of the Clavicle Joint and its impact on sports participation – Description of 2 Cases: diagnosis and treatment**

Maciej BIELAK<sup>1</sup>, Ryszard BIELAK<sup>2</sup>, Kamila KĘDRA<sup>1</sup>, Izabela MICHALIK<sup>1</sup>, Julia ZARAŃSKA<sup>1</sup>, Arkadiusz AAB<sup>1</sup>, Karolina BIELAK<sup>3</sup>

<sup>1</sup> Institute of Medical Sciences, Medical College of Rzeszow University, 35-055 Rzeszów, Poland

<sup>2</sup> NZOZ Ortopeda, ul. Kopisto 8b/512, 35-315 Rzeszów, Poland

<sup>3</sup> Wrocław Medical University, 50-367 Wrocław, Poland

### **Abstract**

Congenital Pseudoarthrosis of the Clavicle (CPC) is a rare condition stemming from incomplete clavicular ossification nuclei fusion. Our work discusses CPC's history, etiology, clinical features, and methods of therapy. We especially emphasize athletes affected by this condition. Here we presents two clinical cases, treatment approaches and outcomes. CPC's distinct presentation, often painless, with central clavicular discontinuity and swelling, allows to differentiate it from other conditions. However, in sport athletes, due to the significant physical exertion involved, symptoms can manifest. Accurate diagnosis is crucial for effective management.

### **Key words**

Congenital Pseudoarthrosis of the Clavicle, CPC, Clavicle, surgical treatment, sport athletes

### **Introduction**

Congenital pseudoarthrosis of clavicle (CPC) is a rare condition due to failure of the union process of the ossification of nuclei of the clavicle [1]. The first documented case of the CPC was described by Fitzwilliams in 1910 as a cleido-cranias dystosis [2]. Since then approximately 200 cases of CPC have been described. The etiology has not been fully understood, authors suggest potential association between CPC and dextrocardia [3]. There is

a theory that suggests that the clavicle typically develops from two ossification centers, which may fail to fuse. There is a group of patients who lack a familial history of pseudoarthrosis, while in others, the family members are similarly affected which suggests that congenital pseudoarthrosis of the clavicle may have genetic basis in certain cases [1,4]. Certain researchers propose that the development of CPC might be influenced more by environmental rather than genetic factors [5]. Classical Congenital Pseudoarthrosis typically becomes apparent either at birth or during early childhood [1]. In most cases, the condition occurs on the right clavicle in girls [6]. Congenital pseudoarthrosis of the left clavicle is often linked to additional congenital disorders, including dextrocardia [7]. Bilateral occurrence is possible in up to 10% of cases, often linked to an unusually elevated placement of the subclavian artery [8]. Radiographic examinations reveal a discontinuity in the central part of the clavicle, accompanied by an interspace cleft; the bone ends are either hypertrophied or thinned [9]. Clinically it is characterized by the presence of a painless lump on the clavicle. The main symptom is swelling in the middle third of the clavicle, which often enlarges as the child grows [10]. Patients may not experience any symptoms throughout their entire life, and the range of shoulder motion can remain painless and normal [11]. Another potential clinical scenario involves a course in which neither pain nor difficulties with regular activities are experienced. However, intense physical exertion can trigger pain in the vicinity of the defect [6]. The lack of pain is an important when distinguishing the disease from a post-traumatic nonunion [12]. The primary differential diagnoses for congenital pseudoarthrosis of the clavicle include cleidocranial dysostosis and posttraumatic pseudoarthrosis. Birth fracture should be considered, in which significant pain is present, while the fracture heals with exuberant callus [13]. Unlike other conditions, CCPC does not stem from any history of trauma, pain, or disability in the patient's past [1]. Our study aims to present two clinical cases of this uncommon medical condition, along with the methods employed in their treatment and the ultimate outcomes achieved.

## **Case Report**

### **Case 1**

An 8-year-old boy was presented to the orthopedics department with a congenital pseudojoint of the right clavicle. Upon admission, a chest X-ray was performed, revealing an anomaly (Figure 1).

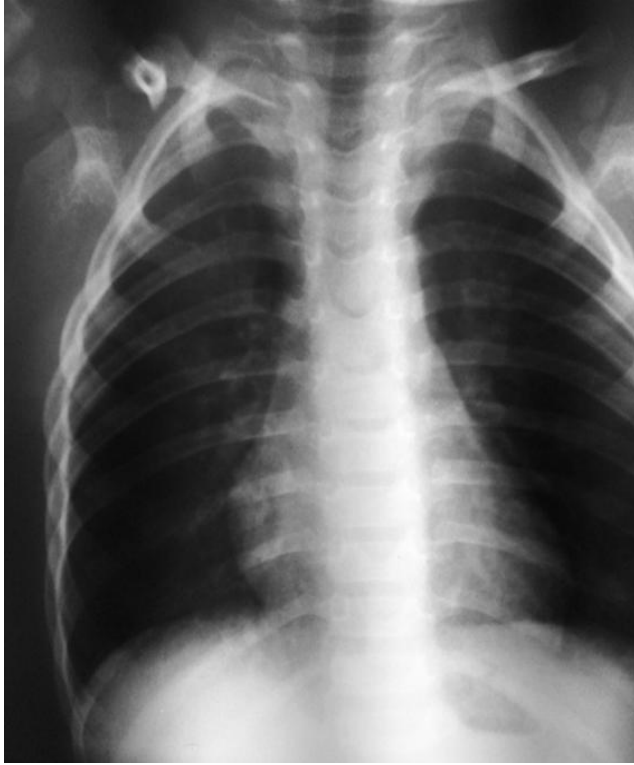

Figure 1.  
*X-ray showing the pseudoarthrosis of the right clavicle.*

The physical examination exposed a CPC located 3 cm from the acromial end of the clavicle. According to the mother's account and medical documentation, the deformity was diagnosed when the child was 2 years old. However, no further treatment decisions were made at that time.

At the age of 6, due to increasing discomfort, the patient was readmitted to the department. During this stay and based on imaging studies (Figure 2) and physical examination (Figure 3) the decision for further intervention was made, and the patient was qualified for surgical treatment.

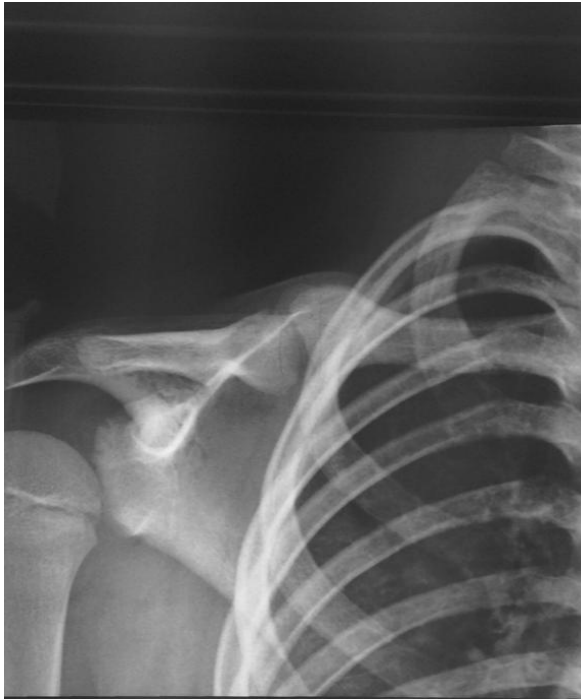

Figure 2.  
*X-ray of the chest by the 6 year-old patient*

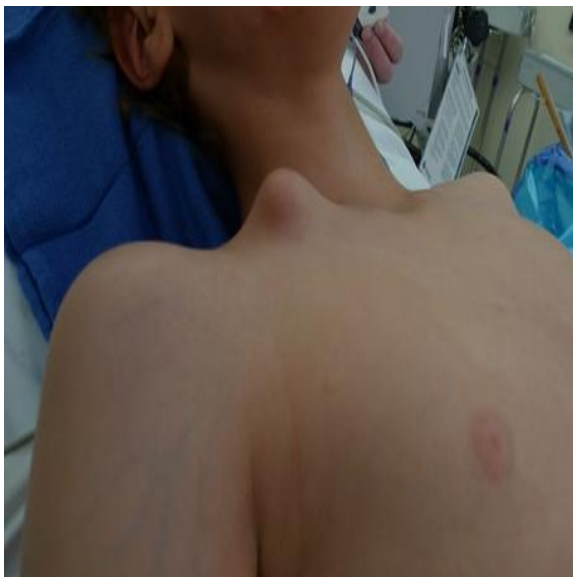

Figure 3.  
*Photograph illustrating the patient deformity*

The patient underwent surgery in the Orthopedics Department, during which the decision was made to perform a resection of the pseudojoint along with intramedullary stabilization (Figure 4), and the defect was filled using the ChronOs preparation.

After the surgical treatment was administered, the decision was made to apply a Desault's bandage for temporary immobilization for a period of 4 weeks.

Full and satisfactory radiographic union was achieved in the 6th week after the surgical procedure.

After 6 months from the surgery, the decision was made to remove the fixation material

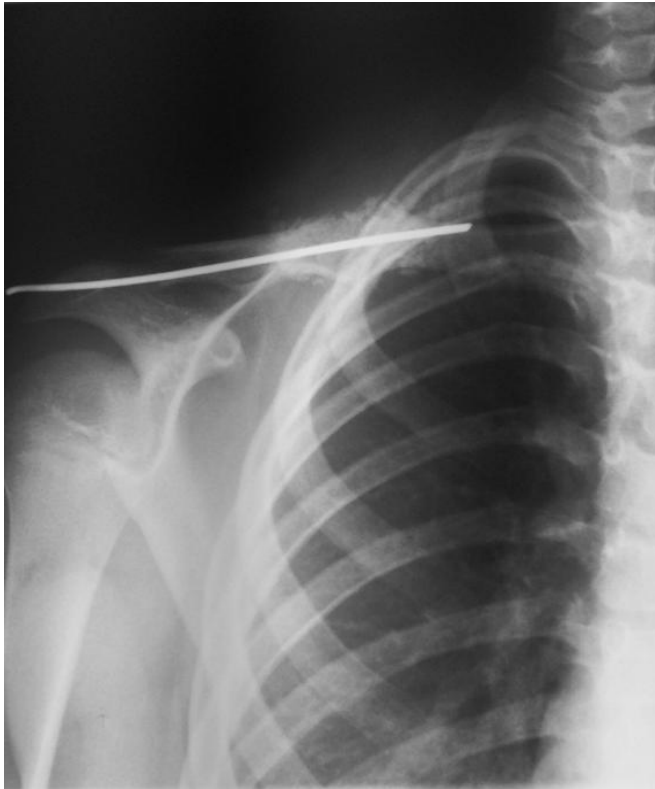

Figure 4.  
*Post-operative X-ray by the 6-year-old patient demonstrating intramedullary stabilization*

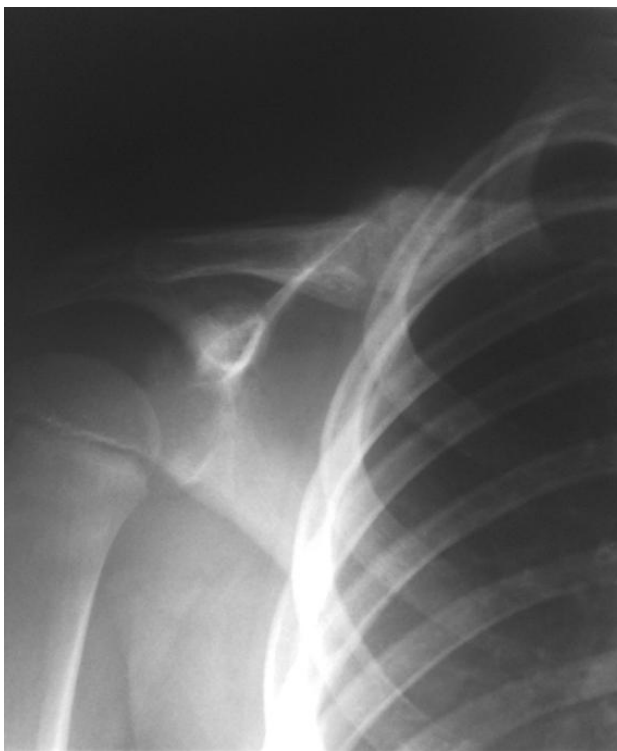

Figure 5.  
*X-ray depicting proper bone union after the removal of fixation material*

## Case 2

A 6-year-old boy was admitted to the ward due to a deformity of his right clavicle. The medical history of the child indicated that the deformity was diagnosed when he was 5 years old. The patient presented with painful symptoms in the area of his right shoulder. During the physical examination, attention was drawn to the taut skin over the sternal end of the clavicle; no motor deficits were observed within the upper limb.

Necessary imaging studies, including X-rays ([Figure 6](#)) and a Computer Tomography ([Figure 7](#)), were performed, revealing a bone defect in the clavicle. It was decided to qualify the patient for surgical treatment.

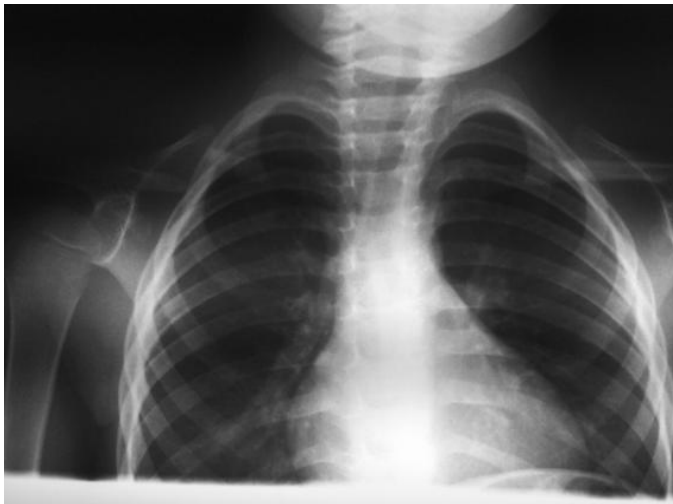

Figure 6.  
*X-ray revealing pseudoarthrosis of the right clavicle*

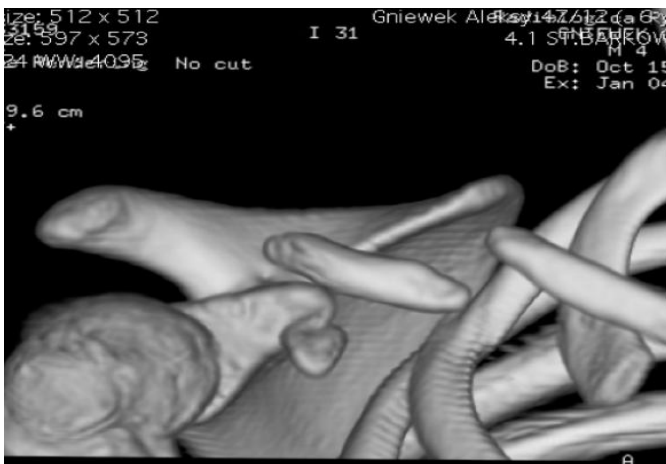

Figure 7.  
*CT showing loss of bone of clavicle*

Due to the size of the defect (1.5 cm), a resection of the pseudojoint was performed along with the defect being filled using an autogenous graft from the hip bone's head. Stabilization was achieved using a LCP plate ([Figure 8](#)). The length of the right clavicle was restored to match the healthy side. Additionally, the operated area was covered with a membrane, and platelet-derived growth factors were administered ([Figure 9](#)).

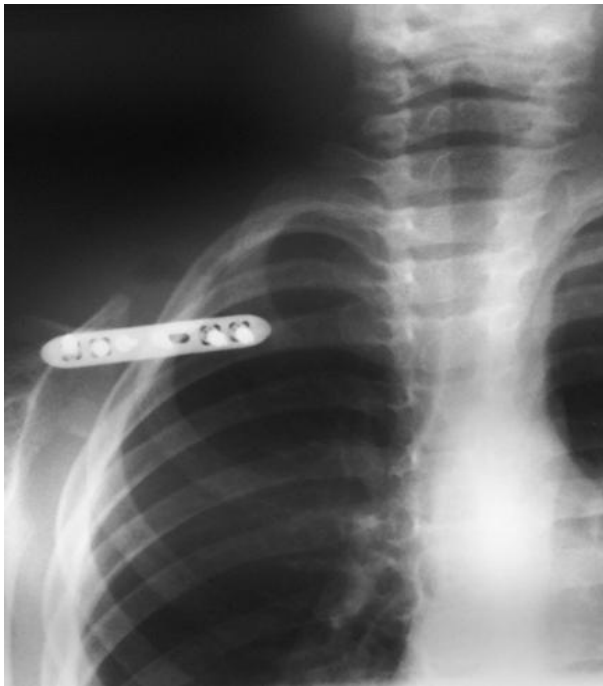

Figure 8.  
*Postoperative X-ray with LCP plate  
on the right clavicle*

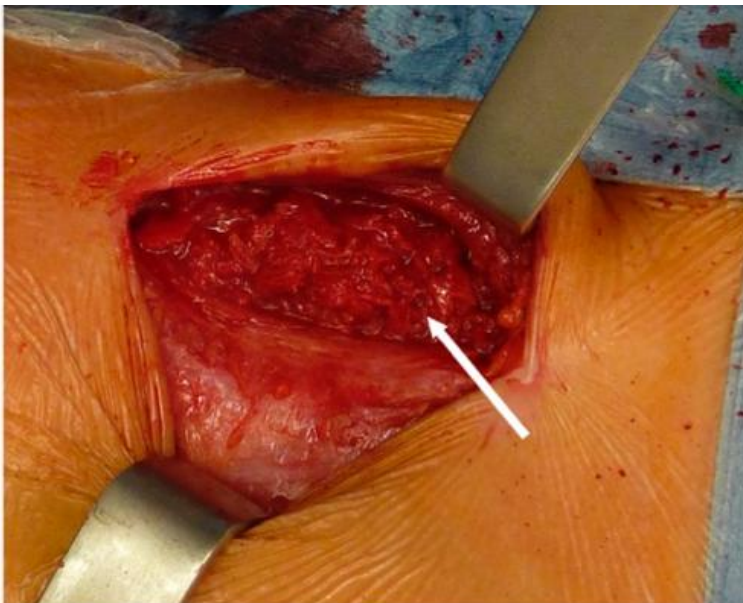


Figure 9.  
*Intraoperative picture which shows  
membrane that was used (white arrow)*

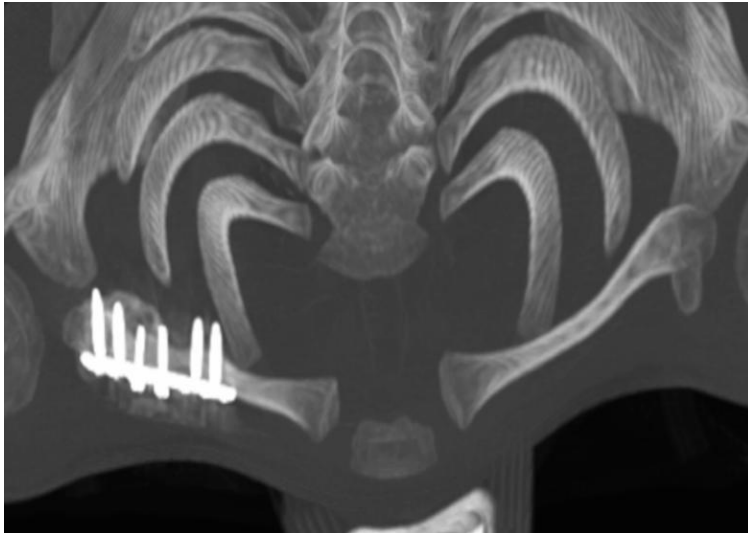


Figure 10.

*Postoperative CT scan showing the proper placement of an LCP plate*

After the surgical treatment was administered, the decision was made to provide temporary immobilization using a Desault's bandage for a period of 6 weeks. Following this, for the subsequent 6 weeks, the child used a brace (temblak) for support

### **Impact on Sports Participation:**

Individuals afflicted by the condition who are not engaged in competitive sports often go through their entire lives without experiencing any discomfort related to the clavicle. However, the situation is different for athletes who are exposed to excessive physical exertion, which can lead to painful symptoms [11]. Athletes afflicted by pseudoarthritis of the clavicle frequently experience enduring shoulder discomfort, particularly when engaging in activities involving overhead motions [6]. In Professional sportsmen experiencing discomfort, we should consider surgical treatment, periods of rest, as well as appropriate physiotherapy. We should take into account the pain intensity and the restriction of movement in the joint. Before considering surgical intervention, one can explore the application of appropriate physiotherapy. The objective should be to reduce pain and restore optimal mobility in the joint. This should ultimately strive to enhance the quality of life and improve performance in the pursued sport. If an athlete undergoes surgery, it is important to remember that during the postoperative period, no physical activity will be permitted for an average of three months [14, 15, 16]. It is also important to bear in mind that in athletes, due to the elevated risk of injury associated with their profession, the disease should be differentiated from posttraumatic pseudoarthrosis of the clavicle [17].

### **Discussion**

Congenital pseudarthrosis of the clavicle is an uncommon condition. Nonetheless, orthopedic professionals should be prepared to accurately diagnose and administer suitable care [18].

Diagnosing congenital pseudarthrosis of the clavicle is established through straightforward radiographic assessments. These images reveal one end taking on an "elephant's foot"



appearance, while the other assumes a "pencil point" shape. Importantly, there is no contact between these ends, and no formation of reactive bone callus is observed [18].

The clinical diagnosis of the condition is made based on the observation of a painless bulge in the middle third of the clavicle in the first days of life, which becomes increasingly prominent as the child grows [18]. The use of CT with 3-dimensional (3D) reconstruction is also a crucial tool enabling precise differential diagnostics and proving valuable in surgical planning. Performing an excisional biopsy of the clavicle, revealing its cartilaginous structure at the terminal surfaces of the pseudoarthrosis, can offer additional histological evidence [19]. Congenital pseudoarthrosis of the clavicle is different from obstetric fracture, post-traumatic non-union, cleidocranial dysostosis, or neurofibromatosis.

An obstetric fracture of the clavicle should be suspected when there is a history of a difficult delivery, pseudoparalysis of the arm with no voluntary limb movement and pain on passive movement, or when a massive callus is seen radiographically.

Plain radiographs can help differentiate the diagnosis of congenital pseudoarthrosis from traumatic non-union because in the latter the bone ends seem attenuated [14].

The treatment of congenital pseudoarthrosis remains a subject of debate among specialists. Some doctors opt for observation of patients, while others choose surgical treatment with or without bone graft [18].

The option of surgical treatment may be contemplated for individuals experiencing upper limb dysfunction, characterized by diminished strength or limited range of motion. Furthermore, surgical intervention might also serve cosmetic objectives and act as a preventive measure against the emergence of late-onset thoracic outlet syndrome [14].

The age of the child at which surgery should be performed remains a topic of discussion among medical professionals. Many of them report that early interventions lead to improved therapeutic outcomes; however, parents typically delay the surgical procedure for their children.

Surgery in very young children is associated with an increased risk of inadequate bone union. On the other hand, this condition is more frequently observed in patients aged 8 years or older. Based on studies conducted in 2010, operative treatment provide better outcomes in children aged 2 to 4 years old [20].

According to more recent reports, surgical intervention should be considered between the ages of 5 and 7 [21], while the literature recommends surgical treatment between the ages of 3 and 5 [22].

In the largest study comparing the timing of surgical intervention, the percentage of patients requiring subsequent surgeries was higher among those, who underwent surgery after 18 months of age (median 6 years). However, the percentage of failed bone unions was more frequently observed in patients who underwent surgery before 18 months of age (median age 8 months) [23].

As a result, the risk of treatment failure or the need for reoperation should be taken into account when making decisions regarding the timing of intervention.

Non-operative treatment is also a course of action if the patient is asymptomatic and there is no impairment of upper limb function. However, patients with Congenital Pseudoarthrosis of the Clavicle (CPC) opt for surgical treatment due to pain, lack of aesthetic appearance, and the enlargement of the anomaly as the patient ages.

## **Conclusion**

In summary, a patient presenting with Congenital Pseudoarthrosis of the Clavicle (CPC) should be managed comprehensively. Surgical treatment for congenital pseudoarthrosis of the clavicle should be determined based on the local condition. The patient should be thoroughly examined, a detailed history should be obtained to assess pain or cosmetic defect, routine

imaging studies should be ordered, and appropriate management options should be proposed and discussed. When making decisions about surgical intervention, the risk of treatment failure and reoperation should be taken into account. For athletes, who, due to the nature of their profession, are particularly susceptible to pain, discomfort, and diminished physical performance, leading to a reduced quality of life, considering appropriate physiotherapy as well as surgical treatment is advisable.

### **Author Contributions**

Conceptualization, K.K., I.M., M.B.; supervision and project administration, M.B., K.K., I.M., A.A., J.Z.; T.H.A and A.A.A., I.M., K.K.; Methodology, K.K., I.M.; Software, A.A., J.Z.; Validation, K.K., I.M.; formal analysis, A.A., M.B.; investigation, M.B.; resources, K.K., I.M.; writing- original draft preparation, K.K., I.M., A.A., J.Z., M.B.; writing- review and editing and visualization, K.K., I.M., A.A., J.Z., M.B.

### **Funding**

This research received no external funding.

### **Institutional Review Board Statement**

Not applicable. The study was conducted in accordance with the Declaration of Helsinki. In accordance with the law in force in the Republic of Poland, case report retrospective studies do not require the opinion or consent of the Bioethics Committee, as they are not a medical experiment in which human organisms would be interfered with. For this reason, we did not seek the consent of the Commission. What's more, the results of the study did not affect the management of patients at any stage, so the above-mentioned procedure was followed.

### **Informed Consent Statement**

Not applicable.

### **Data Availability Statement**

Not applicable.

### **Conflicts of Interest**

The authors declare no conflict of interest.

### **References**

- [1] Gibson DA, Carroll N. CONGENITAL PSEUDARTHROSIS OF THE CLAVICLE. *J Bone Joint Surg Br.* 1970;52-B(4):629-643. doi:10.1302/0301-620X.52B4.629
- [2] Fitzwilliams, D. L. (1910). Hereditary cranio-cleido-dysostosis: with a review of all the published cases of this disease: theories of the development of the clavicle suggested by this condition. *The Lancet*, 176(4551), 1466-1475.
- [3] Kite, J. H. "Congenital pseudarthrosis of the clavicle." *Southern Medical Journal* 61.7 (1968): 703-710.

- [4] Price, B. D., and C. T. Price. "Familial congenital pseudoarthrosis of the clavicle: case report and literature review." *The Iowa Orthopaedic Journal* 16 (1996): 153.
- [5] Behringer, B.R. and Wilson, F.C.: Congenital pseudoarthrosis of the clavicle. *American Journal of Diseases of Children*, 123:511-7,1972
- [6] Gibson, D. A., and N. Carroll. "Congenital pseudarthrosis of the clavicle." *The Journal of Bone & Joint Surgery British Volume* 52.4 (1970): 629-643.
- [7] Lloydhe clavicle. With a note on cranio-cleido dysostosis. *J Bone Joint Surg Br.* 1975 Feb;57(1):24-9. - Roberts GC, Apley AG, Owen R. Reflections upon the aetiology of congenital pseudarthrosis of tPMID: 1117020.
- [8] Herring JA. Tachdjian's pediatrics orthopaedics. 4th ed. WB Saunders; Philadelphia: 2008. Pseudarthrosis of the clavicle; pp. 2423–2429. [Google Scholar] [Ref list]
- [9] Persiani, Pietro, et al. "Surgical treatment of congenital pseudarthrosis of the clavicle: a report on 17 cases." *Acta Orthopaedica Belgica* 74.2 (2008): 161.
- [10] Behringer, Blair R., and Frank C. Wilson. "Congenital pseudarthrosis of the clavicle." *American Journal of Diseases of Children* 123.5 (1972): 511-517.
- [11] Manashil, G., and S. Laufer. "Congenital pseudarthrosis of the clavicle: report of three cases." *American Journal of Roentgenology* 132.4 (1979): 678-679.
- [12] Ahmadi B, Steel HH. Congenital pseudarthrosis of the clavicle. *Clin Orthop Relat Res.* 1977 Jul-Aug;(126):129-34. PMID: 598101.
- [13] Jinkins Jr, W. J. "24 Congenital Pseudarthrosis of the Clavicle." *Clinical Orthopaedics and Related Research*® 62 (1969): 183-186.
- [16] Beslikas TA, Dadoukis DJ, Gigis IP, Nenopoulos SP, Christoforides JE. Congenital pseudarthrosis of the clavicle: a case report. *J Orthop Surg (Hong Kong).* 2007 Apr;15(1):87-90. doi: 10.1177/230949900701500120. PMID: 17429126.
- [15] Lazaro R. Shoulder impingement syndromes: implications on physical therapy examination and intervention. *J Jpn Phys Ther Assoc.* 2005;8(1):1-7. doi: 10.1298/jjpta.8.1. PMID: 25792938; PMCID: PMC4316502.

- [16] Martínez-Aznar C, Parada-Avenida I, Gómez-Palacio VE, Abando-Ruiz S, Gil-Albarova J. Surgical treatment of congenital pseudoarthrosis of the clavicle: Our 22-year, single-center experience. *Jt Dis Relat Surg.* 2021;32(1):224-229. doi: 10.5606/ehc.2021.79576. Epub 2021 Jan 6. PMID: 33463441; PMCID: PMC8073441.
- [17] Odorizzi M, FitzGerald M, Gonzalez J, Giunchi D, Hamitaga F, De Rosa V. Posttraumatic Pseudoarthrosis of a Clavicle Fracture in an 11-Year-Old Girl: A Case Report and Analysis. *Case Rep Orthop.* 2020 Apr 23;2020:4069431. doi: 10.1155/2020/4069431. PMID: 32373378; PMCID: PMC7196132.
- [18] de Figueiredo MJ, Dos Reis Braga S, Akkari M, Prado JC, Santili C. CONGENITAL PSEUDARTHROSIS OF THE CLAVICLE. *Rev Bras Ortop.* 2015 Nov 16;47(1):21-6. doi: 10.1016/S2255-4971(15)30341-4. PMID: 27047839; PMCID: PMC4799365.
- [19] Sung TH, Man EM, Chan AT, Lee WK. Congenital pseudarthrosis of the clavicle: a rare and challenging diagnosis. *Hong Kong Med J.* 2013 Jun;19(3):265-7. doi: 10.12809/hkmj133648. PMID: 23732433.
- [20] Alsaeed AA. Surgical Management of Congenital Pseudoarthrosis of the Clavicle: A Review of Current Concepts. *Cureus.* 2021 Oct 4;13(10):e18482. doi: 10.7759/cureus.18482. PMID: 34754644; PMCID: PMC8565850.
- [21] Giwnewer U, Rubin G, Dohovni E, Rozen N, Bor N. Congenital pseudoarthrosis of the clavicle: Should we reconsider timing and fixation method? *J Orthop Surg (Hong Kong).* 2018 May-Aug;26(3):2309499018799539. doi: 10.1177/2309499018799539. PMID: 30235983.
- [22] Lorente Molto FJ, Bonete Lluch DJ, Garrido IM. Congenital pseudarthrosis of the clavicle: a proposal for early surgical treatment. *J Pediatr Orthop.* 2001 Sep-Oct;21(5):689-93. PMID: 11521043.
- [23] Kim AE, Vuillermin CB, Bae DS, Samora JB, Waters PM, Bauer AS. Congenital pseudarthrosis of the clavicle: surgical decision making and outcomes. *J Shoulder Elbow Surg.* 2020 Feb;29(2):302-307. doi: 10.1016/j.jse.2019.06.002. Epub 2019 Aug 16. PMID: 31427229.