

TUREK, Michał, WINIARZ, Aleksandra, SZLENDAK, Paula, TOŚ, Katarzyna, WOJTALA, Kacper, GROSMAN, Sylwia, WĘGRZYNIAK, Agata, DROBEK, Dominik, WAŚALA, Katarzyna and WOKURKA, Wojciech. Lower back pain caused by radiculopathy induced by lumbar stenosis - literature review. Journal of Education, Health and Sport. 2023;43(1):93-103. eISSN 2391-8306. DOI <http://dx.doi.org/10.12775/JEHS.2023.43.01.008>
<https://apcz.umk.pl/JEHS/article/view/45097>
<https://zenodo.org/record/8221567>

The journal has had 40 points in Ministry of Education and Science of Poland parametric evaluation. Annex to the announcement of the Minister of Education and Science of 17.07.2023 No. 32318. Has a Journal's Unique Identifier: 201159. Scientific disciplines assigned: Physical Culture Sciences (Field of Medical sciences and health sciences); Health Sciences (Field of Medical Sciences and Health Sciences). Punkty Ministerialne z 2019 - aktualny rok 40 punktów. Załącznik do komunikatu Ministra Edukacji i Nauki z dnia 17.07.2023 Lp. 32318. Posiada Unikatowy Identyfikator Czasopisma: 201159. Przypisane dyscypliny naukowe: Nauki o kulturze fizycznej (Dziedzina nauk medycznych i nauk o zdrowiu); Nauki o zdrowiu (Dziedzina nauk medycznych i nauk o zdrowiu).

© The Authors 2023;

This article is published with open access at License Open Journal Systems of Nicolaus Copernicus University in Torun, Poland

Open Access. This article is distributed under the terms of the Creative Commons Attribution Noncommercial License which permits any noncommercial use, distribution, and reproduction in any medium, provided the original author (s) and source are credited. This is an open access article licensed under the terms of the Creative Commons Attribution Non commercial license Share alike. (<http://creativecommons.org/licenses/by-nc-sa/4.0/>) which permits unrestricted, non commercial use, distribution and reproduction in any medium, provided the work is properly cited.

The authors declare that there is no conflict of interests regarding the publication of this paper.

Received: 15.07.2023. Revised:30.07.2023. Accepted: 07.08.2023. Published: 15.08.2023.

Lower back pain caused by radiculopathy induced by lumbar stenosis -literature review

Michał Turek [MT]

Independent Public Clinical Hospital No.4 in Lublin, Poland

<https://orcid.org/0000-0001-9117-517X>

Aleksandra Winiarz [AW]

Samodzielny Publiczny Szpital Kliniczny nr1 w Lublinie, Poland

<https://orcid.org/0000-0002-6994-5796>

Paula Szlendak [PS]

Independent Public Clinical Hospital No.4 in Lublin, Poland

<https://orcid.org/0000-0001-8880-3139>

Katarzyna Toś [KT]

Independent Public Health Care Center in Lubaczów, 168 Mickiewicza St., 37-600

Lubaczów

<https://orcid.org/0000-0002-4674-4078>

Kacper Wojtala [KW]

Independent Public Clinical Hospital No.1 in Lublin, Poland

<https://orcid.org/0000-0002-3531-4603>

Sylwia Grosman [SG]

Clinical Hospital of Poznan University of Medical Sciences, 1/2 DługaSt., 61-848 Poznań

<https://orcid.org/0000-0003-2126-6011>

Agata Węgrzyniak [AWę]

Central Clinical Hospital of the Ministry of Interior and Administration in Warsaw,

Wołoska 137,02-507 Warszawa

<https://orcid.org/0000-0001-8638-0013>

Dominik Drobek [DD]

Medical University of Lublin, 20-059 Lublin, Poland

<https://orcid.org/0000-0001-6072-2513>

Katarzyna Wąsala [KWą]

Clinical Hospital of Poznan University of Medical Sciences, 1/2 DługaSt., 61-848 Poznań

<https://orcid.org/0009-0008-1795-6259>

Wojciech Wokurka [WW]

Department of Anatomy, Medical University of Lublin, 20-059 Lublin, Poland

<https://orcid.org/0000-0001-9936-5656>

Introduction: Lumbar spine pain is a common clinical problem. Due to the multitude of causes of pain, it is important to know the most common ones in order to choose an effective method of treatment.

The aim of this study: Summary of current knowledge regarding back pain caused by radiculopathy associated with lumbar stenosis.

Material and method: The review includes publications published in 1995-2020. The search of the publications in the Pubmed database was carried out using the following keywords: back pain, radiculopathy, lumbar stenosis.

Description of the stage of the knowledge: Lumbar radiculopathy caused by lumbar stenosis is a common clinical problem, especially in older age groups. In diagnostics, an interview with the patient, physical examination and imaging tests - especially CT and MRI - are important. In most patients, conservative treatment is sufficient - the use of analgesics and anti-inflammatory drugs and physiotherapy. In justified cases, surgical treatment should be considered as the most effective causative treatment of the disease. In the last 20 years, the availability of both diagnostic methods has increased and new surgical techniques have appeared, aiming at minimally invasive treatment.

Summary: Radiculopathy caused by lumbar stenosis is a contributing factor to the occurrence of pain, which can hinder the normal functioning of the patient. Proper diagnosis, identification of the impact and methods of treatment, both conservative and surgical, can help the patient and affect his quality of life. Early diagnosis and treatment are crucial for the effective treatment of pain associated with radiculopathy caused by lumbar stenosis.

Key words: back pain, radiculopathy, lumbar stenosis

Introduction

Pain in the lumbosacral spine is a common ailment faced by doctors of various specialties, not only neurologists, neurosurgeons or orthopedists, but also family medicine doctors and general practitioners.[15] One of the most common causes of back pain is lumbosacral radiculopathy. It is a neurological condition caused by direct compression of pathological masses on the medullary root or damage of the root caused by inflammatory mediators secreted in response to mechanical irritation. One of the main causes of radiculopathy is lumbar stenosis, that is a state of limitation of the space of the spinal canal and intervertebral foramina through which the spinal roots run.[2] [19]

The causes of lumbar stenosis can be varied, the most common include: discopathy, spinal joint degeneration, spondylolisthesis, spinal canal tumors, autoimmune inflammatory diseases of the spine, e.g. ankylosing spondylitis, congenital anatomical defects, such as age - dehydration of the intervertebral discs causing a change in their shape or thickening of the spinal ligaments.[15][20]

Disc herniation occurs when the annulus is interrupted and the anterior protrusion of the nucleus pulposus can compress the nerve roots - radiculopathy or the dural sac - lumbar stenosis. In addition to mechanical pressure, inflammatory mediators are released and induce local inflammation. [1][2][8]

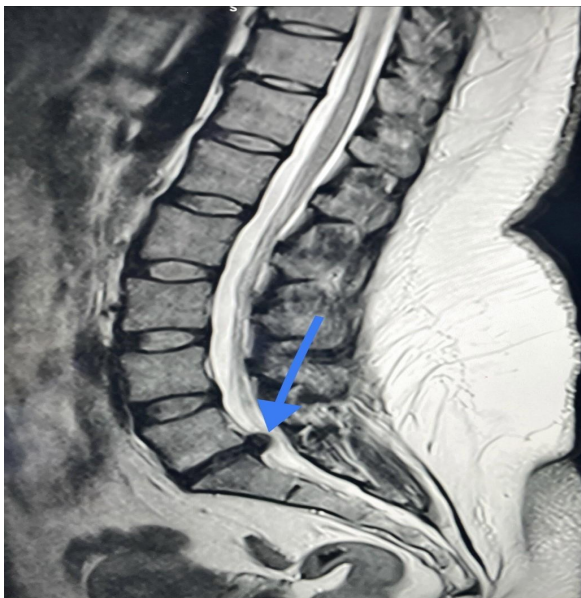


Fig.1 MRI - sagittal section with visible herniation of the intervertebral disc L5/S1 with compression of the thecal sac, resulting in L5/S1 stenosis.

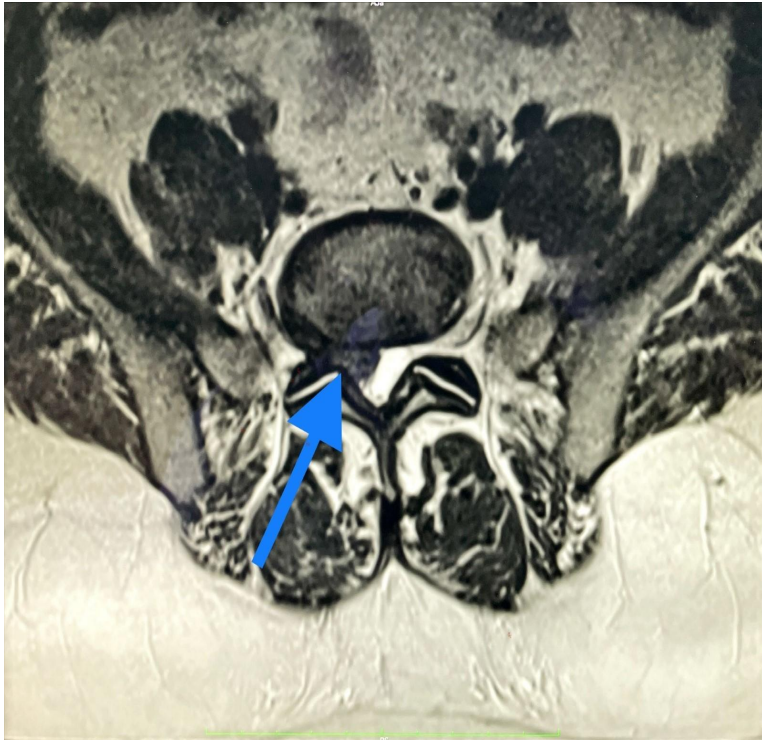


Fig.2 MRI - transverse section with a visible herniated L5/S1 intervertebral disc with compression on the thecal sac and the right S1 spinal root.

Spinal degeneration is one of the main causes of lumbar stenosis. It progresses with the age of the patient, the intervertebral joints degenerate, leading to the formation of osteophytes and reducing the space in the spinal canal. Another lumbar stenosis cause is a spondylolisthesis, spine pathology where one vertebra slides over another. This may be caused by damage of the intervertebral joint or degeneration of the intervertebral disc and ligament structures. As a result, the adjacent vertebrae are shifted, which may cause the limitation of the space of the spinal canal and compression of the nerve structures. In some cases, lumbar stenosis can be caused by congenital anatomical defects, such as a narrow spinal canal, vertebral shape abnormalities, or other structural issues. [4][13][17]

There are several risk factors associated with the development of lumbar spinal stenosis such as - age, lumbar spinal stenosis is more common in older individuals. During aging, the spine can undergo degeneration, leading to a reduction in the space inside the spinal canal.

Genetics - there are certain genetic predispositions to the development of lumbar spinal stenosis. If there are cases of this condition in the family, there is a higher risk of developing it. Degenerative changes in the spine, such as disc herniation, osteophytes (bone spurs), or chronic joint inflammation, can contribute to the narrowing of the spinal canal.

Previous spinal injuries, such as fractures or disc injuries, can increase the risk of developing lumbar spinal stenosis in the future. Prolonged maintenance of poor posture, especially during repetitive activities or heavy lifting. Excessive spinal loading associated with obesity can contribute to degeneration and narrowing of the spinal canal. Smoking can lead to impaired blood circulation and nutrition to the spine, which, in turn, increases the risk of lumbar spinal stenosis. [1][2][13][25]

Symptoms

The symptoms of radiculopathy can vary depending on the level of the spine and the severity of the damage. Here are some of the most common symptoms of lumbosacral radiculopathy:

Low back pain radiating down one or both legs. Intensifying during movement, physical exertion, extended sitting position or bending over. The radiation of pain depends on the level of damage, most often it can reach the buttocks, back of the thigh, calf, foot or toes.

Weakness of muscle strength in the area innervated by the damaged nerve root. This may manifest as difficulty lifting objects, walking up and down stairs or maintaining a standing or sitting position. [11][17]

Tingling and numbness of the muscles and disturbance of superficial in the area of innervation of the damaged nerve. [4]

Difficulties in controlling urination and defecation by impairing the function of the urethral or anal sphincter muscles.

Sexual function disorders, including weak erections, decreased libido and difficulties in achieving satisfaction with sexual activity. [9]

These symptoms significantly limit the patient's quality of life, reducing his ability to move or work.[11][22][23]

Diagnostics

The most important role in the diagnosis of back pain caused by lumbar radiculopathy is the medical history and physical examination. The medical history allows you to initially exclude the causes of traumatic ailments, assess the family and environmental history, especially work in conditions of high physical exertion. Imaging tests are performed to confirm the presence of lumbar stenosis.

The signs of spinal root tension:

Lasègue's sign, also known as the straight leg raising (SLR) test, is used to differentiate sciatica from hip pain. The test involves raising the affected leg by the ankle until pain is felt. A positive test result is indicated by leg pain or paresthesias in the pain distribution area, excluding back pain alone. Ankle dorsiflexion during SLR may intensify pain caused by nerve root compression. Lasègue's sign is mostly associated with compression of the L5 and S1 nerve roots, less so with L4, and has minimal effect on more proximal roots. It is positive in about 83% of cases with nerve root compression and is more likely to be positive in patients under 30 years old with a history of herniated lumbar disc.[5][16]

The Cram test is performed with the patient lying down. The symptomatic leg is raised with the knee slightly flexed, and then the knee is extended. The results are similar to the SLR test.

The crossed straight leg-raising test, also known as Fajersztajn's sign, involves performing SLR on the painless leg, which causes contralateral limb pain. A greater degree of leg elevation is usually required compared to the painful side. This test is more specific but less sensitive than the SLR test, and it may indicate a more central disc herniation.

The femoral stretch test, also called the reverse straight leg raising test, is performed with the patient lying face down. The examiner's palm is placed at the popliteal fossa, and the knee is maximally dorsiflexed. This test is often positive in cases of L2, L3, or L4 nerve root compression (such as upper lumbar disc herniation) or with extreme lateral lumbar disc herniation. It may also be positive in conditions like diabetic femoral neuropathy or psoas hematoma. In these situations, the SLR test (Lasègue's sign) is frequently negative as it primarily involves L5 and S1.

The "bowstring sign" is observed when, after experiencing pain with SLR, the foot is lowered to the bed by flexing the knee while keeping the hip flexed. This maneuver relieves sciatic pain but does not alleviate hip pain.

The sitting knee extension test is performed with the patient seated, hips and knees flexed at 90°. One knee is slowly extended, stretching the nerve roots to a similar extent as a moderate degree of SLR.[4][5][11][15][16]

The gold standard is the MRI examination of the lumbosacral spine. MRI is one of the most precise diagnostic methods used in lumbar stenosis. It allows you to obtain detailed images of the structures of the spine, including the spinal canal, intervertebral discs, ligaments and nerves. MRI allows the identification of spinal stenosis and possible compression of the nerve roots. The disadvantages of this method include a relatively long execution time and less availability of MRI machines compared to other diagnostic methods.[2][16][19]

Computed tomography (CT) can be used in the diagnosis of lumbar stenosis. It allows to obtain cross-sectional images of the spinal structures and can be particularly useful in assessing the anatomy of the spine and the degree of stenosis of the spinal canal. The advantages include greater accessibility of this method compared to MRI and shorter execution time, which is more important in emergency and trauma cases.[15][19]

A spinal X-ray can be used in the initial assessment of the spine, but cannot provide detailed information about spinal stenosis or nerve root compression. However, it is a relatively accessible and quick method that can help rule out other causes of back pain.

Electromyography (EMG) is an electrophysiological test that evaluates the electrical activity of muscles. It can be used in the case of suspected nerve root compression, helping to locate nerve damage and assess its degree.[5][7][24]

Treatment

Conservative treatment: For mild symptoms of lumbar stenosis radiculopathy, conservative treatment may include rest, avoidance of exercise, use of cold compresses, analgesics and anti-inflammatory drugs, followed by physiotherapy to strengthen the spinal muscles and improve range of motion. In 89–90% of patients with low back problems will improve within 1 month even without treatment (including patients with sciatica from disc herniation). [1][12][14][20][22]

Drug therapy: analgesics, non-steroidal anti-inflammatory drugs and in some cases anti-seizure drugs or steroids may be prescribed to relieve pain and reduce inflammation.[3]

Physiotherapy: Spinal strengthening and stabilization exercises, manual therapy, massage, and techniques such as electrical nerve stimulation and ultrasound can all help to ease the recovery and improve spinal function.[10]

Injections of corticosteroids under local anesthetic into the area of nerve root compression can relieve pain and reduce inflammation. [3][6]

Surgical Treatment

For severe or progressive symptoms that do not respond to conservative treatment, surgical treatment such as spinal canal decompression: this is one of the most commonly used surgical procedures to treat lumbar stenosis radiculopathy. It involves the removal of bone fragments, osteophytes, or other structures that compress the nerve roots in the spinal canal. Decompression of the spinal canal helps to restore proper space for the nerve roots and relieves pressure, which brings relief and reduces the symptoms of radiculopathy.[13]

Discectomy - if a herniated disc is the cause of lumbar stenosis, a discectomy may be necessary. The procedure involves the removal of a displaced intervertebral disc that compresses the dural sac or spinal roots. Sometimes combined with foraminotomy, which consists in widening the intervertebral foramina and providing space for decompression of the oppressed root. Currently, the techniques of classical open surgery or the increasingly popular endoscopic methods are available[1][2] [18].

Laminectomy is a surgical procedure in which part of the back surface of the vertebral arches is removed to create more space for the nerve roots and relieve pressure in the spinal canal.

Spinal fusion laminectomy - in cases where lumbar stenosis is associated with spinal instability, spinal fusion may be required. This procedure involves removing part of the vertebral arches and connecting two adjacent vertebrae with implants screwed into the pedicle. Spinal fusion stabilizes the lumbar region and prevents further displacement of the vertebrae. Available techniques are (posterior lumbar interbody fusion - PLIF) (anterior lumbar interbody fusion - ALIF) LLIF (lateral lumbar interbody fusion) or XLIF (extreme lateral interbody fusion).

Summary

Radiculopathy caused by lumbar stenosis is one of the causes of back pain, which can significantly negatively affect the daily functioning of the patient. Proper diagnosis, identification of the cause and appropriate methods of treatment, both conservative and surgical, can bring relief to the patient and improve his quality of life. Early diagnosis and appropriate therapeutic approach are crucial for successful treatment of back pain associated with radiculopathy caused by lumbar stenosis.

Supplementary Materials: Fig.1 MRI - sagittal section with visible herniation of the intervertebral disc L5/S1 with compression of the thecal sac, resulting in L5/S1 stenosis of 35 years old female patient. Fig.2 MRI - transverse section with a visible herniated L5/S1 intervertebral disc with compression on the thecal sac and the right S1 spinal root of 35 years old female patient.

Author's contribution: Conceptualization, MT, and AW; methodology, AWę; software, DD; check, MT, PS, KW, SG and KWą; formal analysis, MT, KT; investigation, MT, KT; resources, MT; data curation, MT, WW, KW, KWą; writing - rough preparation, WW; writing - review and editing, WW, AWę, AW, DD, KW, KWą, SG, MT, KT, and PS; visualization, MT, DD, MT, KT, WW and PS; supervision, MT, AW; project administration, MT, KW.

All authors have read and agreed with the published version of the manuscript.

Funding Statement: No financial support was received.

Institutional Review Board Statement: Not applicable - the study included an analysis of the available literature.

Informed Consent Statement: Not applicable.

Conflict of interest: The authors declare no conflict of interest.

References:

- [1] Arts MP, Kuršumović A, Miller LE, et al. Comparison of treatments for lumbar disc herniation: Systematic review with network meta-analysis. *Medicine*. 2019;98:e14410.
- [2] Awad JN, Moskovich R. Lumbar Disc Herniations: Surgical versus Nonsurgical Treatment. *Clinical Orthopaedics & Related Research*. 2006;443:183–197.
- [3] Benoist M, Boulu P, Hayem G. Epidural steroid injections in the management of low-back pain with radiculopathy: an update of their efficacy and safety. *Eur Spine J*. 2012;21:204–213.
- [4] Bogduk N. On the definitions and physiology of back pain, referred pain, and radicular pain. *Pain*. 2009;147:17–19.

- [5] Cannon DE, Dillingham TR, Miao H, et al. Musculoskeletal Disorders in Referrals for Suspected Lumbosacral Radiculopathy. *American Journal of Physical Medicine & Rehabilitation*. 2007;86:957–961.
- [6] Chou R, Deyo R, Friedly J, et al. Nonpharmacologic Therapies for Low Back Pain: A Systematic Review for an American College of Physicians Clinical Practice Guideline. *Ann Intern Med*. 2017;166:493.
- [7] Chouteau WL, Annaswamy TM, Bierner SM, et al. Interrater Reliability of Needle Electromyographic Findings in Lumbar Radiculopathy. *American Journal of Physical Medicine & Rehabilitation*. 2010;89:561–569.
- [8] Demetriades AK. Insights into the inflammatory process of lumbar discopathy. *Acta Neurochir*. 2020;162:87–88.
- [9] Dzierżanowski M, Dzierżanowski M, Wrzecion K, et al. Discopathy of the Lumbar-Sacral Segment and Its Influence on Sexual Dysfunction.
- [10] Ostelo RW. Physiotherapy management of sciatica. *Journal of Physiotherapy*. 2020;66:83–88.
- [11] Patel E, Perloff M. Radicular Pain Syndromes: Cervical, Lumbar, and Spinal Stenosis. *Semin Neurol*. 2018;38:634–639.
- [12] Qaseem A, Wilt TJ, McLean RM, et al. Noninvasive Treatments for Acute, Subacute, and Chronic Low Back Pain: A Clinical Practice Guideline From the American College of Physicians. *Ann Intern Med*. 2017;166:514.
- [13] Rogerson A, Aidlen J, Jenis LG. Persistent radiculopathy after surgical treatment for lumbar disc herniation: causes and treatment options. *International Orthopaedics (SICOT)*. 2019;43:969–973.
- [14] Stockkendahl MJ, Kjaer P, Hartvigsen J, et al. National Clinical Guidelines for non-surgical treatment of patients with recent onset low back pain or lumbar radiculopathy. *Eur Spine J*. 2018;27:60–75.
- [15] Tarulli AW, Raynor EM. Lumbosacral Radiculopathy. *Neurologic Clinics*. 2007;25:387–405.
- [16] Tawa N, Rhoda A, Diener I. Accuracy of clinical neurological examination in diagnosing lumbo-sacral radiculopathy: a systematic literature review. *BMC Musculoskeletal Disord*. 2017;18:93.
- [17] Vulfsons S, Bar N, Eisenberg E. Back Pain with Leg Pain. *Curr Pain Headache Rep*. 2017;21:32.

- [18] Ahn Y. Endoscopic spine discectomy: indications and outcomes. *International Orthopaedics (SICOT)*. 2019;43:909–916.
- [19] Casey E. Natural History of Radiculopathy. *Physical Medicine and Rehabilitation Clinics of North America*. 2011;22:1–5.
- [20] McNeely ML, Torrance G, Magee DJ. A systematic review of physiotherapy for spondylolysis and spondylolisthesis. *Manual Therapy*. 2003;8:80–91.
- [21] Orita S, Inage K, Eguchi Y, Kubota G, Aoki Y, Nakamura J, et al. Lumbar foraminal stenosis, the hidden stenosis including at L5/S1. *Eur J Orthop Surg Traumatol*. 2016 Oct;26(7):685–93.
- [22] Jain N, Acharya S, Adsul NM, Haritwal MK, Kumar M, Chahal RS, et al. Lumbar Canal Stenosis: A Prospective Clinicoradiologic Analysis. *J Neurol Surg A Cent Eur Neurosurg*. 2020 Sep;81(05):387–91.
- [23] Bydon M, Alvi MA, Goyal A. Degenerative Lumbar Spondylolisthesis. *Neurosurgery Clinics of North America*. 2019 Jul;30(3):299–304.
- [24] Schönström N, Willén J. Imaging Lumbar Spinal Stenosis. *Radiologic Clinics of North America*. 2001 Jan;39(1):31–53.
- [25] Lai MKL, Cheung PWH, Cheung JPY. A systematic review of developmental lumbar spinal stenosis. *Eur Spine J*. 2020 Sep;29(9):2173–87.