

SEKULA, Michał Jakub, PAWLUCKI, Piotr, MACIAK, Anna, CHYŁA, Jakub, SMOLUCHOWSKI, Krzysztof, SOKÓŁ, Dorota, PIOTROWSKA, Paulina and ZIMNA, Aleksandra. Migraine headaches as a complication of the atrial fibrillation ablation procedure: case report. *Journal of Education, Health and Sport*. 2023;42(1):52-62. eISSN 2391-8306. DOI <http://dx.doi.org/10.12775/JEHS.2023.42.01.005> <https://apcz.umk.pl/JEHS/article/view/44113> <https://zenodo.org/record/8088797>

The journal has had 40 points in Ministry of Education and Science of Poland parametric evaluation. Annex to the announcement of the Minister of Education and Science of December 21, 2021. No. 32343. Has a Journal's Unique Identifier: 201159. Scientific disciplines assigned: Physical Culture Sciences (Field of Medical sciences and health sciences); Health Sciences (Field of Medical Sciences and Health Sciences). Punkty Ministerialne z 2019 - aktualny rok 40 punktów. Załącznik do komunikatu Ministra Edukacji i Nauki z dnia 21 grudnia 2021 r. Lp. 32343. Posiada Unikatowy Identyfikator Czasopisma: 201159. Przypisane dyscypliny naukowe: Nauki o kulturze fizycznej (Dziedzina nauk medycznych i nauk o zdrowiu); Nauki o zdrowiu (Dziedzina nauk medycznych i nauk o zdrowiu).  
© The Authors 2023;  
This article is published with open access at License Open Journal Systems of Nicolaus Copernicus University in Torun, Poland  
Open Access. This article is distributed under the terms of the Creative Commons Attribution Noncommercial License which permits any noncommercial use, distribution, and reproduction in any medium, provided the original author (s) and source are credited. This is an open access article licensed under the terms of the Creative Commons Attribution Non commercial license Share alike. (<http://creativecommons.org/licenses/by-nc-sa/4.0/>) which permits unrestricted, non commercial use, distribution and reproduction in any medium, provided the work is properly cited.  
The authors declare that there is no conflict of interests regarding the publication of this paper.  
Received: 22.05.2023. Revised: 15.06.2023. Accepted: 25.06.2023. Published: 29.06.2023.

## **Migraine headaches as a complication of the atrial fibrillation ablation procedure: case report**

**Michał Sekuła** - corresponding author

Neurology Department, Independent Public Clinical Hospital No.4 in Lublin, Jaczewskiego 8 Street, 20-954 Lublin, Poland

<https://orcid.org/0000-0001-8378-9964> e-mail: [michalsekula@onet.pl](mailto:michalsekula@onet.pl)

**Piotr Pawluccki**

The John Paul II Hospital in Krakow, Prądnicza 80 Street, 31-202 Krakow, Poland

<https://orcid.org/0009-0008-9600-2049> e-mail: [pawluckipiotr@gmail.com](mailto:pawluckipiotr@gmail.com)

**Anna Maciak**

5 The Military Clinical Hospital with Polyclinic in Krakow, Wrocławska 1/3 Street, 30-901 Krakow, Poland

<https://orcid.org/0009-0004-4227-6168> e-mail: [annamaciak97@gmail.com](mailto:annamaciak97@gmail.com)

**Jacob Chyła**

NZOZ Kozłówek in Krakow, Na Kozłowce 29 Street, 30-664 Krakow, Poland

<https://orcid.org/0009-0007-6242-393X> e-mail: [jacobchyla@gmail.com](mailto:jacobchyla@gmail.com)

**Krzysztof Smoluchowski**

Anesthesiology and Intensive Care Department, Provincial Specialist Hospital, Aleja  
Kraśnicka 100 Street, 20-718 Lublin, Poland

<https://orcid.org/0000-0001-9237-3346> e-mail: [ksmoluchowski@gmail.com](mailto:ksmoluchowski@gmail.com)

**Dorota Sokół**

Pediatric Neurology Department, Children's Clinical Hospital, Gębali 6 Street, 20-093  
Lublin, Poland

<https://orcid.org/0000-0003-2059-7951> e-mail: [dorotasokol9606@gmail.com](mailto:dorotasokol9606@gmail.com)

**Paulina Piotrowska**

Pediatric Hemato-oncology Department, Children's Clinical Hospital, Gębali 6 Street, 20-093  
Lublin, Poland

<https://orcid.org/0000-0002-5516-952X> e-mail: [paulina.piotrowska222@gmail.com](mailto:paulina.piotrowska222@gmail.com)

**Aleksandra Zimna**

Hospital of the Ministry of Interior and Administration, Grenadierów 3 Street, 20-331 Lublin,  
Poland

<https://orcid.org/0000-0002-8712-3497> e-mail: [aleksandra\\_zimna97@wp.pl](mailto:aleksandra_zimna97@wp.pl)

**Abstract:**

The balloon cryoablation (CA) procedure is an established method for the permanent treatment of atrial fibrillation (AF). Like other surgical interventions, it is associated with the potential development of early and late complications, including neurological ones such as migraine. We report a case of migraine headaches after the CA procedure. 25-year-old man with paroxysmal AF, without comorbidities, underwent balloon CA. On the second day after the procedure, the patient developed visual symptoms typical of migraine aura. After 30 minutes, these symptoms disappeared and appeared classic migraine headache attack. Similar episodes occurred over the following days. A focal central nervous system lesion was ruled out and a diagnosis of migraine with aura was made. The patient received a typical migraine attack treatment. The attacks ceased within two weeks. 3 months later during the follow-up visit at the neurology clinic no abnormalities were detected.

We decided to check if the migraine is a rare complication of AF ablation surgery. Many studies do not include migraine headaches at all in the neurological complications of ablation. However, based on some studies, it may seem that the incidence of migraine as a complication of ablation is underestimated.

**Keywords:** migraine; neurological complications; ablation; atrial fibrillation; foramen ovale

### **Introduction:**

Atrial fibrillation (AF) is the most common heart rhythm disorder in the adult population [1]. There are several subdivisions of AF, one of which is the division into paroxysmal, persistent and permanent AF [1]. In paroxysmal AF, abnormal imaging findings that may be indicative of organic heart disease are less common than in persistent and permanent AF, and its common cause is pathological electrical activity in the region of the pulmonary vein outlet to the left atrium [1]. A way to permanently treat this tachyarrhythmia is percutaneous ablation, which involves destroying the electrical connections that cause re-entry loops and electrical storms [1,2]. One new option is the balloon cryoablation procedure, which is an established treatment method for atrial fibrillation [1,2,3,4].

Like other surgical interventions, this procedure is associated with the potential for the development of early and late complications, such as injection site complications, phrenic nerve injury, tamponade or fluid in the pericardial sac, (pulmonary or bronchial complication), and neurological disorders [1,2]. The latter include ischaemic stroke, TIA, intracerebral haemorrhage, and migraine [5,6,7,8].

Migraine headaches are among the rare complications of AF ablation surgery [5,6]. In many cases, they are even overlooked in studies on the subject [2], although it can be inferred from a small number of papers that their incidence rate may be higher [5,6,9].

Once the more common neurological complications of AF ablation surgery have been ruled out, it is important to remember to direct the diagnostic process towards migraine. The key to its diagnosis is taking a thorough medical history and considering the International Headache Society (IHS) criteria [10]. Performing imaging studies is not necessary to make the diagnosis, and EEG examination, despite frequent paroxysmal changes, adds little to the diagnostic process [10,11].

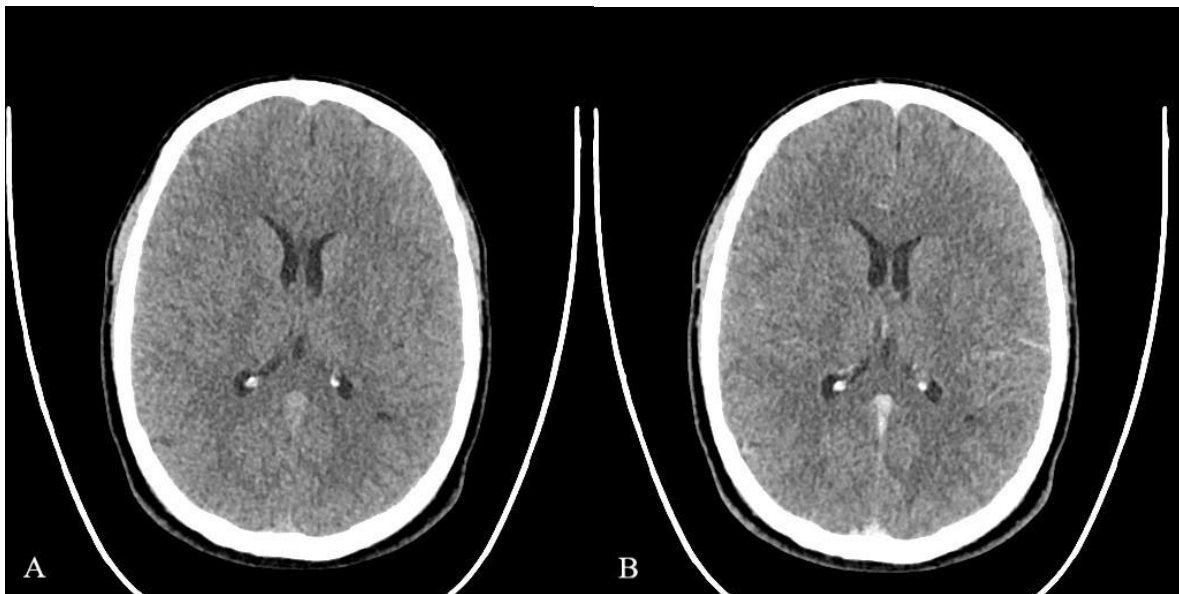
**Case report:**

A 25-year-old man with a history of paroxysmal atrial fibrillation (AF) was scheduled for balloon cryoablation of AF. Prior to the procedure, the patient had been on continuous rivaroxaban 20 mg 1x1 for 4 weeks. He presented no history of migraine episodes or other comorbidities. On admission, ECG showed sinus rhythm, regular heart rate (NSR) of approximately 60/min. Preoperative echocardiography confirmed no thrombus, non-enlarged atria and no other significant changes. An atrial fibrillation balloon cryoablation procedure was performed - pulmonary vein isolation.

Procedure description: An electrode was inserted into the right atrium via the inferior vena cava (RV/SVC) during sinus rhythm, which alternated with short episodes of atrial fibrillation. An Arctic Front Advance (2AF283) French - 10.5 mm cryoablation catheter was inserted into the left atrium by transseptal puncture. Unfractionated heparin and 1 ampoule of Fentanyl were administered. Ablation - balloon cryoablation (pulmonary vein isolation) was performed. Pulmonary vein cryoablation parameters: left superior pulmonary vein (LSPV) (240s - 44oC), left inferior pulmonary vein (LIPV) (240s - 44oC), right superior pulmonary vein (RSPV) (240s - 37oC), joint outlets of right middle pulmonary vein and right inferior pulmonary vein (RMPV/RIPV) (240s - 37oC). Blood pressures during the procedure were 120/62, 96/60 and 120/60 mmHg. The procedure lasted 85 minutes. The perioperative and early postoperative period were uncomplicated. The patient was discharged from the ward in good general condition and instructed to take rivaroxaban 20 mg 1x1 for a minimum of 4 weeks and bisoprolol 2.5 mg 1x1.

On the second postoperative day, the patient suddenly developed visual disturbances in the form of blurred vision and the occurrence of a flickering glare, which then evolved into left-sided anopia. The episode lasted for about 30 minutes, after which the visual complaints disappeared completely, but a severe, throbbing, unilateral headache appeared, localised to the left orbital region and increasing on exertion. The pain was accompanied by nausea, fatigue, photophobia and phonophobia. The pain subsided after several hours of sleep and the administration of paracetamol. Over the following days, episodes with a similar course occurred three times. In addition, during one of the episodes, sensory complaints consisting of a feeling of numbness in the lateral part of the left upper limb occurred, however they spontaneously subsided without any permanent disturbances.

The patient presented to the emergency room, where blood pressure was measured - 139/80 mmHg, heart rate (HR) 84/min. On neurological examination: patient conscious, auto- and allopsychic orientation correct, meningeal signs negative, very discrete L>P anisocoria, sluggish indirect consensual response of the left eye upon illumination of the right eye, no obvious Relative Afferent Pupillary Defect (RAPD), without other cranial nerve abnormalities, strength and muscle tone normal, deep tendon reflexes moderately vivid, symmetrical, no sensory disturbances, no ataxia, no pathological reflexes, Romberg test normal, gait normal. A computed tomography (CT) scan of the head with contrast was performed to rule out another cause of the symptoms; this examination did not show extravasated blood, foci of pathological enhancement after contrast administration, or other abnormalities (shown in **Fig. 1**).



**Fig. 1.** Computed tomography imaging before administering the contrast (**a**) and after administering the contrast (**b**). There are no signs of bleeding and focal damage of central nervous system.

In view of the characteristic history, clinical presentation and the absence of abnormalities on imaging, a diagnosis of migraine with aura was made. Adjunct use of 1000 mg paracetamol or a combined preparation of acetylsalicylic acid (ASA)+paracetamol+caffeine or zolmitriptan 5 mg sublingually was prescribed; bisoprolol was substituted for metoprolol 50

mg 1x1. Treatment with rivaroxaban was maintained. The patient was discharged home in good condition.

A single episode of lesser severity and shorter duration occurred within a week of the emergency room visit. After this time, the patient denied a recurrence of symptoms. After consultation with a cardiologist, rivaroxaban was discontinued 4 weeks after the cryoablation procedure and metoprolol was discontinued one month after the last seizure. As advised, the patient had a follow-up visit at the neurology clinic 3 months later. The patient reported that taking paracetamol or a combined preparation of ASA+paracetamol+caffeine have resulted a slight reduction in pain. After taking a Zolmitriptan the migraine headaches have subsided.

No abnormalities or complications were detected during the visit. The diagnosis of migraine was completed. Since then, no migraine attacks or other concerning neurological symptoms have been reported. On transthoracic echocardiography (TTE), atrial septal thinning was observed in the  $\frac{2}{3}$  of the distal atrial septum over a distance of approximately 0.5 cm, without echocardiographic signs of leakage, otherwise without significant pathology: left ventricular dimensions 53.5/29 mm, left atrium 37 mm, right atrium 37/39 mm, ejection fraction (EF) 66%. Transesophageal echocardiography (TEE) was proposed to the patient but he refused to undergo the examination. Considering the examination and clinical symptoms, an atrial septal defect can be excluded with high probability, but transoesophageal echocardiography with contrast has been recommended in case of recurrent migraine attacks, as it is the conclusive test for the assessment of atrial septal defects [12].

## **Discussion:**

A common cause of paroxysmal atrial fibrillation is pathological electrical activity in the region of the pulmonary vein outlet to the left atrium [1]. Treatment prevents the conduction of electrical impulses to the distal parts of the atria and thus interrupts the initiation of atrial fibrillation [1]. One method is radiofrequency ablation. Its effectiveness in maintaining sinus rhythm compared to pharmacotherapy has been confirmed in randomised trials [1,3,7]. Radiofrequency ablation is dependent on the skill of the operator, so a simpler method of cryoablation has been developed and has become one of the primary procedures for the treatment of paroxysmal atrial fibrillation [1,2]. Currently, the use of cryoablation is not associated with a greater risk to the patient than the use of radiofrequency ablation [2]. A study performed with second-generation cryoballoons shows an efficacy of 79.2% in maintaining sinus rhythm after 2 years [3] and 59.0% after 5 years [4]. Worse results have

been obtained in patients with permanent atrial fibrillation, an enlarged left atrium, and diabetes mellitus [3,4].

The ablation procedure may be associated with numerous complications such as local complications at the insertion site, phrenic nerve injury, tamponade or fluid in the pericardial sac, (pulmonary or bronchial complication), transient neurological disorders, (dyspnea), (thromboembolism) [2].

On the basis of the patient's history, physical examination and additional investigations described in the case report, a diagnosis of migraine with aura was made. It is a rare complication of ablation [5,6]. Two studies from 2010 and 2011 can be found among the publications on this topic. In the first, the study group consisted of 2,069 people; there were complications of headache (2.3%), including newly diagnosed migraine (1.1%), probable newly diagnosed migraine (0.6%) and recurrent headache with a history of migraine (0.4%) [5]. In the second study, the study group comprised 571 patients, and migraine complications occurred in three patients, representing approximately 0.5% [6]. These are among the few studies linking the occurrence of newly diagnosed migraine to AF ablation.

Complications related to (thromboembolism) such as stroke or TIA are more commonly described in the literature [2,7,13]. One of many articles is a meta-analysis comprising 18 studies and a total of 5513 patients. The incidence of complications related to (thromboembolism) during anticoagulant treatment can be 0.12% (warfarin) and 0.65% (dabigatran) [13]. According to another study involving an even larger group of patients (67090 hospitalisations), acute cerebrovascular disorders may occur in 0.8 % of cases, in which stroke accounts for 73 % of them, TIA 24 % and haemorrhage 2 % [7].

According to one study, the incidence of newly diagnosed migraine in patients after ablation can be up to 8% [9]. However, we realise that such a high percentage may be due to the small sample size (87 patients) and the non-standardised symptom questionnaire [9].

Considering the available studies, it could be assumed that migraine complications may occur with similar frequency or even more frequently than TIA, but it may be too hasty to draw such conclusions on the basis of single studies. Large studies assessing the incidence of both complications in a single group of patients to compare their frequency are lacking.

The large effects that a stroke episode may cause make it necessary to focus on the urgent exclusion of an ischaemic episode in the ED or emergency room in patients after AF ablation. The neurological symptoms of a migraine and an ischaemic episode may be similar in many cases [8]. According to 61 studies involving 62664 participants, the proportion resembling ischaemic stroke was 24.8 %, of which 7.76 % constituted migraine [8]. Thus, once an

ischaemic or haemorrhagic episode within the central nervous system has been ruled out, it is important to remember to carry out a diagnosis of migraine as a complication after AF ablation.

Despite years of research and considerable progress, the etiology of migraine is still unclear [10]. A genetically determined, multigene channelopathy is considered to be the primary cause, and a secondary cause is a particular propensity for increased vasomotor activity [10]. Studies in which there is a correlation between a higher incidence of migraines and a persistent foramen ovale should be considered [5,14,15]. The formation of an iatrogenic atrial septal defect may cause right-left leakage similar to a persistent foramen ovale and thus increase the risk of migraine [5,6,9,14]. However, the mechanism by which right-left leakage would lead to migraine attacks is unknown, but hypotheses exist to explain this relationship [5,6,14,15]. Episodes of headaches with or without aura may only be a temporary condition, perhaps due to a change in haemodynamic conditions after the ablation procedure.

According to a meta-analysis involving 1165 patients, an improvement in migraine symptoms can be observed after closure of the persistent foramen ovale [14].

### **Conclusion:**

Further research is needed to uncover the exact mechanisms underlying migraines, as well as linking their occurrence to undergoing ablation surgery. Nevertheless, studies on a large group of patients that would show the epidemiological foundation of neurological complications after AF ablation are also important. Indeed, the results of some studies conducted so far may suggest that the incidence of migraine headaches after ablation is underestimated [5,6,9].

### **Disclosures:**

Financial support: No financial support was received

Conflict of interest: The authors declare no conflict of interest

### **Bibliography:**

1. Margulescu AD, Mont L. Persistent atrial fibrillation vs paroxysmal atrial fibrillation: differences in management. *Expert Rev Cardiovasc Ther.* 2017 Aug;15(8):601-618. doi: 10.1080/14779072.2017.1355237. Epub 2017 Jul 31. PMID: 28724315.



2. Kuck KH, Brugada J, Fürnkranz A, Metzner A, Ouyang F, Chun KR, Elvan A, Arentz T, Bestehorn K, Pocock SJ, Albenque JP, Tondo C; FIRE AND ICE Investigators. Cryoballoon or Radiofrequency Ablation for Paroxysmal Atrial Fibrillation. *N Engl J Med*. 2016 Jun 9;374(23):2235-45. doi: 10.1056/NEJMoa1602014. Epub 2016 Apr 4. PMID: 27042964.
3. Akkaya E, Berkowitsch A, Zaltsberg S, Greiss H, Hamm CW, Sperzel J, Neumann T, Kuniss M. Second-generation cryoballoon ablation as a first-line treatment of symptomatic atrial fibrillation: Two-year outcome and predictors of recurrence after a single procedure. *Int J Cardiol*. 2018 May 15;259:76-81. doi: 10.1016/j.ijcard.2017.11.011. PMID: 29579615.
4. Akkaya E, Berkowitsch A, Zaltsberg S, Greiss H, Hamm CW, Sperzel J, Kuniss M, Neumann T. Five-year outcome and predictors of success after second-generation cryoballoon ablation for treatment of symptomatic atrial fibrillation. *Int J Cardiol*. 2018 Sep 1;266:106-111. doi: 10.1016/j.ijcard.2018.03.069. PMID: 29887425.
5. Noheria A, Roshan J, Kapa S, Srivathsan K, Packer DL, Asirvatham SJ. Migraine headaches following catheter ablation for atrial fibrillation. *J Interv Card Electrophysiol*. 2011 Apr;30(3):227-32. doi: 10.1007/s10840-010-9519-z. Epub 2010 Oct 19. PMID: 20957420.
6. Chilukuri K, Sinha S, Berger R, Marine JE, Cheng A, Nazarian S, Scherr D, Spragg D, Calkins H, Henrikson CA. Association of transeptal punctures with isolated migraine aura in patients undergoing catheter ablation of cardiac arrhythmias. *J Cardiovasc Electrophysiol*. 2009 Nov;20(11):1227-30. doi: 10.1111/j.1540-8167.2009.01525.x. Epub 2009 Jun 26. PMID: 19563357.
7. Patil N, Arora S, Davis L, Akoum NW, Chung MK, Sridhar AR. Incidence and Predictors of 30-day Acute Cerebrovascular Accidents Post Atrial Fibrillation Catheter Ablation (From the Nationwide Readmissions Database). *Am J Cardiol*. 2021 Jan 1;138:61-65. doi: 10.1016/j.amjcard.2020.10.020. Epub 2020 Oct 13. PMID: 33058801.

8. Pohl M, Hesszenberger D, Kapus K, Meszaros J, Feher A, Varadi I, Pusch G, Fejes E, Tibold A, Feher G. Ischemic stroke mimics: A comprehensive review. *J Clin Neurosci*. 2021 Nov;93:174-182. doi: 10.1016/j.jocn.2021.09.025. Epub 2021 Sep 20. PMID: 34656244
9. Jordaens L, Janse P, Szili-Torok T, Van Belle Y. Migraine accompagnée after transeptal puncture. *Neth Heart J*. 2010 Aug;18(7-8):374-5. doi: 10.1007/BF03091795. PMID: 20730006; PMCID: PMC2922785.
10. Khan J, Asoom LIA, Sunni AA, Rafique N, Latif R, Saif SA, Almandil NB, Almohazey D, AbdulAzeez S, Borgio JF. Genetics, pathophysiology, diagnosis, treatment, management, and prevention of migraine. *Biomed Pharmacother*. 2021 Jul;139:111557. doi: 10.1016/j.biopha.2021.111557. Epub 2021 May 17. PMID: 34243621.
11. Evans RW. Diagnostic Testing for Migraine and Other Primary Headaches. *Neurol Clin*. 2019 Nov;37(4):707-725. doi: 10.1016/j.ncl.2019.08.001. Epub 2019 Aug 31. PMID: 31563228
12. Soliman OI, Geleijnse ML, Meijboom FJ, Nemes A, Kamp O, Nihoyannopoulos P, Masani N, Feinstein SB, Ten Cate FJ. The use of contrast echocardiography for the detection of cardiac shunts. *Eur J Echocardiogr*. 2007 Jun;8(3):S2-12. doi: 10.1016/j.euje.2007.03.006. Epub 2007 Apr 25. PMID: 17462958.
13. Sardar P, Nairooz R, Chatterjee S, Wetterslev J, Ghosh J, Aronow WS. Meta-analysis of risk of stroke or transient ischemic attack with dabigatran for atrial fibrillation ablation. *Am J Cardiol*. 2014 Apr 1;113(7):1173-7. doi: 10.1016/j.amjcard.2013.12.027. Epub 2014 Jan 15. PMID: 24513472
14. Zhang Y, Wang H, Liu L. Patent Foramen Ovale Closure for Treating Migraine: A Meta-Analysis. *J Interv Cardiol*. 2022 Feb 2;2022:6456272. doi: 10.1155/2022/6456272. PMID: 35185398; PMCID: PMC8828350.

15. Kumar P, Kijima Y, West BH, Tobis JM. The Connection Between Patent Foramen Ovale and Migraine. *Neuroimaging Clin N Am*. 2019 May;29(2):261-270. doi: 10.1016/j.nic.2019.01.006. PMID: 30926116.