

GRUSZCZYŃSKA, Michalina, JARZEMSKI, Adam, KOLOSSA, Agnieszka, PORZYCH, Rafał, MARZYŃSKA, Dorota, DEPCZYŃSKA, Michalina, GRUSZKA, Beata & GRUSZKA, Alicja. Contact dermatitis to acrylates and secondary nail fungal infection in 22 year old female patient – a case report. *Journal of Education, Health and Sport*. 2023;26(1):37-42. eISSN 2391-8306. DOI <http://dx.doi.org/10.12775/JEHS.2023.26.01.005>  
<https://apcz.umk.pl/JEHS/article/view/43561>  
<https://zenodo.org/record/7896373>

The journal has had 40 points in Ministry of Education and Science of Poland parametric evaluation. Annex to the announcement of the Minister of Education and Science of December 21, 2021. No. 32343. Has a Journal's Unique Identifier: 201159. Scientific disciplines assigned: Physical Culture Sciences (Field of Medical sciences and health sciences); Health Sciences (Field of Medical Sciences and Health Sciences). Punkty Ministerialne z 2019 - aktualny rok 40 punktów. Załącznik do komunikatu Ministra Edukacji i Nauki z dnia 21 grudnia 2021 r. Lp. 32343. Posiada Unikatowy Identyfikator Czasopisma: 201159. Przynależność dyscypliny naukowej: Nauki o kulturze fizycznej (Dziedzina nauk medycznych i nauk o zdrowiu); Nauki o zdrowiu (Dziedzina nauk medycznych i nauk o zdrowiu). © The Authors 2023; This article is published with open access at Licensee Open Journal Systems of Nicolaus Copernicus University in Torun, Poland Open Access. This article is distributed under the terms of the Creative Commons Attribution Noncommercial License which permits any noncommercial use, distribution, and reproduction in any medium, provided the original author (s) and source are credited. This is an open access article licensed under the terms of the Creative Commons Attribution Non commercial license Share alike. (<http://creativecommons.org/licenses/by-nc-sa/4.0/>) which permits unrestricted, non commercial use, distribution and reproduction in any medium, provided the work is properly cited. The authors declare that there is no conflict of interests regarding the publication of this paper. Received: 13.04.2023. Revised: 20.04.2023. Accepted: 04.05.2023. Published: 04.05.2023.

## Contact dermatitis to acrylates and secondary nail fungal infection in 22 year old female patient – a case report

Michalina Gruszczyńska<sup>1</sup>, Adam Jarzemski<sup>1</sup>, Agnieszka Kolossa<sup>1</sup>, Rafał Porzych<sup>2</sup>, Dorota Marzyńska<sup>3</sup>, Michalina Depczyńska<sup>4</sup>, Beata Gruszka<sup>5</sup>, Alicja Gruszka<sup>5</sup>

1. Jan Bizieli University Hospital No. 2 in Bydgoszcz
2. Nicolaus Copernicus University in Toruń, Collegium Medicum in Bydgoszcz.
3. Lower Silesian Oncology, Pulmonology and Hematology Center in Wrocław
4. Norbert Barlicki Memorial Teaching Hospital no. 1 of the Medical University of Lodz
5. Antoni Jurasz University Hospital No. 1 in Bydgoszcz

Michalina Gruszczyńska  
ORCID: 0009-0002-3321-9626  
[michalina.gruszczyńska97@gmail.com](mailto:michalina.gruszczyńska97@gmail.com)

Adam Jarzemski  
ORCID: 0009-0002-0217-3696  
[adam.jarzemski@gmail.com](mailto:adam.jarzemski@gmail.com)

Agnieszka Kolossa  
ORCID: 0009-0008-4968-5721  
[agnieszkakolossa@gmail.com](mailto:agnieszkakolossa@gmail.com)

Rafał Porzych  
ORCID: 0009-0007-3815-8793  
[rafal.porzych@gmail.com](mailto:rafal.porzych@gmail.com)

Dorota Marzyńska  
ORCID: 0009-0002-1657-4669  
[dormarzyńska@gmail.com](mailto:dormarzyńska@gmail.com)

Michalina Depczyńska  
ORCID: 0009-0000-4505-3921  
[depczyńskamichalina@gmail.com](mailto:depczyńskamichalina@gmail.com)

Beata Gruszka  
ORCID: 0009-0001-2197-5566  
[beatagruszka96@op.pl](mailto:beatagruszka96@op.pl)

Alicja Gruszka  
ORCID: 0009-0008-3697-3353  
alicja.gruszka@op.pl

## **Abstract**

Contact dermatitis is an inflammatory skin disease resulting from repeated contact with allergens or irritants. Prevalence of adverse reactions to acrylates monomers is still rising due to their wide use in medical and cosmetics industry. The nail symptoms, including e.g. onycholysis, hyperkeratosis or nail plate discoloration can be indicative of different diagnoses like psoriasis, mycobacterial infections or contact dermatitis. Diagnosis is not always obvious, as exemplified by the patient's history. The aim of the study was to describe a case of contact dermatitis to acrylates associated with secondary fungal nail infection. Moreover article reviews the pathogenesis, clinical manifestation, diagnosis and treatment methods of contact dermatitis induced by acrylates.

**Keywords:** contact dermatitis, acrylates, fungal infection, mycosis, patch testing

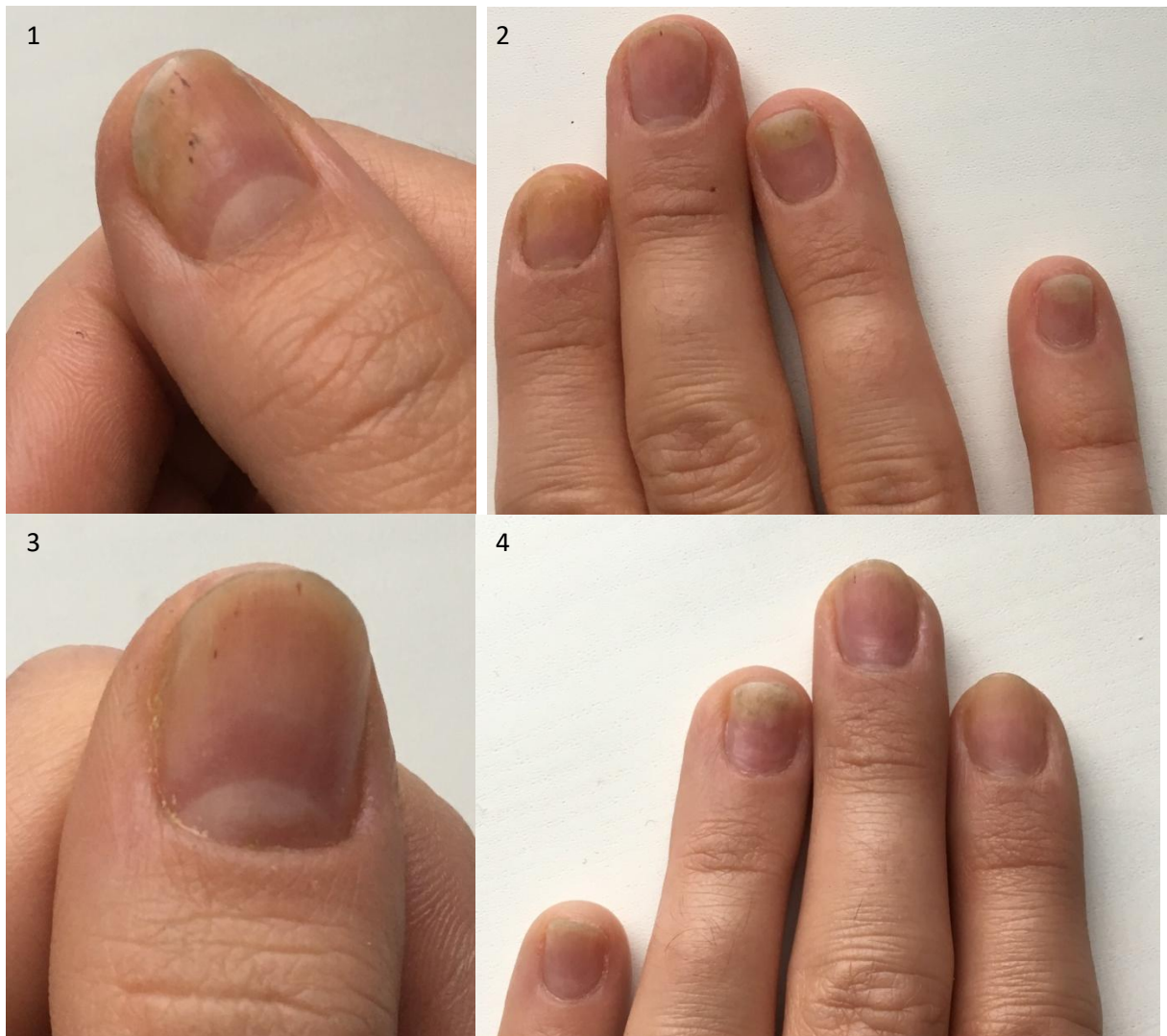## **Introduction**

Contact dermatitis is an inflammatory skin disorder resulting from repeated contact with either allergens or irritants, leading to the development of allergic or irritant contact dermatitis. Most often hands, face and feet are affected. [1] Up to 15% of population suffers from contact dermatitis over a lifetime. [2] The majority of cases (80%) suffer from irritant contact dermatitis (ICD), which results from damage to keratins, cell membranes or skin lipids by substances including e.g. alcohol or acetone. Genetic predisposition might play a role in ICD development, as well as presence of skin conditions in pathogenesis of which skin barrier is damaged, for example atopic dermatitis. [1] 20% of cases suffer from allergic contact dermatitis (ACD) which results from type IV delayed hypersensitivity reaction. Langerhans and helper T-cell activation leads to formation of memory T-cells, and in case of re-exposure pro-inflammatory cytokines are produced and inflammatory symptoms appear. In case of allergic contact dermatitis patch testing is recommended. [3] Allergic contact dermatitis reactions can be either acute – in such cases symptoms include erythema, vesicles and crusting or chronic, with the presence of lichenification, skin cracking and scaling.

Acrylate monomers allergy has been often described in cases in dentistry industry, however recently due to wide use in cosmetology, new forms of contact dermatitis appear. Acrylate monomers have allergenic properties, therefore their proper polymerization is crucial in avoiding side effects. Acrylate monomers polymerization occurs either under ultraviolet light exposure or spontaneously. Polymers are believed to be non-allergic, however sometimes monomers can be released from them. Due to frequent domestic use of acrylic nail kits, using non-professional products including non-professional ultraviolet lamp, which is unable to transform acrylate monomers into polymers properly, the incidence of contact dermatitis to acrylates increases.[4]

## Case presentation

A 22 year old female patient was admitted to the outpatient department of Dermatology and Venereology complaining about nail changes. She presented the symptoms of yellow discoloration of nail plate and onycholysis present on all hand fingers and five feet fingers. Moreover in physical examination elevation of nail plate and splinter haemorrhages were detected, however there were no signs of inflammation (paronychia), including pain, edema, redness or warming. Pictures showing affected nails are presented below the text as Figures 1-5. Patient had a history of three and a half year exposure to hybrid varnishes, applied at home regularly once every three weeks with the use of home acrylic nail kit. Symptoms developed within one month period. Suspecting fungal infection, patient applied nail polish with amorolfinum for two months, however further nail changes development was observed what eventually led to visiting the doctor. After physical examination was performed, a scrap from nail plate was taken for mycological tests and treatment was modified to nail polish with ciclopiroxum, furthermore the necessity of nail painting withdrawal was marked. New treatment method was successful, moreover the mycological test results received after a month revealed the presence of fungus *Throdotorula rubra*, what motivated the effectiveness of the therapy. After few months symptoms subsided when new nail plate replaced the old one.



Figures 1-2 presenting nail plates of right hand, figures 3-4 presenting nail plates of left hand. Symptoms include yellow discoloration, subungual hyperkeratosis, onycholysis and splinter haemorrhages.

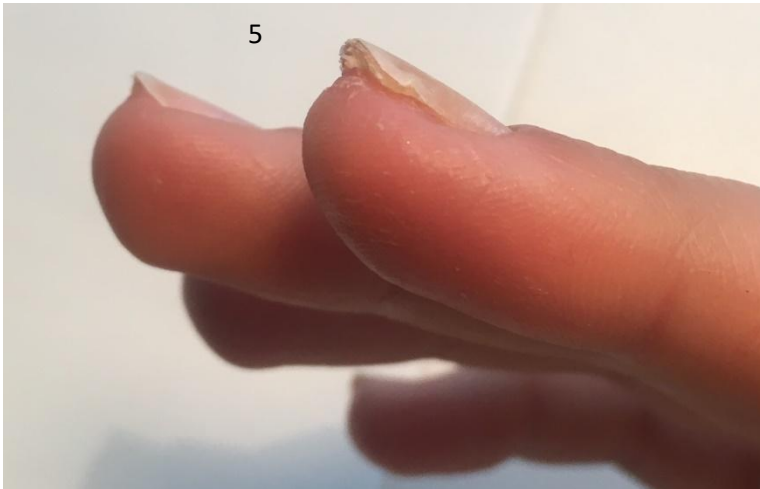


Figure 5 presents following symptoms: subungual hyperkeratosis and nail plate elevation.

One year after first symptoms appeared, patient applied hybrid nail polish again. After one week subungual hyperkeratosis was observed with the elevation of nail plate. Nail polish was immediately removed and patient made an appointment at the dermatologist again. The doctor, after considering the previous medical history, has recommended to perform the patch testing for different allergens, including acrylates present in hybrid nail varnishes. Allergen panels were applied on the skin of the back, after 48 hours panels were removed and first reading was performed, after next 24 hours final reading was performed. The test revealed to be positive for 2-hydroxyethyl methacrylate (HEMA), ethylene glycol dimethylacrylate (EGDMA) and gold sodium thiosulfate, patient was diagnosed with contact dermatitis to these allergens and avoiding them was recommended. It was deduced that fungal infection one year earlier must have developed secondary to the weakened nail plate due to contact dermatitis. Hybrid varnishes avoidance was an effective treatment, however the whole inflammatory process led to the shortening and fragility of nail plates, which are now prone to fractures. The current appearance of nail plates is presented in Figure 6.

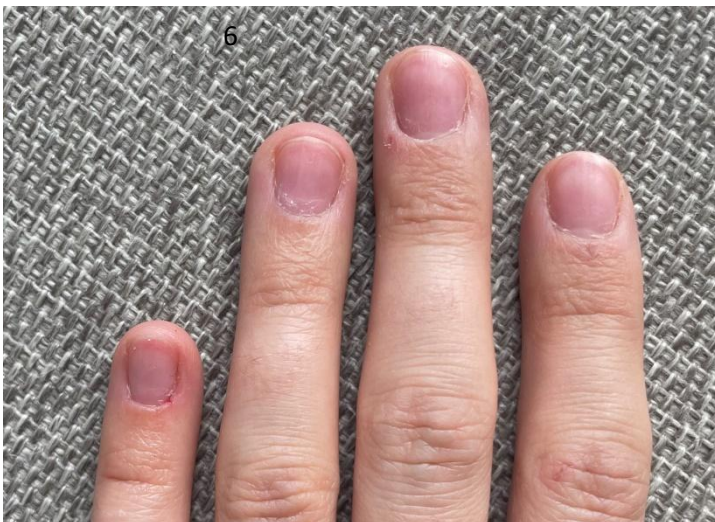


Figure 6 – current appearance of nail plates, with visible shortening of nail plate especially in ring finger.

## Discussion

There were few similar cases already described in Poland. All the patients had a history of performing hybrid manicure using home acrylic nail kit for the period of time ranging from one month to three years.[5] Patients

presented with various symptoms, including onycholysis, subungual hyperkeratosis, nail plate elevation, oedema, exfoliating erythema, crusting, shortening of the nail plate, whitening and thinning of nail plates, splinter haemorrhages or secondary fungal and bacterial infections. Onycholysis was most often detected, moreover every patient suffered from intense pruritus in affected area. There was a positive correlation found between severity of the symptoms and the time of exposure.

Moreover in literature it is mentioned, that symptoms may appear on distant sites of the body as well, including e.g. eyelids and face, and this may be due to airborne dust released from acrylate polymers.[6]

Differential diagnoses, which need to be excluded in the process of examination, include psoriasis, primary fungal infections, mechanical damage. In order to exclude psoriasis, family history of psoriasis should be considered, moreover presence of other autoimmune disorders should be excluded. Patient's skin should be examined to evaluate presence of psoriatic lesions, in doubtful cases skin biopsy can be taken. Fungal infections can be excluded using mycological tests. Moreover symptoms of both psoriasis and fungal infection usually concern few nail plates, whereas it is typical for contact dermatitis that all 10 fingernails are affected.

Moreover cosmetic procedures may lead to development of many symptoms, which do not have to be associated with contact dermatitis, even though symptoms are similar. They include discoloration of nail plate, mechanical onycholysis, keratin degranulation, worn-down nails, peripheral neuropathy, nail thinning. Last but not least, the risk of developing malignant neoplasm after the UV lamp exposure is nowadays assessed to be low, nevertheless we should remember about such possibility. [7]

The sufficient treatment of contact dermatitis to acrylates is avoiding anything that may contain these allergens. Patients are advised to avoid following products: nail varnishes with acrylates, false lashes glue, acrylates glue for prosthesis fixation, dental prostheses, bone cement in orthopaedics, contact lenses, hearing aids, surgical glue, glucose monitoring devices, insulin pumps, electrical insulation, printer ink, disposable diapers, incontinence pads, bandages. [4] In severe cases patients need to be treated with either topical or oral corticosteroids, mostly with a good response.[8]

## Conclusions

The prevalence of contact dermatitis to acrylates is constantly rising due to their wide use in medical and cosmetic procedures. Both professionals and patients should be aware of possible adverse reactions to acrylates, and the allergens should be avoided as soon as the symptoms appear. Proper diagnosis and consideration of possible differential diagnoses is crucial in therapeutic process.

Informed consent was obtained from the patient involved in the study.

The authors declare no conflict of interest.

The publication received no funding.

## Literature

1. Johansen JD, Bonefeld CM, Schwensen JFB, Thyssen JP, Uter W. Novel insights into contact dermatitis. *J Allergy Clin Immunol.* 2022;149(4):1162-1171. doi:10.1016/j.jaci.2022.02.002
2. Svensson, A., Ofenloch, R. F., Bruze, M., Naldi, L., Cazzaniga, S., Elsner, P., et al. Prevalence of skin disease in a population-based sample of adults from five European countries. *Br J Dermatol.* 2018;178(5):1111-1118. doi:10.1111/bjd.16248
3. Burkemper NM. Contact Dermatitis, Patch Testing, and Allergen Avoidance. *Mo Med.* 2015;112(4):296-300.
4. Kucharczyk M, Słowik-Rylska M, Cyran-Stemplewska S, Gieroń M, Nowak-Starz G, Kręcisz B. Acrylates as a significant cause of allergic contact dermatitis: new sources of exposure. *Postepy Dermatol Alergol.* 2021;38(4):555-560. doi:10.5114/ada.2020.95848
5. Opalińska S, Opalińska M, Rudnicka L, Czuwara J. Contact eczema induced by hybrid manicure. The role of acrylates as a causative factor. *Postepy Dermatol Alergol.* 2022;39(4):768-774. doi:10.5114/ada.2021.109684

6. Maio P, Carvalho R, Amaro C, Santos R, Cardoso J. Allergic contact dermatitis from sculptured acrylic nails: special presentation with an airborne pattern. *Dermatol Reports*. 2012;4(1):e6. Published 2012 May 28. doi:10.4081/dr.2012.e6
7. Rieder EA, Tosti A. Cosmetically Induced Disorders of the Nail with Update on Contemporary Nail Manicures. *J Clin Aesthet Dermatol*. 2016;9(4):39-44.
8. Gatica-Ortega ME, Pastor-Nieto MA, Silvestre-Salvador JF. Allergic Contact Dermatitis Caused by Acrylates in Long-Lasting Nail Polish. *Dermatitis alérgica de contacto por acrilatos en esmaltes permanentes*. *Actas Dermosifiliogr (Engl Ed)*. 2018;109(6):508-514. doi:10.1016/j.ad.2017.08.010