

Nikitenko R. P., Kosovan V. M., Vorotyntseva K. O., Koichev E. A. Rationale for extent of operation choice in rectal cancer. *Journal of Education, Health and Sport*. 2021;11(11):423-432. eISSN 2391-8306. <https://apcz.umk.pl/JEHS/article/view/40340>
<https://zenodo.org/record/7144986>

The journal has had 5 points in Ministry of Science and Higher Education parametric evaluation. § 8.2) and § 12.1.2) 22.02.2019.

© The Authors 2021;

This article is published with open access at Licensee Open Journal Systems of Nicolaus Copernicus University in Torun, Poland
Open Access. This article is distributed under the terms of the Creative Commons Attribution Noncommercial License which permits any noncommercial use, distribution, and reproduction in any medium, provided the original author(s) and source are credited. This is an open access article licensed under the terms of the Creative Commons Attribution Non commercial license Share alike.
(<http://creativecommons.org/licenses/by-nc-sa/4.0/>) which permits unrestricted, non commercial use, distribution and reproduction in any medium, provided the work is properly cited.

The authors declare that there is no conflict of interests regarding the publication of this paper.

Received: 10.10.2021. Revised: 22.10.2021. Accepted: 30.11.2021.

UDC: 616.351-006.6-089.87-072.1

Rationale for extent of operation choice in rectal cancer

R. P. Nikitenko, V. M. Kosovan, K. O. Vorotyntseva, E. A. Koichev

Odessa National Medical University of the Ministry of Health of Ukraine

Nikitenko R. P., MD, PhD, Associate Professor of the Department of Surgery № 1, ORCID ID: 0000-0003-4214-5534

Kosovan V.M., MD, PhD, Associate Professor of the Department of Surgery № 1, ORCID ID: 0000-0001-6775-8463

Vorotyntseva K.O., PhD, Associate Professor of the Department of Surgery № 1, | ORCID ID: 0000-0003-1002-7015

Koichev E.A., PhD, Associate Professor of the Department of Surgery № 1, ORCID ID: 0000-0003-0212-0578

Abstract

Introduction. Colorectal cancer (CRC) remains relevant occupying one of the leading places in morbidity and mortality among oncological diseases. It reaches 13.5% in the structure of tumor diseases tending to increase.

The aim of the work to improve the choice of surgical treatment management and reduce the number of intraoperative and postoperative complications in rectal cancer patients.

Materials and methods. 184 operated patients with rectal cancer (RC) were divided into 2 groups: 1 group (patients with stage I RC (T1-2N0M0) and 2 group (stage II RC (T3N0M0)) who were carried out intraoperative detection and examination of sentinel lymph nodes. The volume and surgical approach depended on the stage and the presence of metastases (MTS). The average period of postoperative observation was 12–60 months,

taking into account early (purulent-septic complications, bleeding, intestinal perforation) and distant (recurrence of rectal cancer) complications.

Results. The patients of the 1 group had no MTS lesions of sentinel lymph nodes, due to this fact the surgical intervention was limited to transanal microsurgery. Among the complications were the following: bleeding – 2.2%; intraoperative perforation of the intestinal wall – 5.6%. No purulent-septic cases, no recurrences of rectal cancer were detected. In group 2, of 94 patients, 36 (38.3%) had MTS detected intraoperatively in sentinel lymph nodes which required a low anterior rectal resection with total mesorectectomy. Among the complications was bleeding – 6.3%. No intraoperative perforations of the intestinal wall and no purulent-septic complications were detected. Recurrence of rectal cancer was detected in 12 (13.8%) patients.

Conclusions. Performing transanal endoscopic resections in patients with RC I and especially stage II is possible only under the conditions of mandatory intraoperative staining and emergency histological examination of "sentinel" lymph nodes. The extent of surgical intervention is determined on the operating table based on the results of an emergency histological examination. When MTS lesions of the mesorectal "sentinel lymph nodes" are detected, the operation should be continued with mandatory mesorectectomy.

Key words: rectal cancer; sentinel lymph node; Indocyanine Green; transanal endoscopic microsurgery.

Introduction. Colorectal cancer (CRC) remains relevant occupying one of the leading places in morbidity and mortality among oncological diseases. It reaches 13.5% in the structure of tumor diseases tending to increase (Fig. 1) [1, 7, 16].

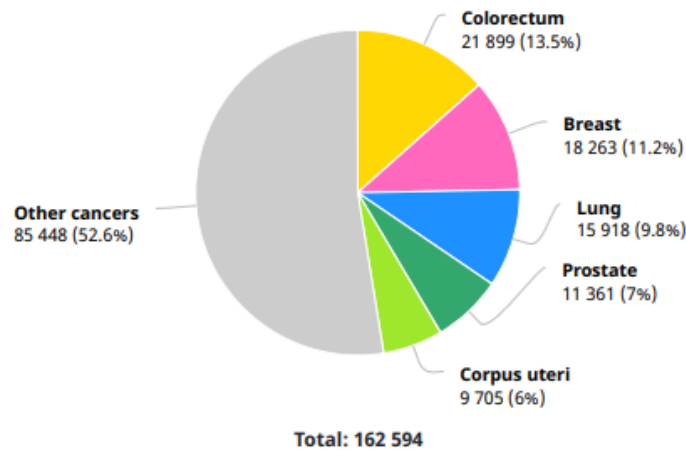
CRC ranks the second place. Every year, 800 thousand new cases of CRC and 500 thousand deaths from it are registered in the world. There is a clear trend to this disease spread both in the world and Ukraine, where 24 new cases of CRC are detected per 100,000 population. A particular danger lies in the fact that in almost 50% of patients the disease is diagnosed at late or advanced stages, and leads to unsatisfactory results, such as relapsed cancer [1, 6, 10].

According to randomized trials, the frequency of metastatic (MTS) lesions of the lymph nodes directly depends on the size of the tumor, so metastases in the lymph nodes are possible in patients with T1 tumors – from 0% to 12%, with T2 tumors – from 12% to 28%, with T3 tumors – from 36% to 79% [1, 5, 15, 16].

Ukraine

Source: Globocan 2020

Number of new cases in 2020, both sexes, all ages



Number of new cases in 2020, males, all ages

Figure 1. Colorectal cancer prevalence in Ukraine

The complexity lies in the fact that there are no clear clinical and laboratory data to accurately determine the presence or absence of metastatic lesions of the lymph nodes [1– 3]. Many authors state in their publications that the main criterion for determining the presence of metastases in the lymph nodes is its size [1, 5, 6]. However, the size of the lymph nodes does not always indicate if they involve in the tumor process or not [4, 12].

That is why the sentinel lymph node strategy is very actual in CRC surgery. It is the detection of the sentinel lymph node (SLN) that has an important prognostic value for determining further surgical management [1, 7].

The standard method of surgical treatment of patients with rectal cancer is total mesorectumectomy (TME), which provides regional control of the disease, and reduces the local recurrences rate to 5% [1, 10, 11, 14]. However, this operation is associated with increased term of patient's stay in the hospital, a high risk of intraoperative and postoperative complications, as well as a significant decrease in the patient's life quality [9, 15].

Surgical treatment of rectal cancer (RC) is predominantly represented by the following types of interventions: 1 – anterior resection of the rectum, 2 – abdominoanal resection, 3 – extirpation of the rectum.

An alternative to traditional methods of surgical treatment of patients with early RC (Tis, T1–T2) is the method of transanal endoscopic microsurgery (TEM).

Currently there are several methods of local removal of early rectal neoplasms (Tis, T1–T2) – endoscopic electroexcision, transanal excision of the tumor, transanal endoscopic microsurgery.

Each of these methods has its advantages and disadvantages, the most severe of which is the high probability of tumor recurrence, sometimes reaching 45 % [4]. One of the modern and frequently used methods of surgical treatment is TEM. It is the method of endoscopic resection of rectal neoplasms by the transanal access using special instruments developed by G. Buess in the early 1980s. This is an operating proctoscope (length – 15 – 20 cm, diameter – 4 cm), a working eyepiece with 5 ports for inserting an endoscopic microscope, an insufflator for injecting carbon dioxide into the rectum, an irrigator-aspirator, instruments for endoscopic manipulations [1, 8–10].

Aim of the research to improve the choice of surgical treatment management and reduce the number of intraoperative and postoperative complications in rectal cancer patients.

Material and methods. During the years 2009 to 2022, a retrospective analysis of treatment results of 375 rectal cancer patients was conducted at the Odesa Regional Clinical Hospital. The age of the patients ranged from 42 to 86 years. All the patients, depending on the operation performed, were divided into 2 groups. In group I, 184 (49.1%) patients had TEM. In group II, 191 (50.9%) patients had low anterior rectal resection with TME.

All the patients with diagnosed rectal cancer according to the preoperative biopsy results, obligatory according to indications, underwent neoadjuvant chemoradiotherapy. Before surgery all the patients were informed about possible intraoperative and postoperative complications. The informed consent for the operation was obtained from all the patients. Before surgery the patients had general clinical examinations, sigmoidoscopy, fibrocolonoscopy, irrigoscopy, transrectal ultrasound, multislice computed tomography (MCT) of the chest, abdomen and pelvic organs with intravenous contrast in order to determine the presence of distant metastases and enlarged lymph nodes. The conducted preoperative preparation met the standard. Mandatory prevention of venous thromboembolic (VTE) complications was carried out, including wearing compression stockings or elastic bandaging the lower extremities, low molecular weight heparins, and early activation after surgery.

All operations were performed under endotracheal anesthesia with patients in the supine position.

In group I (184 patients) RC stage I (T1-2N0M0) was diagnosed in 90 patients (48.9%). The age of the patients ranged from 42 to 86 years. RC stage II (T3N0M0) was diagnosed in 94 (51.1%) patients before surgery.

Depending on the RC stage the patients of the group I were subdivided into two subgroups: subgroup IA (the patients with RC stage I (T1-2N0M0)), subgroup IB (the patients with RC stage II (T3N0M0)).

Transanal endoscopic resections were performed using “Karl Storz TEO” surgical equipment. The standard TEM procedure was performed in group I. A special port was installed in the rectum for electrosurgical instruments. After carbon dioxide insufflation, the tumor resection zones were marked with an electrocoagulation hook with a distance of at least 10 mm from the tumor edges. Using a hook and “LigaSure” coagulator of the “Covidien” company, by layer tumor resection within healthy tissues was conducted. After that, the rectum was sanitized with Betadine solution, and then the defect of the rectum was sutured using a self-tightening “V-Lock” thread of “Covidien” company.

In all the patients of this group after performing local excision of tumors using the TEM technique with taking into account a high risk of recurrence and metastasis, the standard TEM technique was added with an express histological examination of the sentinel lymph node. The patient’s treatment was started according to the standard TEM method, then 1–2 ml of ICG dye was injected into the submucosal layer of the tumor. In 15 minutes after staining laparoscopy was performed to dissect the stained regional lymph nodes (Fig. 2).

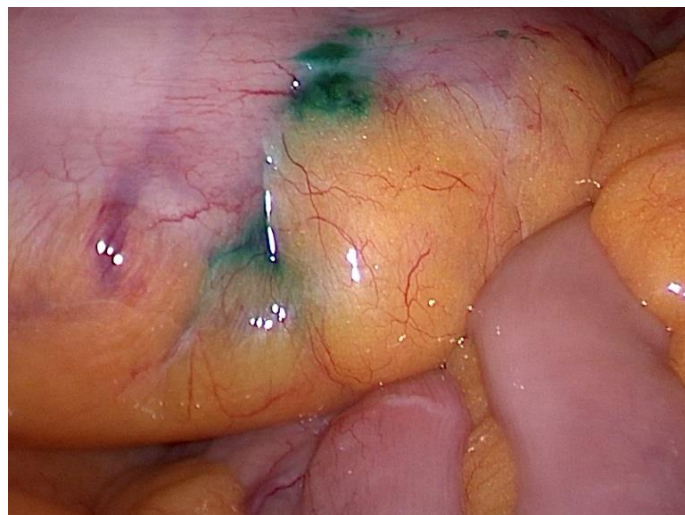

Fig. 2. Stained sentinel lymph nodes during laparoscopy

A clear imaging of the sentinel lymph vessels and regional lymph nodes was carried out in the ultraviolet illumination mode on the “Karl Storz” videolaparoscopic stand (Fig. 3).

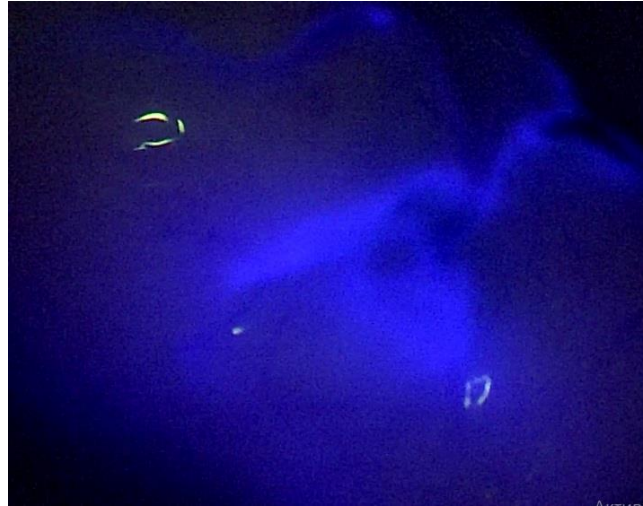


Fig. 3. The stained sentinel lymph node in the fluorescence mode on the “Karl Storz” stand

Table 1 - Distribution of patients into groups

Groups	Group I 184 (49.1%) patients			Group II 191 (50.9%) patients
	Stage I Group IA	Stage II Group IB		Stage III Group II
Rectal cancer staging				
Number of patients in subgroups	90 (48.9 %)	94 (51.1%)		not divided
Operations performed	TEM in 100% of cases	TEM – 58 (61.7%) patients	LAR+TME 36 (38.3%) patients	LAR+TME 191 (50.9%) patients
Express examination of sentinel lymph nodes	100%	100%		Not studied, group retrospective analysis
Presence of MTS lesions of sentinel lymph nodes	0%	36 (38.3%) patients		191 (100%) patients according to standard histological examinations
Venous thromboembolic complications	No	No		No
Bleeding	2 (2.2%)	6 (6.3%)		No
Purulent-septic complications	No	No	No	28 (14.6%)
Intraoperative perforation of the intestinal wall	5 (5.6%)	1 (1.7%)	No	No
Recurrence of rectal cancer in 12–60 months	Not	Not	12 (13.8%)	29 (15.2%)

After laparoscopic removal of sentinel lymph nodes, their urgent histological examination was performed. If no cancer micrometastases were detected in the lymph nodes, the tumor was resected using the TEM technique. With metastatic involvement of the sentinel

lymph nodes, laparoscopic or laparoscopic-assisted low anterior resection of the rectum supplemented with TME was performed.

Sentinel lymph nodes examination revealed no MTS lesions in group IA; 58 (61.7%) patients of the group IB had no cancer metastases. These patients had radical removal of the rectal tumor by a standard TEM technique. The low anterior resection (LAR) of the rectum with total mesorectumectomy was performed in 36 (38.3%) patients of the group IB with detected metastases in the sentinel lymph nodes (Table 1).

Histological examination of all patients revealed adenocarcinoma of various degree of differentiation.

Results. In group I, all 184 patients had no thromboembolic and urological complications, no severe intraoperative complications. Any patient died neither during the operation nor at the early postoperative period. The duration of patient's stay in the hospital averaged (3.4 ± 1.7) days. The lower edge of the tumor was at an average height of (9.5 ± 4.2) cm from the anal canal (5–16 cm), the average size of the tumor was from (2.8 ± 1.7) cm – 1.5–4 cm. When analyzing the histology results, in all cases the tumor was removed within healthy tissues, which meets the oncological method standards.

In group IB, acute bleeding occurred in 8 patients at the early postoperative period on the 2nd day, which required the surgical reintervention using the TEM technique. Sources of bleeding were identified and eliminated intraoperatively. After the reintervention these patients were discharged in an improved condition.

Intraoperative penetration into the abdominal cavity took place in 6 (6.6%) patients with the location of the tumor at a height of 13–16 cm from the anal canal. It was eliminated during laparoscopy simultaneously with sentinel lymph node biopsy without the unloading stoma. The tightness of the seams was checked by the bubble test.

At the late postoperative period it was found that rectal defects healed satisfactorily.

The mean follow-up period ranged from 12 to 60 months. Recurrence of rectal cancer was found in 12 (13.8%) patients, all the patients were in IB group.

In group II, all 191 patients had no thromboembolic and urological complications, as well as bleeding requiring reinterventions. There were no severe intraoperative complications, no patients died either during the operation or at the early postoperative period. However, 28 (14.6%) patients had purulent-septic complications in this group.

15 (53.6%) patients had suppuration of the postoperative wound, which subsequently required outpatient observation, 9 (32.1%) patients were diagnosed intra-abdominal abscesses and infiltrates, the latter were stopped by puncture and drainage under ultrasound control and

antibiotic therapy; 4 (14.2%) patients had anastomotic leaks, colostomy followed by a reconstructive stage in three months was required in 2 (7.1%) patients.

The length of patient's stay in the hospital averaged (8.4 ± 1.7) days. When studying the histology results, in all cases the tumor was removed within healthy tissues, which meets the standards of oncological technology.

During the period of 12–40 months tumor recurrence and distant metastases were found in 29 (15.2%) patients of group II.

Discussion. The results of recent multicentric trials show that the treatment of patients with rectal cancer is debatable, since local excision of the tumor is performed without lymphadenectomy. However, it is the local resections of rectal tumors that can significantly reduce the number of intraoperative and postoperative complications, decrease the length of patients' stay in the hospital, reduce the colostomy formation incidence, and reduce the frequency of the autonomic nerve plexuses damage.

The use of transanal endoscopic resections in patients with RC stage I, in our opinion, can become a standard procedure in many clinics, as it shows its effectiveness and low surgical injury. With the enough high level of preoperative examination and correct tumor staging, TEM can be performed without biopsy of sentinel lymph nodes with reliably good results. The use of transanal endoscopic resections in patients with RC stage II became possible due to the laparoscopic express diagnostics of sentinel lymph nodes with intraoperative determination of the extent of surgical intervention.

Absence of cancer micrometastases in regional lymph nodes is a reliable justification and indication to local removal of rectal tumors with the TEM technique.

Conclusions. Transanal endoscopic resections in patients with RC stage II are possible provided a mandatory intraoperative staining and express histology of sentinel lymph nodes. In such cases the extent of surgical intervention is determined on the operating table based on the results of the express histological examination. If MTS lesions of the mesorectal (sentinel) lymph nodes are detected, the operation must be continued with the obligatory mesorectumectomy.

The RC treatment algorithm of choice makes it possible in the vast majority of cases to refuse traumatic operations in favor of TEM.

Disclosures: Financial support: No financial support was received.

Conflict of interest: The authors declare no conflict of interest.

References

1. Grubnik VV, Nikitenko RP, Degtyarenko SP, & Grubnik VV. Transanal endoscopic operations in rectal tumors. *Klinicheskaia Khirurgiia*. 2019; 86(3): 15-18. doi.org/10.26779/2522-1396.2019.03.15.
2. Konishi T, Kuroyanagi H, Oya M, Ueno M, Fujimoto Y, Akiyoshi T, Yoshimatsu H, Watanabe T, Yamaguchi T, Muto T. Multimedia article. Lateral lymph node dissection with preoperative chemoradiation for locally advanced lower rectal cancer through a laparoscopic approach. *Surg Endosc*. 2011; 25: 2358-2359 DOI:10.1007/s00464-010-1531-y.
3. Quadros CA, Falcao MF, Carvalho ME, Ladeia PA, Lopes A. Metastases to retroperitoneal or lateral pelvic lymph nodes indicated unfavorable survival and high pelvic recurrence rates in a cohort of 102 patients with low rectal adenocarcinoma. *J Surg Oncol*. 2012; 106: 653-8. <https://doi.org/10.1002/jso.23144>.
4. Lezoche E, Baldarelli M, Lezoche G, Paganini AM, Gesuita R, Guerrieri M. Randomized clinical trial of endoluminal locoregional resection versus laparoscopic total mesorectal excision for T2 rectal cancer after neoadjuvant therapy. *Br J Surg*. 2012; 99: 1211-1218. doi.org/10.1002/bjs.8821.
5. Morino M, Risio M, Bach S, Beets-tan R, Bujko K, Panis Y, Quirke P, Rembacken B, Rullier E, Saito Y, Youngfadok T, Allaix ME. Early rectal cancer: the European Association for Endoscopic Surgery (EAES) clinical consensus conference. *Surg Endosc*. 2015; 29: 755-73. DOI: 10.1007/s00464-015-4067-3.
6. Bilhim T, Pereira JA, Tinto HR, Fernandes L, Duarte M, O'Neill JE, et al. Middle rectal artery: Myth or reality? Retrospective study with CT angiography and digital subtraction angiography. *Surg Radiol Anat [Internet]*. 2013; 35: 517-522. DOI: 10.1007/s00276-012-1068-y.
7. Ermakov V, Saribekyan EK, Ablitsova NV, Usov FN. Sentinel lymph nodes in malignant tumors *Malignant Tumors*. 2017; 1(22): 70-7. DOI:10.18027/2224-5057-2017-1-70-77
8. Allaix ME, Arezzo A, Arolfo S, Caldart M, Rebecchi F, Morino M. Transanal endoscopic microsurgery for rectal neoplasms. How do I do it. *J Gastrointest Surg*. 2013; 17: 586-592. DOI: 10.1007/s11605-012-2060-x
9. Wu Y1, Wu YY, Li S, Zhu BS, Zhao K, Yang XD, et al. TEM and conventional rectal surgery for T1 rectal cancer: a meta-analysis. *Hepato- gastroenterology*. 01 Mar 2011; 58 (106): 364-368. PMID: 21661397

10. Denzer U, Beilenhoff U, Eickhoff A, et al. S2k-Leitlinie Qualitätsanforderungen in der gastrointestinalen Endoskopie, AWMF Register Nr. 021–022. *ZGastroenterol.* 2016; 53: E1-E227. doi.org/10.1055/s-0041-109598
11. Mölle B, Ommer A, Lange J, Girona J (eds.). *Chirurgische Proctologie.* Springer, Heidelberg, Berlin, New York, 2018. 478 p. <https://doi.org/10.1007/978-3-662-54682-6>.
12. Schmidt A, Bauerfeind P, Gubler C, et al. Endoscopic full-thickness resection in the colorectum with a novel over-the-scope device: first experience. *Endoscopy.* 2015; 47: 719-725. <https://doi.org/10.1055/s-0034-1391781>.
13. Watanabe T, Muro K, Ajioka Y, et al. Japanese Society for Cancer of the Colon and Rectum (JSCCR) guidelines 2016 for the treatment of colorectal cancer. *Int J Clin Oncol.* 2018; 23: 1-34. doi.org/10.1007/s10147-017-1101-6.
14. Stevenson ARL, Solomon MJ, Brown CSB, Lumley JW, Hewett P, Clouston AD, et al. Disease-free survival and local recurrence after laparoscopic-assisted resection or open resection for rectal cancer: the Australasian laparoscopic cancer of the rectum randomized clinical trial. *Ann Surg.* 2019; 269 (4): 596-602.
15. Penna M, Hompes R, Arnold S, Wynn G, Austin R, Warusavitarne J, et al. Transanal total mesorectal excision: international registry results of the first 720 cases. *Ann Surg.* 2017; 266(1): 111–7.
16. Smith JJ, Strombom P, Chow OS, Roxburgh CS, Lynn P, Eaton A, et al. Assessment of a watch-and-wait strategy for rectal cancer in patients with a complete response after neoadjuvant therapy. *JAMA Oncol.* 2019; 5: e 185896.