

Broshkov M. M., Kusturov V. B. Toxoplasmosis as a factor in chronic diseases in dogs. *Journal of Education, Health and Sport*. 2022;12(4):271-234. eISSN 2391-8306. DOI <http://dx.doi.org/10.12775/JEHS.2022.12.04.021>
<https://apcz.umk.pl/JEHS/article/view/JEHS.2022.12.04.021>
<https://zenodo.org/record/7068537>

The journal has had 40 points in Ministry of Education and Science of Poland parametric evaluation. Annex to the announcement of the Minister of Education and Science of December 1, 2021. No. 32343. Has a Journal's Unique Identifier: 201159. Scientific disciplines assigned: Physical Culture Sciences (Field of Medical sciences and health sciences); Health Sciences (Field of Medical Sciences and Health Sciences).

Punkty Ministerialne z 2019 - aktualny rok 40 punktów. Załącznik do komunikatu Ministra Edukacji i Nauki z dnia 1 grudnia 2021 r. L.p. 32343. Posiada Unikatowy Identyfikator Czasopisma: 201159. Przypisane dyscypliny naukowe: Nauki o kulturze fizycznej (Dziedzina nauk medycznych i nauk o zdrowiu); Nauki o zdrowiu (Dziedzina nauk medycznych i nauk o zdrowiu).

© The Authors 2022;

This article is published with open access at Licensee Open Journal Systems of Nicolaus Copernicus University in Torun, Poland

Open Access. This article is distributed under the terms of the Creative Commons Attribution Noncommercial License which permits any noncommercial use, distribution, and reproduction in any medium, provided the original author (s) and source are credited. This is an open access article licensed under the terms of the Creative Commons Attribution Non commercial license Share alike. (<http://creativecommons.org/licenses/by-nc-sa/4.0/>) which permits unrestricted, non commercial use, distribution and reproduction in any medium, provided the work is properly cited.

The authors declare that there is no conflict of interests regarding the publication of this paper.

Received: 23.03.2022. Revised: 04.04.2022. Accepted: 29.04.2022.

UDK 636.7.09:616.993.195

TOXOPLASMOSIS AS A FACTOR IN CHRONIC DISEASES IN DOGS

M. M. Broshkov, V. B. Kusturov

Odesa State Agrarian University, Odesa, Ukraine

Abstract

Toxoplasmosis is one of the most common animal and human diseases worldwide and is reported in European, Asian, African, North, and Latin American countries. This is due to the limited research methods that confirm the pathogen presence in animals and humans, the characteristic clinical signs, in some regions it is associated with sanitation problems, mainly due to improper cooking as most positive animals did not show a significant association with rodents or raw water consumption, the impossibility of complete body rehabilitation using currently known tools and treatment regimens, as well as the lack of understanding among individual physicians the peculiarities of pathogenesis in this pathology, features of diagnostic and therapeutic approaches. Toxoplasmosis course is clinically manifested by a wide range of clinical signs and immunosuppression of the cellular immune system that complicates the selection of pharmacological agents for the treatment in dogs. Prolonged functioning of the immune system in conditions of chronic recurrent infection contributes to cytokine imbalances and their permanent expression, supporting the inflammatory process. The reason for the development of chronic diseases is a violation of homeostasis due to either excessive intake of xenobiotics, including toxic, or violation of various levels of protection –

detoxification, immunity, and excretion of pathological metabolites from the body. Therefore, this review is aimed at providing an analysis on the clinical aspects of toxoplasmosis, the development of immunological reactions, and the seasonality of antigen activation, which coincides with the exacerbation of clinical signs. This review may be of interest among practicing physicians and researchers.

Key words: *T. gondii*; immunity; plasmapheresis; antibody titer; renal failure; immunoregulatory cells

Introduction. *Toxoplasma gondii* is an obligate intracellular protozoan parasite with a sexual life cycle that occurs only in the feline intestine. The disease has complex epidemiology; the parasite is able to infect almost all warm-blooded animals and has a life cycle involving two hosts [1, 2].

The transmission of toxoplasmosis to humans is a critical issue. In some parts of the world, about 60% of the population has antibodies to toxoplasmosis and probably are permanently infected [3, 4].

According to Rodrigo Costa da Silva data, toxoplasmosis in certain regions is associated with sanitation awareness problems, mainly due to improper cooking, as most positive animals did not show a significant association with the presence of rodents or raw water consumption, but instead reveal the relationship with homemade food consumption [5].

Our research revealed that cattle and sheep meat is contaminated with *T. gondii*. Muscles from the diaphragm, back, and thigh, as well as the lung, kidney, and liver tissues in animals with a confirmed diagnosis of toxoplasmosis, were sampled for laboratory tests. According to research results, the highest antibody titer was found in the diaphragm muscles (Table 1).

Table 1

Antibody titer (Ig M, G) in different tissues and organs from animals with toxoplasmosis

Animal species	Muscles			Tissues		
	diaphragm	back	thigh	lung	kidney	liver
Cattle	51.0	45.3	51.8	10.8	19.7	17.6
Sheep	44.7	39.1	43.6	17.4	15.0	10.3

Notes: Result interpretations (%): ≤40 – negative result; 40–50 – doubtful result; ≥50 – positive result.

T. gondii exists in three forms: (I) tachyzoites, which are characterized by growing forms and perform a secretory function, promoting the penetration of the parasite into host

cells; (II) bradyzoites, forms of obligate intracellular parasite that slowly replicate and occur in various tissues (tissue cysts); and (III) oocysts – resistant forms found only in feline feces [6–8]. All three forms are contagious. For the last three decades, *T. gondii* has generally been considered the only true species in the genus *Toxoplasma* [9, 10].

In dogs and other mammals (except cats), *T. gondii* does not pass the sexual stage of its development [11]. Thereby, they are not a source of toxoplasmosis infection, as oocysts are not formed in the intestine and chronic infection takes the form of cysts, which are mainly located in the muscles and brain [12]. In the body of vertebrates, *T. gondii* faces many challenges in crossing biological barriers, avoiding immune surveillance, and establishing its niche as an intracellular parasite. This journey begins in the intestine, where parasites penetrate enterocytes and replicate, but they can also pass through the epithelial barrier and reach lamina propria consisting of loose connective tissue with glands and lymphoid formations, where they are exposed to macrophages, dendritic cells (DCs) and intraepithelial lymphocytes [13]. The immune response also induces the differentiation of the parasite into a chronic form (bradyzoites). The transition from acute primary infection to chronic toxoplasmosis is accompanied by a transition from fast replicating and metabolically highly active tachyzoites to slow replicating and largely dormant bradyzoites within tissue cysts. Such differentiation of development is critical for *T. gondii* in order to complete its life cycle and for pathogenesis [14]. However, the immune response is not able to eradicate tissue cysts, and the reactivation of cysts can cause severe disease in the body with primary or acquired deficiencies in T cell-mediated immunity [15].

The mechanisms due to which *T. gondii* penetrates host cells and forms an intracellular niche were widely considered but some aspects of this process are directly related to immunity and pathogenesis [16].

In the literature, there are different views on which factors prevent reactivation of infection and which contribute to persistence [17–19].

Little is known about transplacental toxoplasmosis in dogs, although its occurrence is thought to be less common than in other species. The only evidence is based on two studies [20, 21] that reported a high prevalence of *T. gondii* DNA detection in fetal tissues of dogs, but the significance of these findings is unknown.

In dogs, *T. gondii* was isolated in puppies from a seropositive bitch in Australia, however, clinical signs were not found in any of the animals [22]. *T. gondii* DNA was detected in fresh semen from five out of eleven seropositive naturally infected healthy dogs in Brazil, and *in vitro* isolation of the parasite was achieved [23]. However, the venereal

transmission was demonstrated earlier, when fresh semen, collected from experimentally infected dogs that tested positive for *T. gondii*, was used for artificial insemination in four bitches. Seroconversion was observed in all females seven days after artificial insemination, and reabsorption occurred in two dogs. The remaining bitches sustained full-term gestations, and *T. gondii* cysts were detected in brains of four offspring [24].

Aim of the work: to highlight less-known clinical manifestations, the description of sources of infection for both animals and humans, the development of immunological reactions during infection, and new approaches to the treatment of chronic toxoplasmosis, which may be of particular interest to physicians and researchers.

Materials and methods. Animal experiments were conducted in accordance with international and national recommendations, the OIE Terrestrial Animal Health Code CNAS-CL06:2018, respectively, regarding the care and use of laboratory animals.

Enzyme immunoassay (ELISA)

The *Toxoplasma gondii* IgG titer was determined by the method of solid-phase enzyme immunoassay on the Multiskan FC ELISA analyzer using the “Hema” test system.

Plasmapheresis procedure

Investigations were conducted on 3 *T. gondii* seropositive dogs aged 2 to 5 years, the average body weight of which was 16 kg. Clinical signs of hepatopathy, depression, persistent signs of skin lesions in the form of rashes, itching were found in the anamnesis of all animals during the examination. To carry out the plasmapheresis procedure, the ACE-1 “Hemofer” device was used, which is a chamber pump of the ventricular type with inlet and outlet valves that suck blood from the vein during the “diastole” period, and push it further during the “systole” period.

When performing plasmapheresis, a single-use line and plasma filter (PMF-800) were used. An isotonic NaCl solution was used as a plasma substitute, and a heparin solution (5000 IU/ml) was used as an anticoagulant, an average of 3 ml per head. Anticoagulant was added gradually to the NaCl solution at the rate of 1 ml per 200 ml of isotonic solution. On average, 600 ml of NaCl solution was used for one plasmapheresis procedure. Each animal underwent the plasmapheresis procedure three times, with an interval of 48 hours.

Blood serum biochemical investigations

To study the content of total protein, protein fractions, alanine aminotransferase (ALT), aspartate aminotransferase (AST), whole blood was collected in tubes with a blood coagulation activator (SiO₂), the serum was carefully separated from the formed elements of the blood no later than 1 hr after taking of blood

Determination of the concentration of total protein, protein fractions, alanine aminotransferase (AlAT), aspartate aminotransferase (AsAT) in blood serum was carried out using test systems of the DAC company (Moldova). The research was carried out on a biochemical analyzer "Evolution 3000" (Italy).

Determination of the absolute number of natural killer cells (NK cells)

The number of killer cells was calculated using the universal method of morphological research of formed blood elements. The relative number of lymphocytes in 1 µl of blood was determined by counting the percentage of large plasma lymphocytes (with azurophilic granularity) in the total number of lymphocytes. The calculation was carried out using immersion oil and an immersion lens (eyepiece magnification 15, lens 90).

Determination of phagocytic activity of neutrophils

The reaction to determine the neutrophils phagocytic activity is carried out in 96-cell plates for immunological reactions with cells with a capacity of 0.2 ml and a round bottom. The phagocytosis test is carried out in the same way as E-rosette formation, but instead of a suspension of ram erythrocytes, 0.06 ml of a 0.1% suspension of baker's yeast cells, previously killed by heating, is added. In the preparations, the number of phagocytic neutrophils per 50 neutrophils is counted. A cell was considered phagocytizing - a neutrophil that swallowed 1 or more yeast cells.

Determination of the immunoregulatory index

The immunoregulatory index (the ratio of T-helpers to T-suppressors) shows that a change in this indicator usually occurs due to imbalances between immunoregulatory subpopulations of lymphocytes and is one of the risk factors for the development of immunopathological reactions.

Determination of the relative number of T- and B-lymphocytes by the method of rosette formation with erythrocytes of sheep and mice (B-lymphocytes) as markers

In the blood of experimental animals, the absolute number of leukocytes was determined (according to the method of prof. T.V. Degtyarenko), the absolute and relative number of lymphocytes and their immunoregulatory subpopulations (in the rosette formation reaction with ram erythrocytes), and the number of phagocytic neutrophils per 50 neutrophils was also determined.

One of the characteristic features of T-lymphocytes is the presence on their surface of specific receptors for ram erythrocytes, which allows for their differential diagnosis and to calculate their relative content. Thanks to the presence of specific receptors on their membranes, T-lymphocytes under certain conditions form so-called "rosettes" with ram

erythrocytes, in the center of which there is a lymphocyte, and on the periphery erythrocytes. The number of erythrocytes adsorbed by one lymphocyte determines the degree of T-cell activity, as this phenomenon is caused by the density of receptors on the surface of lymphocytes and characterizes their functional properties.

Statistics. The resulting digital material was processed using the Statystika program for Windows XP. After comparing the studied indicators and their differences between groups, the Student's t-test was used, and the result was considered probable after $p < 0.05$.

The following marks are used in the tables: * - $p < 0.05$, ** $p < 0.01$, *** $p < 0.001$.

Results

1. Clinical manifestation and pathology of toxoplasmosis in dogs.

Pathological changes reveal in chronically infected hosts, where degenerative changes in the organs are observed. *T. gondii* has tropism to the muscular and nervous tissues, therefore, parenchymal organs, muscles, and brain, as well as the myocardium and endocrine glands are most frequently affected. The portal of entry for infection during foodborne transmission, as a rule, is the ileum. This is evidenced by a pronounced reaction of the mesenteric lymph nodes. In the latter, there is hyperplasia with the presence of giant multinucleated cells. Typical lesions in the muscles, myocardium, less often the muscle tissue of other organs, are areas of intermediate productive myositis, also focal muscle necrosis is rarely detected. At that time, there are small areas of necrosis, extensive infiltrates consisting of lymphocytes, histiocytes, as well as plasma cells, neutrophils, and eosinophilic leukocytes in places of parasite location in all affected organs. Necrotic foci develop in nerve cells.

Professor A. M. Bugaiev claims that *T. gondii* causes severe morphological changes in different organs including the brain: "...in the brain, Toxoplasma hydrolyzes the white matter, namely, transform the dendrites, axons of neurons and glial cell processes into an unstructured protein mass. Tissue cysts of Toxoplasma are parasite colonies consisting of 5–10 thousand microscopic organisms. There may be one such colony in the brain, may be two, three, but there may be more...". During congenital toxoplasmosis, there is an underdevelopment of cerebral hemispheres. The lesions of the ependyma, the appearance of adhesions in the brain ventricles, and obliteration of the subarachnoid spaces lead to the development of hydrocephalus. During the late fetopathy, there are foci of necrosis and calcification in the cerebral cortex, subcortical area, and brainstem. Acquired toxoplasmosis is characterized by a productive inflammation of the brain and its membranes, namely meningoencephalitis, meningoradiculitis, and paralysis of the extremities. Since the retina is a nervous tissue, frequent cases of necrobiosis occur with the formation of granulomas in the

vascular tract (productive necrotic endophthalmitis, chorioretinitis, and uveitis), and blindness may develop. The presence of *T. gondii* in the central nervous system and eyes during the elimination of the pathogen is due to the slow diffusion of antibodies through the blood-brain and blood-ophthalmic barriers, resulting in favorable conditions for their survival and cyst formation in the brain tissues and eyes [10]. Parasite differentially expressed genes, which are involved in metabolic pathways, showed significant changes at the beginning of the infection. These results suggest that gene expression in porcine kidney (PK-15) cells that interact with *T. gondii* are closely related.

Studies have confirmed that if signs of kidney damage are detected during the general clinical examination, it is necessary to conduct additional serological tests for *T. gondii* and stool test. The graphs show the dynamics of serum creatinine and urea levels during the course of therapy in animals seropositive for toxoplasmosis (Fig. 1).

Other authors give similar conclusions regarding the need for serological tests for toxoplasmosis during the manifestation of clinical signs of liver failure.

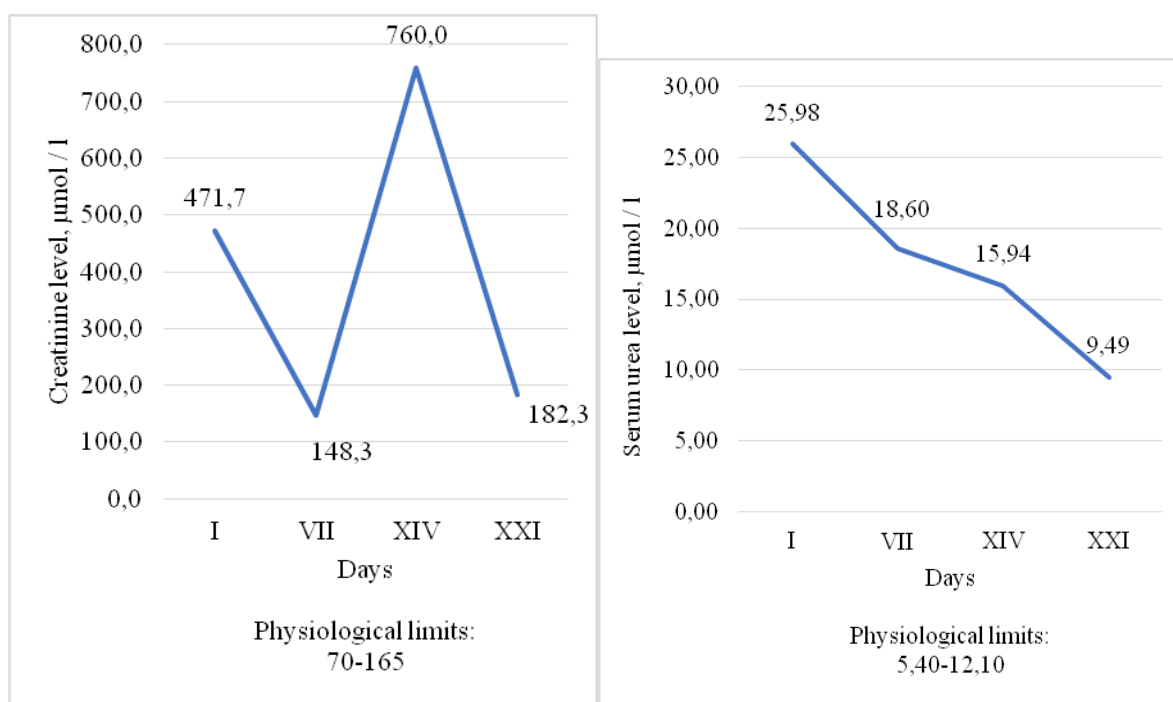


Fig. 1. Serum creatinine and urea levels in seropositive animals during treatment

The liver is most severely infected. As a result of *T. gondii* replication, several pathological changes were observed including hepatomegaly, granulomas, hepatitis with small foci of necrosis, and granulomas. Histological examination of the liver showed multifocal hepatocellular necrosis, severe hemorrhage, as well as the accumulation of fibrin,

chromatin, and macrophages. Some hepatocytes contained in the cytoplasm several elongated basophilic bodies with a diameter of 3 to 4 μm , which resembled protozoan parasites. Severe forms of injury may occur during both chronic and acute forms with a long-term recurrent course. Laparoscopy often shows signs of chronic hepatitis. Toxoplasmic hepatitis has no specific clinical symptoms and is similar to viral hepatitis by its course. In addition, the biliary function is impaired that leads to gallstone formation.

The most commonly described is interstitial hepatitis with small areas of necrosis and severe portal infiltration, which changes to fibrosis later.

Neurological disorders with signs of seizures, cranial nerve deficits, tremors, ataxia, paresis, or paralysis within encephalomyelitis may occur. Paraparesis and tetraparesis, which progressed to lower motor neuron paralysis and nodules in the spinal cord, were described in dogs with dual infection with *Sarcocystis neurona* and *T. gondii*. Other reported cases of toxoplasmosis in dogs include noise sensitivity in an 8-year-old female collie, myositis that initially showed an abnormal gait, muscle wasting, and stiffness, and ocular disease described as necrotizing conjunctivitis, anterior uveitis, endophthalmitis, and chorioretinitis. Cutaneous toxoplasmosis should be considered in the differential diagnosis of skin lesions in dogs, especially those with immunosuppression.

According to our observations, dogs with chronic skin dysfunctions require compulsory testing for toxoplasmosis. The photo shows uncharacteristic synchronous alopecia in the periphery of the auricle in a dog of the French bulldog breed, which is seropositive for toxoplasmosis (Fig. 2).

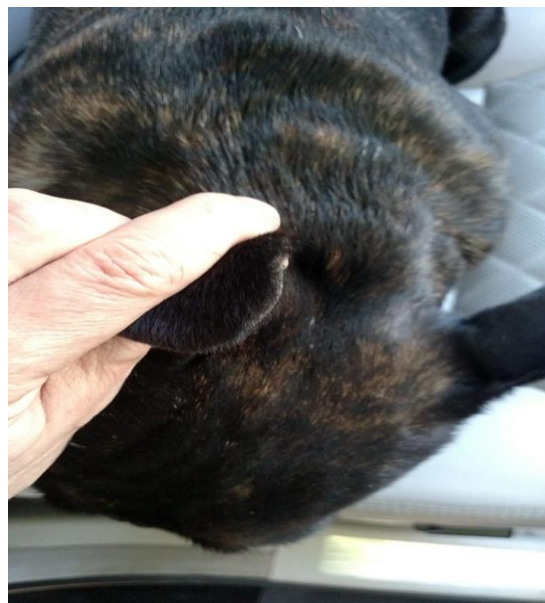

Fig. 2. Uncharacteristic synchronous alopecia in a seropositive French bulldog (male 4 years)

2. Features of the immune response in toxoplasmosis

The influence on the immune response formation in the acute stage of toxoplasmosis and its results are insufficiently described in the literature. In research publications that focus on the problem of toxoplasmosis, one of the numerous issues is poorly covered: what humoral disorders occur in dogs during the acute and chronic stages of acquired toxoplasmosis?

Inflammatory cells attracted to the primary focus of infection are targets for parasites that enter into the cell in order to circulate through the body inside the host cell, by a mechanism similar to a Trojan horse, delivering the parasite to tropism tissues such as the central nervous system and eyes.

For the successful achievement of this semi-equilibrium state between the host and parasite, the initial events occurring at the entry site of the parasite are critical.

The antibody synthesis during the primary infection with *T. gondii* in animals with a normally functioning immune system is carried out by the basic principles of immunogenesis. The crucial value has the dynamics of antibodies in animals during a certain time period; the relationship between the manifestations of the infectious process and the state of the immune system during *T. gondii* infection and their persistence; an increasing in the number of factors that negatively affect the immunogenesis in animals. All these factors determine a significant increase in the number of individuals with the possible development of pronounced forms of the disease (septic forms in individuals with severe immunodeficiency).

According to the authors, cysts are unstable; some of them are being continuously ruptured, causing a continuous entry of both the pathogen itself and its antigens and waste products into the intercellular space. This determines the constant interaction of the pathogen with the animal immune system.

By the modern concepts, in the early stages of infection (in experiments, particularly *in vitro*), *T. gondii* initiate antigen-nonspecific T cell-independent immunity through the activation of macrophages and natural killers. This activation is mediated by the cytokine systems, which is manifested in enhancing interferon-gamma (IFN- γ) production by natural killers with subsequent activation of the microbicidal function in macrophages. This restricts tachyzoites replication until adequate T cell-mediated immunity is formed.

IFN- γ is a major mediator of resistance to *T. gondii* and is crucial for the activation of various antimicrobial measures in hematopoietic and non-hematopoietic cells that limit parasite replication. This cytokine also stimulates phagocytes to produce reactive oxygen species and nitrogen intermediates, which can cause damage to parasites and inhibit macrophage growth. In the earliest stages of *T. gondii* infection, a cascade of reactions occurs among macrophages and

natural killers leading, on the one hand, to direct restriction of pathogen distribution and, on the other, to cytokine synthesis that determines the type of immune response and T lymphocyte activation. *T. gondii* is a potent inducer of antigen-specific T lymphocyte lines: with helper activity (CD4 cells) and with killer and suppressor activity (CD8 cytotoxic cells), which proves the participation of parasitic peptides in cell-mediated methods of antigen presentation.

Studies have shown the importance of interleukin-12 (IL-12) induction in the presence of monocytes in the early stages of infection. IL-12 is required for resistance to acute and chronic toxoplasmosis due to its essential role in stimulating IFN- γ production. Secretion of IL-12, CD8 α^+ DCs suggests the role of these cells in response to *T. gondii* antigens, plasma cells, dendritic cells. Neutrophils also occupy a leading position in the cascade of early events leading to IL-12-dependent immunity to *T. gondii*.

Interestingly, the stimulation of the early T cell-mediated immune response in toxoplasmosis is carried out only after the antigen processing to CD8+, except for IFN- γ synthesis, which shows cytotoxicity against infected cells. The main target for cytotoxic CD8+ T cells is a major surface antigen of *T. gondii*, although its other antigens show similar properties.

In response to infection, immunocompetent animals produce specific M class antibodies. In 3–4 weeks or more (up to 3–5 months) after primary infection, the synthesis of specific IgG begins, the titer of which grows exponentially and progressively. Most often, by the end of the 3rd–5th month after primary infection, anti-Toxoplasma IgM antibodies disappear, and the IgG titer reaches its maximum. In the future, specific IgG can be preserved for decades preventing re-infection. Fluctuations in their titers towards an increase several times are most often observed during exacerbation or recurrence of the disease. By this time, *T. gondii* is completely transformed into bradyzoites, forming cysts and thus hiding from the exposure to factors of resistance. The appearance of the pathogen in the extracellular space leads to its death as a result of interaction with specific antibodies and activated macrophages [18, 19].

In dogs, *T. gondii* (as an intracellular parasite) remains active and leads to clinical exacerbations, mainly in the warm season. It was found that 21.7% of the studied blood serum samples from domestic omnivorous animals had antibodies to *T. gondii*. There is a relationship between the seasons of the year and the number of animals that are seropositive for toxoplasmosis. The highest seropositivity rates, both among cats and dogs, were recorded in summer – 26.3% and 31.7%, respectively.

There is also a seasonality regarding infection of animals with toxoplasmosis and most often, this occurs in the summer period of the year, which is supposed to be related to the temperature factor (Fig. 3).

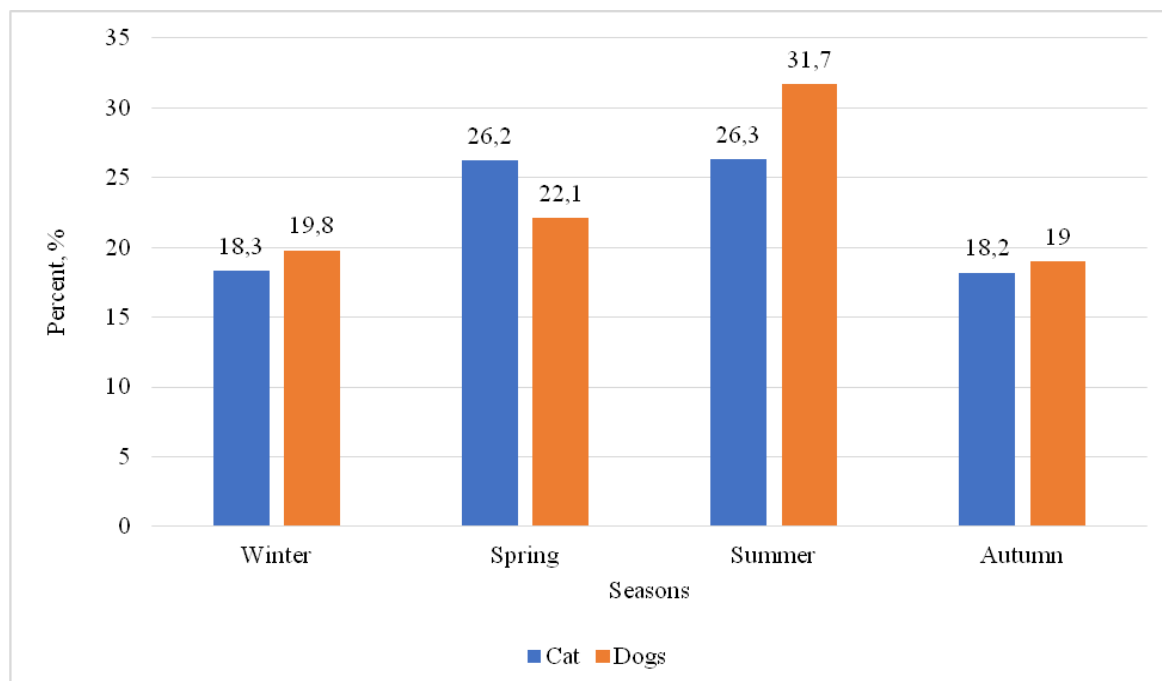


Fig. 3. Seasonality of *Toxoplasma gondii* infection in dogs and cats.

Antigens formed as a result of the *T. gondii* death, interacting with cells of the immune system, cause long-term stimulation of antibody formation and persistence of memory T lymphocytes [17].

There are various considerations in the literature on which factors prevent infection reactivation and which contribute to persistence. Many researchers believe that a key point in preventing the reactivation of chronic toxoplasmosis is a high level of IFN- γ synthesis that prevents cyst rupture [17–19].

Some studies have shown that infection of macrophages with *T. gondii* leads to a decrease in the expression of major histocompatibility complex (MHC) class II and IFN- γ -dependent presentation of MHC class I molecules, which may be one of the factors determining the persistence of this pathogen. Other authors have shown that during the reactivation of latent infection, an important role plays CD8⁺, which lyses the infected cell but does not destroy *T. gondii* itself.

Moreover, infection of host cells is associated with decreased expression of MHC molecules. Despite these mechanisms, infection with *T. gondii* strains type II leads to DCs

activation and release of CD8+ T-cell response, whereas infection with virulent strains type I causes a weak reaction.

The immunosuppressive effect causes a redistribution of the formed types of the immune response towards Th1-type, which is manifested by the increase in interferon-alpha (IFN- α) level, the role of which consists in the protection of intact cells and cell apoptosis during stress. In the background, an immune imbalance develops, the concentration of IFN- γ decreases, i.e. there is a redistribution of synthesis. The decrease in IFN- γ concentration leads to a violation of the toxoplasmodicidal activity in macrophages, the transformation of specific Th0 cells into Th1 cells that cause increased cytolysis of cells infected with *T. gondii*. In this case, *T. gondii* enters the extracellular space and is partially lysed by specific antibodies in the presence of complement.

Some parasites undergoes incomplete phagocytosis. Inside the cell, *T. gondii* forms its membrane, suppresses the antigen-presenting function, and thus creates the conditions for its preservation, since even after cell lysis it remains alive. In our studies, we performed a comparative analysis of cellular immunity in dogs with detected antibodies to toxoplasmosis (experimental group) and without antibodies (control group) (Table 2).

Table 2

The absolute number of immunoregulatory cells in seropositive dogs

Immunophysiological parameters	Animal groups	
	Experimental	Control
White blood cells, g/L	7.1 \pm 1.7	10.5 \pm 1.11*
Lymphocytes, g/L	1.56 \pm 0.27	3.08 \pm 0.6*
T lymphocytes, g/L	0.993 \pm 0.149	2.22 \pm 0.176
T-helpers, g/L	0.893 \pm 0.122	1.48 \pm 0.16*
T-suppressors, g/L	0.251 \pm 0.011	0.73 \pm 0.034*
B lymphocytes, g/L	0.245 \pm 0.011	0.332 \pm 0.044
Immunoregulatory index (Th/Ts)	3.42 \pm 0.162	2.65 \pm 0.086
NK cells, g/L	0.083 \pm 0.001	0.172 \pm 0.014*
Phagocytic activity of neutrophils, g/L	2.258 \pm 0.232	3.98 \pm 0.74*

Note: * P<0.01 the difference is significant between control and experimental groups

The data obtained shows that in dogs with *T. gondii* antibodies, the absolute number of immunocompetent cells and phagocytic activity of neutrophils is significantly lower. This confirms the data of other researches on the suppressive state of the immune system during

toxoplasmosis. Perhaps the antibodies themselves have a suppressive effect on cellular immunity [86]. Prolonged functioning of the immune system in conditions of chronic recurrent infection contributes to cytokine imbalances and their permanent expression, supporting the inflammatory process. Each exacerbation of a chronic inflammatory process activates the immune system and restores the balance between inflammatory processes and the response due to immunocompetent cells on a different, lower level of protection.

It is also important to conduct the sanitation of the internal environment in the body, namely the removal of pathological metabolites and the restoration of normal metabolic processes, including lipid peroxidation or proteolysis, i.e., if you do not eliminate the “toxic pressure” on the immune system, it is difficult to rely on recovery using only drug stimulation.

Therefore, it is obvious that pharmacological agents with immunotropic action are required during therapy taking into account the long-term persistence of *T. gondii* antigen and consequently the immune response. At the same time, it is necessary to consider the multiple clinical course and features of the immune response.

3. Treatment of toxoplasmosis in dogs

The issue of toxoplasmosis treatment is one of the cornerstones of this problem. There is no evidence that any drug can completely cleanse the body from *T. gondii*, so the recurrent clinical disease can occur in infected dogs or cats [25]. It is difficult to cause clinical toxoplasmosis in dogs or cats without concomitant disease, suppression of immunity, so there are no controlled studies on the treatment effects [26]. Some dogs and cats with central nervous system diseases need supportive care, such as anticonvulsant medications.

Usually, after the disappearance of symptoms, toxoplasmosis goes into the stage of chronic latent disease. In this case, *T. gondii* is stored in the form of intracellular cysts in host cells and inside the areas of destruction in the internal organs [27].

In our observations of three seropositive dogs, we found that the titer of immunoglobulin G had dynamics (Fig. 4). The increase in titer coincided with the manifestation of clinical signs.

Anti-Toxoplasma drugs are ineffective against cysts; they can only affect pathogenic trophozoites.

The modern arsenal of drugs for the treatment and prevention of toxoplasmosis in Ukraine is identical to foreign and did not change in recent decades. For this purpose, three groups of drugs are used.

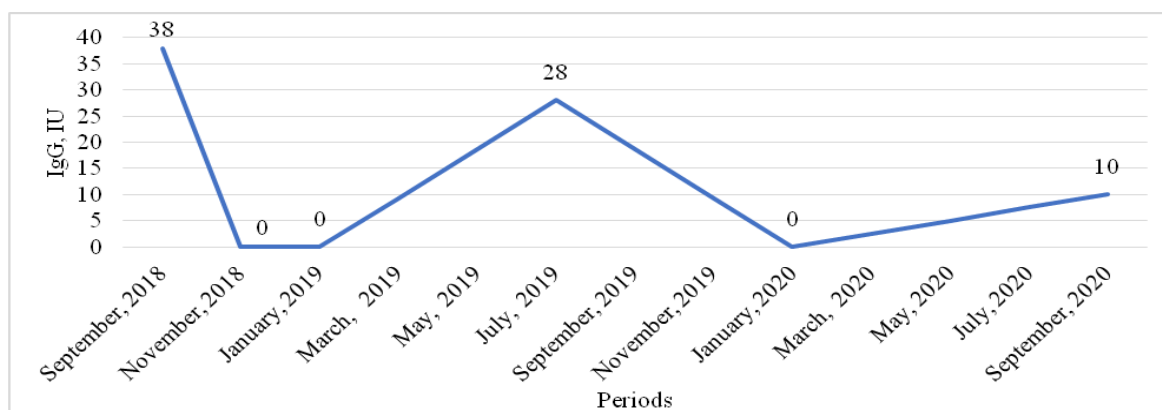


Fig. 4. Dynamics of immunoglobulin G levels in seropositive dogs

The first group includes the antibiotic spiramycin (rovamycin) and other macrolides (erythromycin, metacycline), lincomycin, which have no harmful effect on the fetus.

The second group of drugs – pyrimethamine (daraprim, tindurine, chloridin). The third group – short-acting sulfonamides (sulfadiazine, etc.) [28].

Quite frequently, combinations of pyrimethamine and sulfadiazine are used during the treatment for toxoplasmosis, which, acting together, inhibit *T. gondii* replication. The combination of these drugs is 6 times more active in treating *T. gondii* infection than individual drugs and therefore is widely used, although a large number of side effects (embryotoxic and teratogenic effects) characterizes this combination. Therefore, in the period of embryogenesis and organogenesis, the combination of pyrimethamine with sulfadiazine is not recommended, limited to the prescription of spiramycin. Sulfadiazine is administered orally at a dose of 100 mg/kg of body weight (daily dose is divided into 4 doses); at the same time pyrimethamine is prescribed at a dose of 1 mg/kg. The course of treatment constitutes 1–2 weeks [29].

The treatment of toxoplasmosis should be started immediately after the diagnosis is confirmed and continue for several days after the symptoms disappear. If clinical improvement is not noticeable within 2–3 days, the diagnosis of toxoplasmosis should be questioned. Pyrimethamine can be toxic to some cats, even if given in small amounts [30].

Tetracycline drugs have good therapeutic activity [31]. As an etiotropic therapy for acute toxoplasmosis is prescribed: fansidar (pyrimethamine complex with sulfadoxine) 1 tablet 2 times per day for 5 days, followed by a break of 5–7 days, during which calcium folinate is administered orally in a dose of 10 mg/day, then a course of fansidar is held a second time; doxycycline 100 mg capsule 2 times per day for 10 days; delagil 250 mg tablet 3 times per day + trichopol 200 mg tablet 3 times per day for 7–10 days [32].

Desensitizing and symptomatic drugs are prescribed throughout the course of etiotropic therapy. Fansidar is the most active but has a number of unpleasant side effects [33]. Doxycycline is readily available. Delagil is indicated for severe myalgias and arthralgias and is contraindicated during chorioretinitis [34].

It was recently reported that the antibiotic clindamycin is effective in treating toxoplasmosis with a small number of side effects. The best results give the use of clindamycin at a dose of 50 mg/kg of body weight (daily dose is divided into 3 doses), the course of treatment should be at least 2 weeks after remission. The drug is effective in the acute phase of the disease and reduces the number of isolated oocysts. Possible side effects of clindamycin: anorexia, vomiting, diarrhea (dosage must be adjusted) [35]. Spiramycin is a natural 16-membered macrolide, highly active against *T. gondii*, and one of the few antimicrobial drugs that can be used for toxoplasmosis prevention [36].

Often recommended drugs for the treatment or prevention of toxoplasmosis are limited to combinations of pyrimethamine and sulfadiazine. Unfortunately, these drugs have serious side effects, such as neutropenia, leukopenia, severe platelet depletion, thrombocytopenia, and hypersensitivity reactions. In addition, these drugs are also associated with some uncommon reactions, including agranulocytosis, Stevens-Johnson syndrome, toxic epidermal necrolysis, and liver necrosis, which can be fatal in patients with toxoplasmosis.

Available drugs usually inhibit *T. gondii* replication and are not completely effective in killing the parasite [37]. The use of folic acid reduces the risk of toxic reactions to chemotherapeutic drugs in the hematopoietic organs. Symptomatic therapy is also useful during the treatment of toxoplasmosis [38].

During the treatment of chronic toxoplasmosis, there is no need for specific antiprotozoal treatment. Traditional therapy of concomitant diseases is carried out. Treatment in the period of exacerbation of chronic toxoplasmosis should be comprehensive. Prolonged antiprotozoal therapy is pathogenetically unreasonable (the pathogen is unstable outside the cell, parasitemia is absent, chemotherapeutic drugs and antibiotics do not penetrate into the cysts) [39].

A typical mistake in evaluating the treatment efficacy is to focus on serological data after receiving treatment. Repeated courses of antibiotics and chemotherapy with long-term use cause immune imbalances with varying degrees of manifestation. The main criterion for treatment efficacy is the elimination of clinical manifestations of the infection. During chronic toxoplasmosis, the positive dynamics appears not earlier than one month after a comprehensive course of treatment. If the therapy is carried out properly, then the relief of the disease

manifestations occurs within 6 months [40]. Concerning laboratory indicators of the treatment efficacy, it is important to study the immune status in the body. The combination of an increase in blood serum IFN- γ levels with an increase in indexes of the completion of phagocytosis has prognostic value [40].

Recent experimental studies in clinical cases have clearly shown that drug resistance in *T. gondii* is ongoing. The emergence of *T. gondii* strains resistant to current drugs represents a concern not only for treatment failure but also for increased clinical severity in immunocompromised patients. Further development of a greater understanding of exact mechanisms of drug resistance in *T. gondii* is needed to improve the therapeutic outcomes in patients [38].

The reason for the development of chronic diseases is a violation of homeostasis due to either excessive intake of xenobiotics, including toxic, or violation of various levels of protection – detoxification, immunity, and excretion of pathological metabolites from the body [41].

Not all substances to be excreted from the body can be captured and fixed on sorbents. Electrochemically inert molecules are not capable of adhesion and remain in the circulation, which makes the hemoadsorption procedure incomplete. In these cases, the effect of such substances elimination can be obtained by plasmapheresis, when a certain part of blood plasma is completely removed together with all the pathological metabolites contained in it. Membrane plasmapheresis is also applied in the small animal practice in recent decades [42].

In contrast to hemoadsorption, plasmapheresis has a more universal nature because all pathological metabolites are removed despite the presence and magnitude of the electrostatic charge in their molecules.

Double filtration plasmapheresis (DFPP) was performed in dogs with *Leishmania infantum*, resulting in the rapid elimination of hyperproteinemia signs [43]. Plasmapheresis (therapeutic plasma exchange or double filtration) has been reported in veterinary medicine for use in systemic lupus erythematosus [44], myasthenia gravis, immune-mediated hemolytic anemia [45], and hyperviscosity syndrome (HVS) [43].

In these conditions, even when the plasma is replaced only by isotonic sodium chloride solution, there are no significant changes in the main components of the internal environment (proteins, fats, carbohydrates, electrolytes, hormones, etc.). Newly formed cellular and humoral elements of homeostasis in the “renewed” environment, devoid of “toxic pressure” of the removed pathological metabolites, retain their natural functions and properties for a longer period of time [46].

In our opinion, the wide variations in the clinical manifestation of chronic toxoplasmosis are associated with the abortive immune response and the accumulation of toxic metabolites as a result. The clinical manifestation depends on the individual characteristics of the organism (age, gender, and adequate breeding).

We have tested a method for the application of filtration plasmapheresis in dogs during chronic manifestations of toxoplasmosis, which involves 3–4 procedures with an interval of 2–3 days between them. This completely excludes the complications associated with the subsequent application of antibiotic therapy, makes it possible to fully correct the immunosuppressive state in animals (Fig. 5).

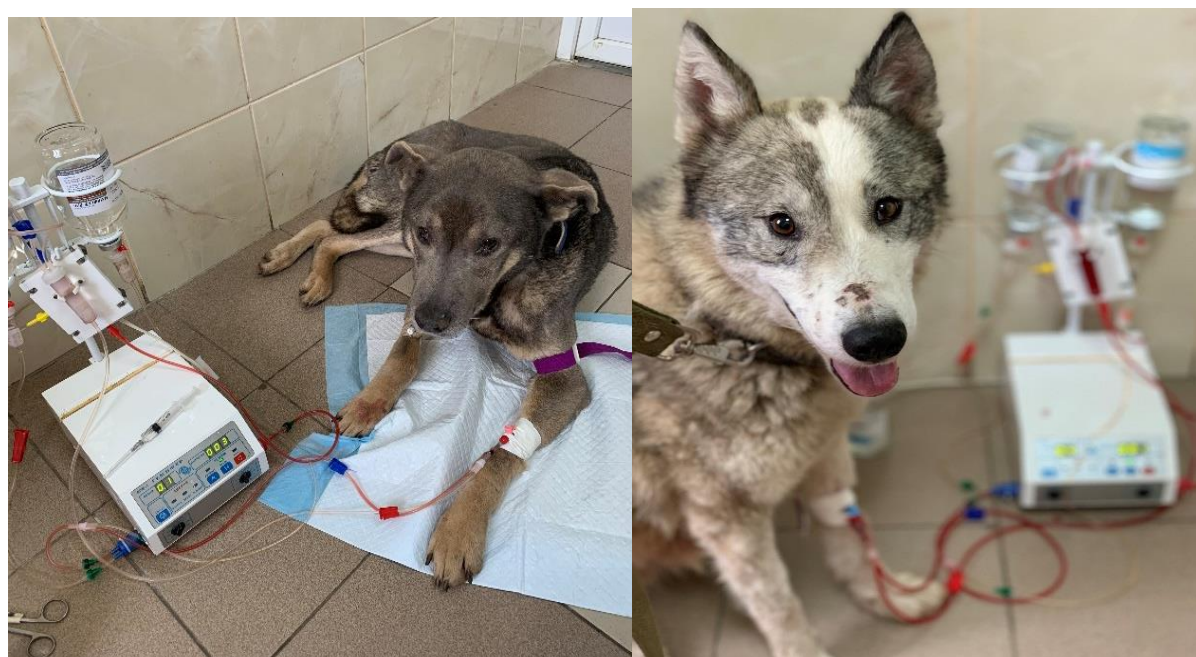

Fig. 5. Plasmapheresis procedure in seropositive dogs for *T. gondii*

Discussion. The testing for the presence of toxoplasmosis in dogs during a clinical examination usually is not performed in veterinary clinics. The main reason for ignoring *T. gondii* diagnosis is the absence of specific clinical signs of toxoplasmosis. Our research has shown that it is almost impossible to get rid of the antigen in the body because there is a periodic activation of the pathogen depending on the season.

Clinical markers that indicate the need to perform a test for toxoplasmosis include chronic renal and hepatic failure, as well as skin lesions and nervous system dysfunction. Taking into consideration the fact that most cases of toxoplasmosis are accompanied by immunosuppression of the T cell immune system, further research aimed at finding the optimal pharmacological agents for conducting immunocorrection for the immunological control of *T. gondii* antigen activity. Carrying out 3–4 procedures of filtration membrane

plasmapheresis in dogs with chronic toxoplasmosis almost excludes possible side effects associated with the use of antibiotics.

Conclusions

1. Dogs with chronic skin dysfunctions require compulsory testing for toxoplasmosis.

2. It is obvious that pharmacological agents with immunotropic action are required during therapy taking into account the long-term persistence of *T. gondii* antigen and consequently the immune response. At the same time, it is necessary to consider the multiple clinical course and features of the immune response.

3. The wide variations in the clinical manifestation of chronic toxoplasmosis are associated with the abortive immune response and the accumulation of toxic metabolites as a result. The clinical manifestation depends on the individual characteristics of the organism (age, gender, and adequate breeding).

4. Assuming that most cases of toxoplasmosis are accompanied by immunosuppression of the T cell immune system, further research aimed at finding the optimal pharmacological agents for conducting immunocorrection for the immunological control of *T. gondii* antigen activity. Carrying out 3–4 procedures of filtration membrane plasmapheresis in dogs with chronic toxoplasmosis almost excludes possible side effects associated with the use of antibiotics.

References

1. Webster JP, Dubey, J.P. Toxoplasmosis of Animals and Humans. Parasites & Vectors [Internet]. 2010;3(1):112. Available from: <https://doi.org/10.1186/1756-3305-3-112>
2. Calero-Bernal R, Gennari SM. Clinical Toxoplasmosis in Dogs and Cats: An Update [Internet]. Frontiers in Veterinary Science. 2019; 6. Available from: <https://doi.org/10.3389/fvets.2019.00054>
3. Majid A, Khan S, Jan AH, Taib M, Adnan M, Ali I, et al. Chronic toxoplasmosis and possible risk factors associated with pregnant women in Khyber Pakhtunkhwa. Biotechnology & Biotechnological Equipment. 2016 Jul 3;30(4).
4. Dubey J. Toxoplasmosis in Dogs [Internet]. The MSD Veterinary Manual. 2018 [cited 2021 Oct 25]. Available from: <https://www.msdsvetmanual.com/en-au/dog-owners/disorders-affecting-multiple-body-systems-of-dogs/toxoplasmosis-in-dogs#>
5. Silva RC da, Souza LC de, Langoni H, Tanaka EM, Lima VY de, Silva AV da. Risk factors and presence of antibodies to *Toxoplasma gondii* in dogs from the coast of São Paulo State, Brazil. Pesquisa Veterinária Brasileira. 2010 Feb;30(2).

6. Dubey J, Beattie C. Toxoplasmosis of animals and man. Boca Raton, FL: CRC Press; 1988.
7. Frenkel JK. Toxoplasmosis in human beings. Journal of the American Veterinary Medical Association. 1990 Jan 15;196(2).
8. Hall SM. Toxoplasmosis. Journal of Small Animal Practice. 1986 Oct;27(10).
9. Literák I, Rychlík I, Svobodová V, Pospíšil Z. Restriction fragment length polymorphism and virulence of Czech *Toxoplasma gondii* strains. International Journal for Parasitology. 1998 Sep;28(9).
10. Frenkel JK. Biology of *Toxoplasma gondii*. In: Congenital toxoplasmosis. Paris: Springer Paris; 2000.
11. Raviolov RK, Gerasimov VV, Vorobieva MN. Toxoplasmosis of domestic carnivores. Kazan: Pechatny dvor; 2008.
12. Limon G, Burrells A, Dadios N, Hosein S, Vince L, Crotta M, et al. *Toxoplasma gondii*: Level of exposure in pigs and cattle in the UK and a hypothetical model for human exposure [Internet]. London; 2016 [cited 2021 Oct 25]. Available from: <https://old.food.gov.uk/sites/default/files/fs517004finalreport.pdf>
13. Buzoni-Gatel D, Schulthess J, Menard LC, Kasper LH. Mucosal defences against orally acquired protozoan parasites, emphasis on *Toxoplasma gondii* infections. Cellular Microbiology. 2006 Apr;8(4).
14. Lueder CGK, Rahman T. Impact of the host on *Toxoplasma* stage differentiation. Microbial Cell. 2017 Jul 3;4(7).
15. Montoya J, Liesenfeld O. Toxoplasmosis. The Lancet. 2004 Jun;363(9425).
16. Mendez OA, Koshy AA. *Toxoplasma gondii*: Entry, association, and physiological influence on the central nervous system. PLOS Pathogens. 2017 Jul 20;13(7).
17. Igarashi M, Kano F, Tamekuni K, Machado RZ, Navarro IT, Vidotto O, et al. *Toxoplasma gondii*: Evaluation of an intranasal vaccine using recombinant proteins against brain cyst formation in BALB/c mice. Experimental Parasitology. 2008 Mar;118(3).
18. Scandella E, Bolinger B, Lattmann E, Miller S, Favre S, Littman DR, et al. Restoration of lymphoid organ integrity through the interaction of lymphoid tissue–inducer cells with stroma of the T cell zone. Nature Immunology 2008 9:6 [Internet]. 2008 Apr 20 [cited 2021 Oct 26];9(6):667–75. Available from: <https://www.nature.com/articles/ni.1605>
19. St John AL, Abraham SN. Salmonella disrupts lymph node architecture by TLR4-mediated suppression of homeostatic chemokines. Nature Medicine. 2009 Nov 25;15(11).

20. Smielewska-Los E, Rypula K, Dzimira S. Studies on congenital toxoplasmosis in canines. *Medycyna Weterynaryjna*. 2003;59(2):141–5.
21. Taques IIGG, Barbosa TR, Martini A de C, Pitchenin LC, Braga ÍA, de Melo ALT, et al. Molecular assessment of the transplacental transmission of *Toxoplasma gondii*, *Neospora caninum*, *Brucella canis* and *Ehrlichia canis* in dogs. *Comparative Immunology, Microbiology and Infectious Diseases*. 2016 Dec;49.
22. Al-Qassab S, Reichel MP, Su C, Jenkins D, Hall C, Windsor PA, et al. Isolation of *Toxoplasma gondii* from the brain of a dog in Australia and its biological and molecular characterization. *Veterinary Parasitology*. 2009 Oct;164(2–4).
23. Koch M, Weiss R, Cruz A, Soccol V, Gonçalves K, Bertol M, et al. Detection and isolation of *Toxoplasma gondii* from fresh semen of naturally infected dogs in Southern Brazil. *Reproduction in Domestic Animals*. 2016 Aug;51(4).
24. Arantes TP, Lopes WDZ, Ferreira RM, Pieroni JSP, Pinto VMR, Sakamoto CA, et al. *Toxoplasma gondii*: Evidence for the transmission by semen in dogs. *Experimental Parasitology*. 2009 Oct;123(2).
25. Malmasi A, Mosallanejad B, Mohebbi M, Sharifian Fard M, Taheri M. Prevention of Shedding and Re-Shedding of *Toxoplasma gondii* Oocysts in Experimentally Infected Cats Treated with Oral Clindamycin: A Preliminary Study. *Zoonoses and Public Health*. 2009 Mar;56(2).
26. Dubey JP, Lindsay DS, Lappin MR. Toxoplasmosis and Other Intestinal Coccidial Infections in Cats and Dogs. *Veterinary Clinics of North America - Small Animal Practice*. 2009 Nov;39(6):1009–34.
27. Dubey JP, Lindsay DS, Speer CA. Structures of *Toxoplasma gondii* Tachyzoites, Bradyzoites, and Sporozoites and Biology and Development of Tissue Cysts. *Clinical Microbiology Reviews* [Internet]. 1998 [cited 2021 Oct 26];11(2):267. Available from: /pmc/articles/PMC106833/
28. Konstantinovic N, Guegan H, Stājner T, Belaz S, Robert-Gangneux F. Treatment of toxoplasmosis: Current options and future perspectives. *Food and Waterborne Parasitology*. 2019 Jun 1;15:e00036.
29. Alday PH, Doggett JS. Drugs in development for toxoplasmosis: advances, challenges, and current status. *Drug Design, Development and Therapy* [Internet]. 2017 Jan 25 [cited 2021 Oct 26];11:273. Available from: /pmc/articles/PMC5279849/

30. el Bissati K, Levigne P, Lykins J, Adlaoui EB, Barkat A, Berraho A, et al. Global initiative for congenital toxoplasmosis: an observational and international comparative clinical analysis. *Emerging Microbes & Infections*. 2018 Dec 1;7(1).
31. Chang HR, Comte R, Pechère JC. In vitro and in vivo effects of doxycycline on *Toxoplasma gondii*. *Antimicrobial Agents and Chemotherapy* [Internet]. 1990 [cited 2021 Oct 26];34(5):775. Available from: [/pmc/articles/PMC171690/?report=abstract](https://pubmed.ncbi.nlm.nih.gov/171690/)
32. Foot AB, Garin YJ, Ribaud P, Devergie A, Derouin F, Gluckman E. Prophylaxis of toxoplasmosis infection with pyrimethamine/sulfadoxine (Fansidar) in bone marrow transplant recipients. *Bone marrow transplantation*. 1994 Aug;14(2).
33. Ben-Harari RR, Goodwin E, Casoy J. Adverse Event Profile of Pyrimethamine-Based Therapy in Toxoplasmosis: A Systematic Review. *Drugs in R&D* [Internet]. 2017 Dec 1 [cited 2021 Oct 26];17(4):523. Available from: [/pmc/articles/PMC5694419/](https://pubmed.ncbi.nlm.nih.gov/294419/)
34. Rabinovich SA, Tokmalaev AK, Kukina I v, Morozov EN, Maksakovskaia E v, Sadykova VD, et al. Monitoring delagil (chloroquine) efficacy against imported *Plasmodium vivax* strains. *Meditinskaya parazitologiya i parazitarnye bolezni*. 2010;(4):46–8.
35. Hartmann K, Addie D, Belák S, Boucraut-Baralon C, Egberink H, Frymus T, et al. *Toxoplasma Gondii* Infection in Cats. *Journal of Feline Medicine and Surgery*. 2013 Jul 27;15(7).
36. Sánchez-Sánchez R, Vázquez P, Ferre I, Ortega-Mora LM. Treatment of Toxoplasmosis and Neosporosis in Farm Ruminants: State of Knowledge and Future Trends. *Current Topics in Medicinal Chemistry*. 2018 Nov 16;18(15).
37. Dubey JP. Toxoplasmosis in Cats and Dogs. In: *World Small Animal Veterinary Association World Congress*. Mexico-City; 2005.
38. Montazeri M, Mehrzadi S, Sharif M, Sarvi S, Tanzifi A, Aghayan SA, et al. Drug Resistance in *Toxoplasma gondii*. *Frontiers in Microbiology* [Internet]. 2018 Mar 29 [cited 2021 Oct 26];9:2587. Available from: [/pmc/articles/PMC6215853/](https://pubmed.ncbi.nlm.nih.gov/3015853/)
39. Vasiliev V. Toxoplasmosis: modern scientific and practical approaches. 2001.
40. Taylor GA, Collazo CM, Yap GS, Nguyen K, Gregorio TA, Taylor LS, et al. Pathogen-specific loss of host resistance in mice lacking the IFN-gamma -inducible gene IGTP. *Proceedings of the National Academy of Sciences*. 2000 Jan 18;97(2).
41. Omelchuk ST, Velikaya NV, Zalesky VN. Mechanisms of xenobiotics detoxification: balance support of the detoxification by the components of plant food product [Internet]. one health and nutritional problems in Ukraine. 2015 [cited 2021 Oct 27]. Available from: <http://pronut.medved.kiev.ua/index.php/en/issues/2015/1/item/440-mechanisms-of->

xenobiotics-detoxification-balance-support-of-the-detoxification-by-the-components-of-plant-food-product/440-mechanisms-of-xenobiotics-detoxification-balance-support-of-the-detoxification-by-the-components-of-plant-food-product

42. Toft P, Schmidt R, Broechner AC, Nielsen BU, Bollen P, Olsen KE. Effect of Plasmapheresis on the Immune System in Endotoxin-Induced Sepsis. *Blood Purification*. 2008;26(2).

43. Lippi I, Perondi F, Ross SJ, Marchetti V, Lubas G, Guidi G. Double filtration plasmapheresis in a dog with multiple myeloma and hyperviscosity syndrome. *Open Veterinary Journal* [Internet]. 2015 [cited 2021 Oct 26];5(2):108. Available from: [/pmc/articles/PMC4663801/](https://pubmed.ncbi.nlm.nih.gov/2663801/)

44. Matus RE, Gordon BR, Leifer CE, Saal S, Hurvitz AI. Plasmapheresis in five dogs with systemic immune-mediated disease. Vol. 187, *Journal of the American Veterinary Medical Association* (USA). 1985. p. 595–9.

45. Crump KL, Seshadri R. Use of therapeutic plasmapheresis in a case of canine immune-mediated hemolytic anemia. *Journal of Veterinary Emergency and Critical Care*. 2009 Aug;19(4).

46. Boyarintsev V, Evseev M. Metabolism and nutritional support in surgical patients [Internet]. Saint-Petersburg: Only-Press; 2017 [cited 2021 Oct 27]. Available from: <https://www.bbraun.ru/content/dam/b-braun/ru/website/products-and-therapies/nutrition-therapy/pdf/BMR-C-700190-BROCHURE-Metabolism-and-nutritional-support.pdf>