

Luts B. V. Radiotherapy in the comprehensive treatment of rectal cancer. *Journal of Education, Health and Sport*. 2022;12(5):393-401. eISSN 2391-8306. DOI <http://dx.doi.org/10.12775/JEHS.2022.12.05.031>
<https://apcz.umk.pl/JEHS/article/view/JEHS.2022.12.05.031>
<https://zenodo.org/record/7068102>

The journal has had 40 points in Ministry of Education and Science of Poland parametric evaluation. Annex to the announcement of the Minister of Education and Science of December 1, 2021. No. 32343. Has a Journal's Unique Identifier: 201159. Scientific disciplines assigned: Physical Culture Sciences (Field of Medical Sciences and health sciences); Health Sciences (Field of Medical Sciences and Health Sciences).

Punkty Ministerialne z 2019 - aktualny rok 40 punktów. Załącznik do komunikatu Ministra Edukacji i Nauki z dnia 1 grudnia 2021 r. Lp. 32343. Posiada Unikatowy Identyfikator Czasopisma: 201159. Przypisane dyscypliny naukowe: Nauki o kulturze fizycznej (Dziedzina nauk medycznych i nauk o zdrowiu); Nauki o zdrowiu (Dziedzina nauk medycznych i nauk o zdrowiu).

© The Authors 2022;

This article is published with open access at Licensee Open Journal Systems of Nicolaus Copernicus University in Torun, Poland

Open Access. This article is distributed under the terms of the Creative Commons Attribution Noncommercial License which permits any noncommercial use, distribution, and reproduction in any medium, provided the original author(s) and source are credited. This is an open access article licensed under the terms of the Creative Commons Attribution Non commercial license Share alike. (<http://creativecommons.org/licenses/by-nc-sa/4.0/>) which permits unrestricted, non commercial use, distribution and reproduction in any medium, provided the work is properly cited.

The authors declare that there is no conflict of interests regarding the publication of this paper.

Received: 29.04.2022. Revised: 11.05.2022. Accepted: 31.05.2022.

Radiotherapy in the comprehensive treatment of rectal cancer

B. V. Luts

Assistant of the department of oncology of the **Uzhgorod National University**

dr.lucbogdan@gmail.com

ORCID: <https://orcid.org/0000-0003-3969-601X>

Abstract

Introduction. A favorable outcome of the treatment of patients with rectal cancer in the early stages is not a difficult task, as it is easily solved thanks to only surgical intervention. The biggest problem is the treatment of patients with late-stage (III and IV) rectal cancer. The use of radiation therapy is an integral niche in the complex treatment of rectal cancer. Complete or partial clinical response of the tumor to neoadjuvant therapy is a favorable factor that correlates with an increase in overall and recurrence-free survival of patients with rectal cancer.

Aim. To conduct an analysis of the effectiveness of radiotherapy and neoadjuvant chemoradiotherapy in the complex treatment of rectal cancer based on the results of the tumor's clinical response to the treatment.

Research results. In both groups of patients, the tumor was localized in the middle ampullary part of the rectum in 52.6% of the main group and 55.4% of the control group. In the lower ampullary section of the rectum in 22 patients of the main group (38.6%) and in 22 (39.3%) of the control group, respectively. The number of patients with tumor localization in the upper ampullary region was 5 (8.8%) and 35 (5.3%), respectively. Positive dynamics in

the form of replacement of tumor tissue by fibrosis was observed in 89 (78.7%) patients in the compared groups. A complete clinical response was noted in 2 (3.5%) patients in the main group and in 1 (1.8%) in the control group. In 86 patients in the compared groups, II and III degrees of tumor regression according to TRG grading were recorded in 43 (75.4%) patients in the main group and 43 (76.8%) in the control group.

Conclusions. In both groups, the tumor was most often localized in the middle ampullary part of the rectum, 52.6% in the main group and 55.4% of the control group. Positive dynamics in the form of replacement of tumor tissue by fibrosis was observed in 89 (78.7%) patients in the compared groups. A complete clinical response was noted in 2 (3.5%) patients in the main group and in 1 (1.8%) in the control group. Unsatisfactory dynamics in the form of IV and V degrees of tumor regression according to the TRG grading were noted in 12 (21.05%) patients of the main group and in 12 (21.4%) - in the control group.

Key words: neoadjuvant chemoradiotherapy; tumor process; rectal cancer; recurrence-free survival; localregional recurrences; radiotherapy.

Introduction. Treatment of patients with locally advanced rectal cancer (LARC) is a complex problem that requires the coordinated work of a whole team of oncologists of various specialties. In the absence of active treatment, the median life expectancy of patients with relapses of LARC is about 8 months [1, 2].

As a result of previously conducted numerous studies, a complex approach consisting of neoadjuvant radiotherapy and chemoradiotherapy with fluoropyrimidines, subsequent surgery and adjuvant chemotherapy has become the standard of treatment for patients with LARC. With the full implementation of this approach, the level of local recurrence does not exceed 10%, the overall 5-year survival of patients with a locally advanced form of the disease reaches 60%. A careful study of the problems of radiation and chemoradiation at the neoadjuvant stage of treatment of patients with LARC in modern literature, many authors indicate the absence of significant differences in oncological outcome indicators [3].

A complete or partial clinical response of the tumor to neoadjuvant therapy is a favorable factor that correlates with an increase in overall and recurrence-free survival rates of patients with LARC [4]. Achieving such a response can allow the transfer of a part of initially unresectable tumors to a resectable state [5, 6]. Preoperative chemoradiotherapy can affect both the volume of viable tumor mass in the wall of the rectum and affected lymph nodes, including causing its complete elimination. Such regression of the tumor with a decrease in the assessment of T and N categories compared to the preoperative ones is used to assess the

clinical response [7]. The decrease in the size of the tumor began to be considered as a sign of its radiosensitivity and an important prognostic factor that correlates with the survival rates of cancer patients [8].

Aim. To conduct an analysis of the effectiveness of radiotherapy and neoadjuvant chemoradiotherapy in the complex treatment of rectal cancer based on the results of the tumor's clinical response to the treatment.

Materials and methods. The analysis of the results of the treatment of 113 patients with locally disseminated rectal cancer (cT3c-4N1-2M0, with the presence of extramural vascular invasion (EMVI - extramural vascular invasion), a positive circular resection margin ≤ 1 mm (CRM+ - circumferential resection margin), which in the departments of radiation therapy, chemotherapy, and tumor surgery department of the Transcarpathian Antitumor Center from 2019 to 2022. A prolonged course of neoadjuvant chemoradiotherapy, neoadjuvant radiotherapy, and subsequent surgical intervention was conducted. The study was conducted in compliance with the ethical principles prescribed in Declaration of Helsinki.

The diagnosis of locally advanced rectal cancer was established on the basis of the following diagnostic manipulations, studies and analyses: digital rectal examination, rectomanoscopy, colonoscopy with biopsy, irrigoscopy when colonoscopy was not possible, and magnetic resonance imaging (MRI).

To rule out the presence of distant metastases, patients were prescribed the following diagnostic tools: ultrasound examination of the pelvis and abdominal cavity, as well as the retroperitoneal space, or computer tomography (CT) of the abdominal cavity with intravenous (iv) contrast, X-ray chest organs, positron emission computed tomography (PET/CT) in case of suspicion of metastases based on CT or MRI data.

The patients were divided into two groups: the first (main) group included 57 patients with LARC, who, as part of the neoadjuvant stage of treatment, received only a course of neoadjuvant radiotherapy (NRT) in the fractionation regime (SFD 1.8 Gr/d, 5 fractions per week, TFD 50.4 Gr on the regional lymph nodes of the pelvis and on the primary tumor and affected lymph nodes).

The second group (control group) included 56 patients with LARC who underwent a course of neoadjuvant radiochemotherapy (NHRT) in the mode of classical fractionation (SFD 1.8 Gr/d, 5 fractions per week, TFD 50.4 Gr on the regional lymph nodes of the pelvis and on the primary tumor and affected lymph nodes) with capecitabine potentiation (825 mg/m² 2 t/d 5 days a week).

To assess the therapeutic effect, the tumor regression grade assessment scale based on

MRI data (TRG, tumor regression grade) was used [9]:

TRG 1 – absence of MR evidence of the presence of tumor tissue, or total replacement of the tumor volume by fibrosis;

TRG 2 - MR signs of the presence of tumor tissue, more than 50% of the primary tumor is replaced by fibrous changes;

TRG 3 - MR signs of the presence of tumor tissue, from 25 to 50% of the primary tumor is replaced by fibrous changes;

TRG 4 - MR signs of the presence of tumor tissue, less than 25% of the primary tumor is replaced by fibrous changes;

TRG 5 – no signs of tumor regression, no fibrosis.

Results and discussion

In the main group, the gender distribution was as follows: 22 women (38%) and 35 men (62%). In the control group, these indicators were 25 (45%) and 31 (55%), respectively, $p=0.443$. The distribution of patients by age is presented in table 1.

Table 1

Distribution of patients by age

Indicator	Main group n=57(%)		Control group n=56(%)		p
Age: up to 40		average age 57.0		average age 56.4	0.720
41-50	6(10.5%)		7 (12.5)		
51-60	6(10.5%)		6 (10.7)		
61 and older	20 (35.0%)		20 (35.7)		
	25 (44.0%)		23 (41.1)		

As can be seen from table 1, the majority of patients in the studied groups were in the age group of 61 and older. The number of patients under the age of 40 was 6 (10.5%) in the main group and 7 (12.5%) in the control group. There were 25 patients older than 61 years in the main group, and 23 patients in the control group, which was 44.0% and 41.1%, respectively. The average age of patients in our study was 56.7 ± 2.06 years.

In patients with LARC, the localization of the tumor in the rectum is one of the most important factors of the prognosis, which, along with the stage of the tumor process, determines the choice of treatment tactics.

The distribution of patients depending on the location of the tumor in the rectal sections in the comparison groups is presented in figure 1.

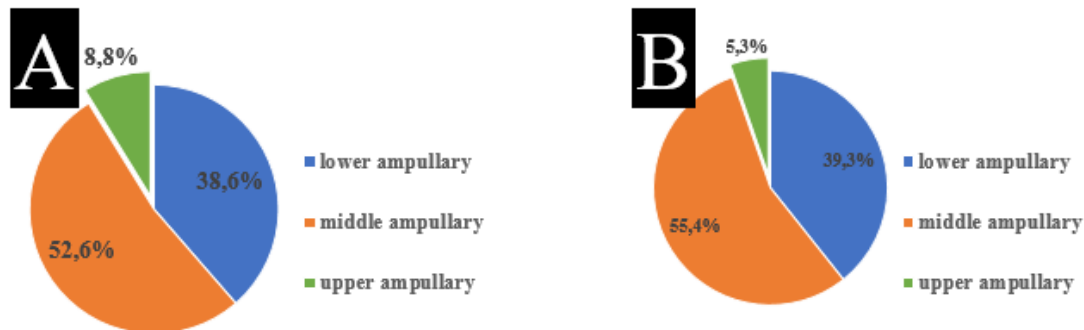


Figure 1. Distribution of patients with LARC depending on the location of the tumor in the rectum; A - main group, n = 57; B - control group, n = 56.

As can be seen from figure 1, in most patients in both groups, the tumor was localized in the middle ampullary part of the rectum, 52.6% in the main group and 55.4% in the control group. In the lower ampullary section of the rectum in 22 patients of the main group (38.6%) and in 22 (39.3%) of the control group, respectively. The number of patients with tumor localization in the upper ampullary region was 5 (8.8%) and 3 (5.3%), respectively. There were no statistically significant differences in tumor localization in the rectum in the compared groups, $p > 0.05$.

In all patients, the rectal tumor was morphologically verified. The degree of differentiation of tumor cells was determined taking into account the criteria of the international histological classification of tumors (WHO, 2010). The analysis of the obtained data of all patients showed that highly differentiated adenocarcinoma was observed in 20 (17.7%) patients, moderately differentiated adenocarcinoma - in 55 (48.7%), poorly differentiated adenocarcinoma - in 17 (15%), undifferentiated adenocarcinoma - in 7 (6.2%), "mucinous" adenocarcinoma - in 9 (8%), and squamous cell carcinoma - in 5 (4.4%).

The distribution of patients according to the morphological structure of the tumor is presented in figure 2.

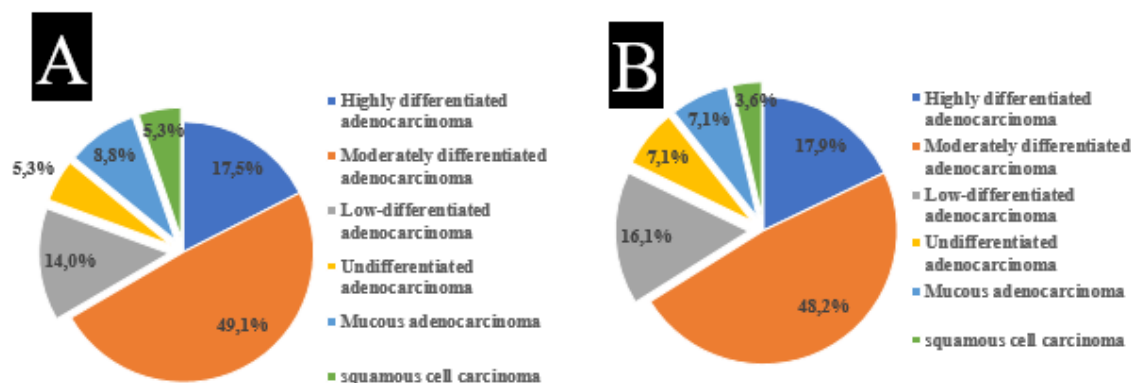


Figure 2. Morphological structure and degree of tumor differentiation in the main group (A) and in the control group (B), n=113.

As can be seen from Figure 2, moderate differentiated adenocarcinoma was verified in the majority of patients in the comparison groups: 49.1% and 48.2%, respectively. In 19.4% of patients in the main group and in 17.8% in the control group, relatively rare morphological forms of rectal cancer (undifferentiated adenocarcinoma, mucosal adenocarcinoma, and squamous cell carcinoma) were verified.

In order to assess the clinical response of the tumor to NRT and NHRT, all 113 patients with MRPC underwent a follow-up MRI of the pelvic organs after an average of 7.2 (95% CI 6.7 to 7.6) weeks. To evaluate the clinical effect, the scale for assessing the degree of tumor regression at MRI (TRG) was used. The results of the assessment of the clinical response to HRT in patients in the comparison groups are presented in Table 2.

Table 2

The degree of tumor regression in patients after a course of NRT and NHRT, n=113

Indicator	Main group n=57 Abs (%)	Control group n=56 Abs (%)
TRG 1	2 (3.5)	1 (1.8)
TRG 2	12 (21)	11 (19.6)
TRG 3	31(54.4)	32 (57.1)
TRG 4	11 (19.3)	8 (14.4)
TRG 5	1 (1.8)	4 (7.1)

As can be seen from the data presented in table 2, positive dynamics in the form of replacement of tumor tissue by fibrosis was observed in 89 (78.7%) patients in the compared groups. A complete clinical response was noted in 2 (3.5%) patients in the main group and in

1 (1.8%) in the control group. In 86 patients in the compared groups, II and III degrees of tumor regression according to TRG grading were recorded in 43 (75.4%) patients in the main group and 43 (76.8%) in the control group. Unsatisfactory dynamics in the form of IV and V degrees of tumor regression according to the TRG grading were noted in 12 (21.05%) patients of the main group and in 12 (21.4%) - in the control group.

The goal of radiation therapy is to deliver a therapeutically effective dose to the target while reducing the dose in the surrounding healthy organs and tissues below values, exceeding which the risk of post-radiation damage becomes unacceptable.

Pre-radiation preparation of patients for HRT takes a special place for planning the amount of radiation exposure. The use of modern radiodiagnostic methods before the start of RT in rectal cancer, such as MRI, makes it possible to clarify the degree of spread of the primary tumor, its spread into the surrounding tissue, involvement of regional lymph nodes. These data are the basis for choosing the amount of radiation exposure

The clinical response of the tumor to therapy is a change in the linear dimensions of the neoplasm, determined by radiological research methods, and its assessment is of key importance for determining the tactics of further treatment.

Evaluation of the clinical response of the tumor to neoadjuvant therapy is based on the results of clinical and instrumental studies, such as: digital examination of the rectum, colonoscopy and MRI of the pelvic organs. MRI is a leading diagnostic method that allows to assess the dynamics of changes in tumor size, the depth of invasion, the condition of regional lymph nodes, and the volume of tumor tissue replaced by fibrous tissue (TRG - tumor regression grade).

Conclusions

1. In both groups, the tumor was most often localized in the middle ampullary part of the rectum, 52.6% in the main group and 55.4% of the control group.

2. Positive dynamics in the form of replacement of tumor tissue by fibrosis was observed in 89 (78.7%) patients in the compared groups. A complete clinical response was noted in 2 (3.5%) patients in the main group and in 1 (1.8%) in the control group.

3. Unsatisfactory dynamics in the form of IV and V degrees of tumor regression according to the TRG grading were noted in 12 (21.05%) patients of the main group and in 12 (21.4%) - in the control group.

References (APA)

1. Bujko, K., Wyrwicz, L., Rutkowski, A., Malinowska, M., Pietrzak, L., Kryński, J., ... & Polish Colorectal Study Group. (2016). Long-course oxaliplatin-based preoperative chemoradiation versus 5× 5 Gy and consolidation chemotherapy for cT4 or fixed cT3 rectal cancer: results of a randomized phase III study. *Annals of oncology*, 27(5), 834-842.
2. Lee, S. U., Kim, D. Y., Kim, S. Y., Baek, J. Y., Chang, H. J., Kim, M. J., ... & Oh, J. H. (2013). Comparison of two preoperative chemoradiotherapy regimens for locally advanced rectal cancer: capecitabine alone versus capecitabine plus irinotecan. *Radiation Oncology*, 8(1), 1-7.
3. Jiao, D., Zhang, R., Gong, Z., Liu, F., Chen, Y., Yu, Q., ... & Jia, J. (2015). Fluorouracil-based preoperative chemoradiotherapy with or without oxaliplatin for stage II/III rectal cancer: a 3-year follow-up study. *Chinese Journal of Cancer Research*, 27(6), 588.
4. Golo, D., But-Hadzic, J., Anderluh, F., Breclj, E., Edhemovic, I., Jeromen, A., ... & Velenik, V. (2018). Induction chemotherapy, chemoradiotherapy and consolidation chemotherapy in preoperative treatment of rectal cancer-long-term results of phase II OIGIT-01 Trial. *Radiology and oncology*, 52(3), 267-274.
5. Bahadoer, R. R., Dijkstra, E. A., van Etten, B., Marijnen, C. A., Putter, H., Kranenbarg, E. M. K., ... & Silviera, M. L. (2021). Short-course radiotherapy followed by chemotherapy before total mesorectal excision (TME) versus preoperative chemoradiotherapy, TME, and optional adjuvant chemotherapy in locally advanced rectal cancer (RAPIDO): a randomised, open-label, phase 3 trial. *The Lancet Oncology*, 22(1), 29-42.
6. Simson, D. K., Mitra, S., Ahlawat, P., Saxena, U., Sharma, M. K., Rawat, S., ... & Tanwar, A. (2018). Prospective study of neoadjuvant chemoradiotherapy using intensity-modulated radiotherapy and 5 fluorouracil for locally advanced rectal cancer—toxicities and response assessment. *Cancer Management and Research*, 10, 519.
7. Liu, S. X., Zhou, Z. R., Chen, L. X., Yang, Y. J., Hu, Z. D., & Zhang, T. S. (2015). Short-course versus long-course preoperative radiotherapy plus delayed surgery in the treatment of rectal cancer: a meta-analysis. *Asian Pacific Journal of Cancer Prevention*, 16(14), 5755-5762.
8. Van der Valk, M. J., Hilling, D. E., Bastiaannet, E., Kranenbarg, E. M. K., Beets, G. L., Figueiredo, N. L., ... & Zimmerman, D. D. (2018). Long-term outcomes of clinical complete responders after neoadjuvant treatment for rectal cancer in the International

Watch & Wait Database (IWWD): an international multicentre registry study. *The Lancet*, 391(10139), 2537-2545.

9. Patel, U. B., Brown, G., Machado, I., Santos-Cores, J., Pericay, C., Ballesteros, E., ... & Fernandez-Martos, C. (2017). MRI assessment and outcomes in patients receiving neoadjuvant chemotherapy only for primary rectal cancer: long-term results from the GEMCAD 0801 trial. *Annals of Oncology*, 28(2), 344-353.