

Wróbel-Roztropiński Artur, Zagacki Dawid, Kruczykowska Lidia, Kozakiewicz Marcin. Infections in the maxillofacial region in the clinic material – retrospective analysis. *Journal of Education, Health and Sport*. 2022;12(4):117-126. e-ISSN 2391-8306. DOI <http://dx.doi.org/10.12775/JEHS.2022.12.04.010>  
<https://apcz.umk.pl/JEHS/article/view/JEHS.2022.12.04.010>  
<https://zenodo.org/record/6451103>

The journal has had 40 points in Ministry of Education and Science of Poland parametric evaluation. Annex to the announcement of the Minister of Education and Science of December 21, 2021. No. 32343. Has a Journal's Unique Identifier: 201159. Scientific disciplines assigned: Physical Culture Sciences (Field of Medical sciences and health sciences); Health Sciences (Field of Medical Sciences and Health Sciences).

Punkty Ministerialne z 2019 - aktualny rok 40 punktów. Załącznik do komunikatu Ministra Edukacji i Nauki z dnia 21 grudnia 2021 r. Lp. 32343. Posiada Unikatowy Identyfikator Czasopisma: 201159. Przepisane dyscypliny naukowe: Nauki o kulturze fizycznej (Dziedzina nauk medycznych i nauk o zdrowiu); Nauki o zdrowiu (Dziedzina nauk medycznych i nauk o zdrowiu).

© The Authors 2022;

This article is published with open access at Licensee Open Journal Systems of Nicolaus Copernicus University in Torun, Poland  
Open Access. This article is distributed under the terms of the Creative Commons Attribution Noncommercial License which permits any noncommercial use, distribution, and reproduction in any medium, provided the original author (s) and source are credited. This is an open access article licensed under the terms of the Creative Commons Attribution Non commercial license Share alike. (<http://creativecommons.org/licenses/by-nc-sa/4.0/>) which permits unrestricted, non commercial use, distribution and reproduction in any medium, provided the work is properly cited.  
The authors declare that there is no conflict of interests regarding the publication of this paper.

Received: 26.03.2022. Revised: 30.03.2022. Accepted: 12.04.2022.

## **Infections in the maxillofacial region in the clinic material – retrospective analysis**

**Artur Wróbel-Roztropiński**  
**Klinika Chirurgii Szczękowo-Twarzowej, Uniwersytet Medyczny w Łodzi**

**Dawid Zagacki**  
**Międzynarodowa Szkoła Doktorska Uniwersytetu Medycznego w Łodzi**

**Lidia Kruczykowska**  
**Klinika Chirurgii Szczękowo-Twarzowej, Uniwersytet Medyczny w Łodzi**

**Marcin Kozakiewicz**  
**Klinika Chirurgii Szczękowo-Twarzowej, Uniwersytet Medyczny w Łodzi**

### **Abstract**

Infections in the maxillofacial and neck region are a serious problem nowadays. Lately diagnosed infection may lead to many hazardous complications including spreading through superior thoracic aperture to the mediastinum. That affects everyday life of patients, including his ability to work. The aim of this study was to analyze the factors affecting work inability associated with the treatment of maxillofacial and neck infections. We made a retrospective analysis of medical documentation of patients treated in our Department due to the infections of maxillofacial and neck region. In our research, mostly men were burden with infections in the maxillofacial region and neck (64.3%). Patient presented poor oral hygiene thus the main cause of the infection was periodontal. Treatment period (including hospitalization and inability to work) varied from 1 up to 124 days; Mostly affected are patients in their 3<sup>rd</sup> and

4<sup>th</sup> decade of life when they are professionally active. A proper treatment (including surgical and pharmacological) is required to allow those patients come back to their everyday life.

**Keywords:** infections; work inability; maxillofacial surgery; treatment; maxillofacial area; odontogenic maxillofacial infections; disabled worker

## **1. Introduction**

Oral cavity is a microhabitat for over 700 species of bacteria. Every manipulation in oral cavity may lead to the dysbiosis and thus resulting in the oral pathology. Untreated teeth carries, periodontal disease, trauma or even dental procedures performed in oral cavity may result in the spread of odontogenic infection [1].

One of the common complications is neck abscess due to its anatomy with many interfascial spaces between soft tissues of the neck and unusually developed lymphatic system with over 300 lymph nodes present.

Depending on the primary site of the infection in the oral cavity and oropharynx, abscesses may localize in the submandibular region, retropharyngeal space, peritonsillar space, parotid area, floor of the mouth, masseteric space or pteropalatine maxillary space [2]. From head and neck surgeons' point of view the most common are submandibular area's abscesses which in either extreme or neglected cases may spread through interfascial areas even to superior thoracic aperture to the mediastinum.

Not only the deep neck infection has a hazardous implementation on the general health of the patient, it also affects their everyday life. Patients with advanced abscesses are often disabled from work that results in their absence in working area.

The aim of this study was to present and analyze the abscesses treated in our Department in years 2016 to 2021.

## **2. Materials and Methods**

A retrospective analysis of the medical documentation of patients treated in the Department of Maxillofacial Surgery, Medical University of Łódź was performed. We included to our study patients with neck infections that were hospitalized in our Clinic in the period of time from January 2016 up to September 2021. Patients that did not require hospitalization were excluded from our study.

The following data were collected:

- Patients cohort (age, sex, residence area – urban if a patient was living in a city, rural if a patient was living in a village)
- Patients' general health (co-morbidity, allergies, alcohol abuse)
- Oral hygiene (each patient had had a dental chart performed; if calculus or dental plaque was present and/or relict roots and/or >3 active dental caries the hygiene was described as poor. In other situation it was described as good),
- Diagnosis,
- Side involvement – if the abscess was crossing the centerline of the body was described as a double side involvement, if not – single side involvement,
- Causative agent,
- Performed procedures,
- Bacteriological culture result,
- Antibiotic treatment performed,
- The length of hospitalization,
- Work inability period.

### **3. Results**

#### **3.1. Patients cohort**

All the data about the patients cohort were included in the table 1. 56 patients met our inclusion criteria. 36 of them were men (64.3%) and 20 women (35.7%). The average age was  $45.3 \pm 17.5$  years, median 40 years old. The youngest patient administered to our Department due to the abscess was 21 years old, the oldest – 92 years old. Most patients were in the 3<sup>rd</sup> and 4<sup>th</sup> decades age groups (Fig. 1).

Patients mostly came from urban area (44 patients) and 12 patients had rural origin.

Fig.1. Age distribution

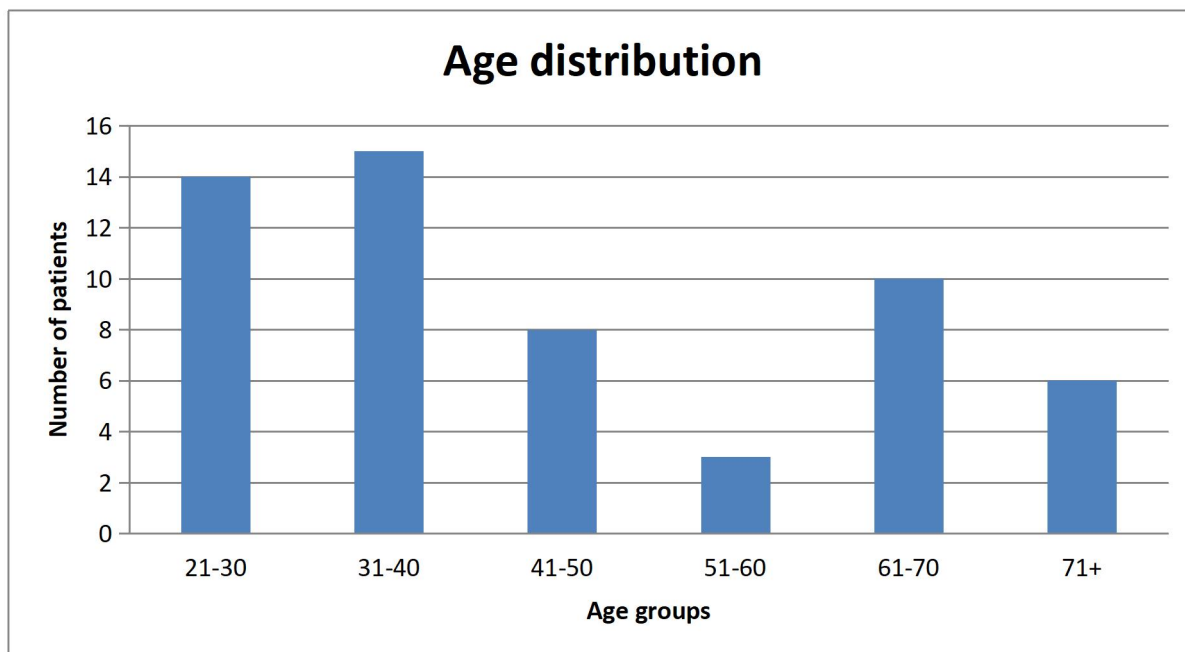


Table 1. Patients cohort – sex, age, residence area, causative agent and side involvement

<u>Patient number</u>	<u>Sex</u>	<u>Age</u>	<u>Residence area</u>	<u>Causative agent</u>
1	Female	21	Urban	Odontogenic
2	Male	21	Urban	Odontogenic
3	Male	71	Urban	Odontogenic
4	Male	27	Urban	Odontogenic
5	Male	26	Urban	Odontogenic
6	Male	26	Rural	Odontogenic
7	Male	68	Rural	Odontogenic
8	Female	58	Urban	Odontogenic
9	Female	80	Urban	Odontogenic
10	Male	31	Urban	Odontogenic
11	Male	26	Urban	Odontogenic
12	Male	62	Urban	Odontogenic
13	Male	47	Urban	Odontogenic
14	Female	28	Rural	Odontogenic
15	Male	39	Urban	Odontogenic
16	Male	28	Rural	Odontogenic
17	Male	45	Urban	Odontogenic
18	Female	74	Urban	Odontogenic
19	Female	68	Urban	Odontogenic
20	Female	46	Rural	Odontogenic
21	Female	34	Urban	Odontogenic
22	Male	40	Urban	Odontogenic
23	Male	39	Urban	Odontogenic
24	Female	63	Urban	Odontogenic
25	Male	32	Urban	Odontogenic
26	Female	65	Urban	Odontogenic
27	Male	38	Urban	Odontogenic

28	Male	30	Rural	Odontogenic
29	Male	61	Urban	Odontogenic
30	Male	28	Urban	Odontogenic
31	Male	31	Urban	Odontogenic
32	Male	50	Urban	Odontogenic
33	Male	30	Urban	Odontogenic
34	Male	22	Rural	Odontogenic
35	Male	49	Rural	Bone fracture
36	Female	55	Urban	Odontogenic
37	Female	32	Urban	Unknown
38	Male	45	Urban	Odontogenic
39	Female	40	Urban	Odontogenic
40	Female	27	Urban	Odontogenic
41	Male	63	Rural	Odontogenic
42	Female	92	Urban	Odontogenic
43	Male	39	Urban	Odontogenic
44	Male	25	Urban	Odontogenic
45	Female	43	Rural	Odontogenic
46	Female	71	Urban	Odontogenic
47	Male	62	Urban	Odontogenic
48	Female	74	Urban	Odontogenic
49	Female	63	Rural	Odontogenic
50	Male	37	Urban	Odontogenic
51	Male	35	Urban	Bone fracture
52	Female	39	Urban	Unknown
53	Male	52	Urban	Odontogenic
54	Male	47	Urban	Odontogenic
55	Male	33	Rural	Odontogenic
56	Male	61	Urban	Odontogenic

### 3.2. Medical examination:

25 patients presented co-morbidity, 55 of them reported allergies (8 drug allergies, 47 medically not related allergies), 23 presented alcohol abuse.

The average body temperature was  $37.0 \pm 0.7^{\circ}\text{C}$ , median  $36.7^{\circ}\text{C}$ .

In 43 patients the oral hygiene remained poor (76.8%) while in 13 patients it was described as good (23.2%).

Out of all patients 38 presented with unilateral inflammation process and 18 with bilateral inflammation.

Most commonly the causative agent was odontogenic (52, 92.9%) other causes included: trauma (2), unknown (2).

### 3.3. Treatment

Out of 56 patients 51 were treated surgically. 42 procedures were performed under general anesthesia, 9 of them were performed in local anesthesia. The drainage was performed up from 0 to 6 times in patients (incision without drainage in 7 patients, 1 incision and drainage was performed in 25 patients, 2 drainages in 10 patients, 3 drainages in 8 patients, 6 drainages in 1 patients). 17 patients had the causative teeth removed during the first surgical procedure. Bacteriology was performed in 27 patients. Bacteria cultivated are shown in the table below (Tab.2).

Table 2. Bacteria cultivated

Bacteria specie	Number of patients
<i>Granulicatella adiacens</i>	1
<i>Klebsiella pneumoniae</i>	2
<i>Rothia mucilaginosa</i>	1
<i>Staphylococcus constelatus</i>	1
<i>Staphylococcus epidermidis</i>	5
<i>Staphylococcus hominis</i>	1
<i>Staphylococcus epidermidis</i> + <i>Streptococcus mitis</i>	1
<i>Staphylococcus pasteurii</i> + <i>staphylococcus anginosus</i>	1
<i>Streptococcus anginosus</i>	1
<i>Streptococcus anginosus</i> + <i>Streptococcus oralis</i>	1
<i>Streptococcus mitis</i>	1
<i>Streptococcus anginosus</i> + <i>Staphylococcus epidermidis</i>	1
Sterile culture	10

Pharmacologically, all patients were treated with antibiotics as well. Polytherapy was performed in 52 patients. The combinations of antibiotics included:

- Cephalosporin + metronidazole (8),
- Penicillin + aminoglycoside (1),
- Penicillin + aminoglycoside + metronidazole (14),
- Penicillin + cephalosporin + metronidazole (2),
- Penicillin + lincosamide + metronidazole (2),
- Penicillin + metronidazole (25).

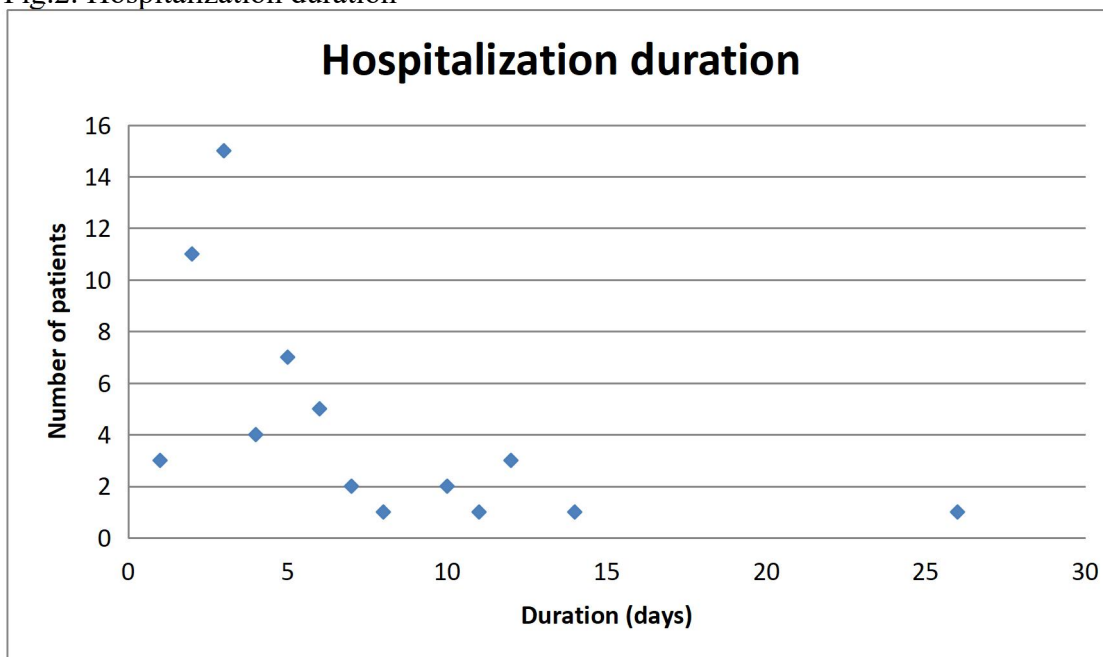
Monotherapy was performed in 4 patients (tetracycline 1, lincosamide 1, penicillin 2)

### 3.4. Work inability:

Hospitalization length ranged from 1 day to 26 days (Fig.2). Antibiotic therapy was introduced during the hospitalization period and was prolonged for 3 to 14 days, average 7 days. Total antibiotic treatment varied in patients from 5 up to 21 days, with average of 12 days and median 12 days.

Some patients due to their health condition also required prolonged work inability. The post hospital recovery varied from 0 days up to 121 days (average 10 days). That resulted in total patients work inability (including hospitalization and work inability) from 1 up to 124 days (average 15 days, median 7 days).

Fig.2. Hospitalization duration



## 4. Discussion

Before introducing antibiotics to the therapy, in the region of head and neck, tonsillar and peritonsillar infections were the main cause of the deep neck infections (DNI) (about 70%) [1]. Nowadays, the main cause of the DNI remains odontogenic (according to some authors it is estimated at 38.8-49%) [2,3,4,5,6,7]. In our case, odontogenic cause of the infection was nearly exclusive (52 out of 56 cases). The increased percentage of odontogenic involvement in our study is probably mostly due to referring patients with other causative agents to otorhinolaryngologists as the second most common cause of DNI is the abscess localized in the peritonsillar area, then salivary glands, foreign bodies and malignancies. What should be highlighted is that most of the patients presented poor oral hygiene (43). It not only presents

the importance of proper oral hygiene (and the role of dentists) but also how low the awareness of the need of proper oral hygiene remains among Polish society.

In our case, mostly male patients were predominant to the DNI (about 1.8:1) and other authors also suggest male predominance [1, 8, 9]. Age range in our study was between 21 up to 92 years with the average of 45 years that is also supported by different publications [1, 10]. Pediatric patients are not referred to our department, that is why the mean age is higher than in publications that also included children [9].

A proper treatment of the infection in the head and neck involves establishing the drainage (either by the incision of soft tissues, through the root canal) or by extracting the causative teeth [11]. Antibiotics are considered as adjuvant therapy when the extra-oral swelling is present, body temperature is increased or the patient's immune system cannot cope properly with inflammation [11]. Most commonly, empirical antibiotic therapy is prescribed for patients. Even though the guidelines may differ in some countries, penicillins are the most commonly prescribed as a first-line treatment [12]. Due to the increased bacterial resistance to the antibiotics the importance of prescribing the antibiotic to the patients is under discussion. Ellison et al. suggest that surgical drainage and the removal of the causative tooth can manage the infection successfully without antibiotics [13]. In our Department, if it was possible, the removal of the causative teeth was performed during the drainage incision (if trismus was present then the procedure was delayed). Performed antibiotic therapy in many cases was empirical – penicillins. Changes were mostly dictated by the reported antibiotic allergies or recently prescribed antibiotics (to minimize the risk of increasing the antibiotic resistance).

In odontogenic infections, most common pathogens include: *Streptococcus milleri*, *Peptostreptococcus*, *Prevotella*, *Porphyromonas*, *Fusobacterium* [14,15]. The unusual findings include: *Rothia mucilaginosa* and *Granulicatella adiacens*. These infections may be called opportunistic affecting patients with immune impairing. That may result in the primary failure and problems with treating such infections and also the identification of the causative bacteria. That may indicate the need of performing the swab from the incision material routinely to minimize the risk of prolonged treatment of the patient (as well as the prolonged use of antibiotics).

A proper management of maxillofacial and neck dissection is the key to minimize the negative effect of the treatment on patients every day life. The prolonging treatment not only generates the costs for the hospital and patient but also affects the budget of the patient by precluding them from their work. Mostly patients in their 3<sup>rd</sup> and 4<sup>th</sup> decade were affected by



the infection so they were professionally active or during their studying. Everyday followup or staying in the hospital does not allow patients to participate in that activities thus resulting in financial loss and work absence until full recovery is obtained.

## 5. Conclusions

Infections in the head and neck region are the reason of the inability to work. It is important to include the proper treatment as soon as it is possible, as mainly affected groups are patients in their 3<sup>rd</sup> and 4<sup>th</sup> decade of life. Thus it results in patients' work inability. In our Clinic, the inability to work varied from 0 up to 121 days, with the average of 10 days. As the most common causative agent of the infections was odontogenic, it highlights the importance of increasing the awareness of the proper oral hygiene.

## References:

1. Pesis M, Bar-Droma E, Ilgiyaev A, Givol N. Deep Neck Infections Are Life Threatening Infections of Dental Origin: a Presentation and Management of Selected Cases. *Isr Med Assoc J.* 2019 Dec;21(12):806-811. PMID: 31814344.
2. Huang TT, Liu TC, Chen PR, Tseng FY, Yeh TH, Chen YS. Deep neck infection: analysis of 185 cases. *Head Neck* 2004; 26: 854-60
3. Parhiscar A, Harel G: Deep neck abscess. a retrospective review of 210 cases. *Ann Otol Rhinol Laryngol* 2001; 110: 1051-4.
4. Bottin R, Marioni G, Rinaldi R. Deep neck infection: a present day complication. A retrospective review of 83 cases (1998–2001). *Eur Arch Otorhinolaryngol* 2003; 260: 576-9.
5. Marioni G, Rinaldi R, Staferi C. Deep neck infection with dental origin: analysis of 85 consecutive cases (2000–2006). *Acta Otolaryngol* 2008; 128: 201-6.
6. Efekharian A, Roozbahany NA, Vaezeafshar R. Deep neck infections: retrospective review of 112 cases. *Eur Arch Otorhinolaryngol* 2009; 266: 273-7.
7. Bakir S, Tanriverdi MH, Gun R, et al. Deep neck space infection: a retrospective review of 173 cases. *Am J Otolaryngol* 2012; 33: 56-63

8. Brito TP, Hazboun IM, Fernandes FL, Bento LR, Zappelini CEM, Chone CT, Crespo AN. Deep neck abscesses: study of 101 cases. *Braz J Otorhinolaryngol.* 2017 May-Jun;83(3):341-348. doi: 10.1016/j.bjorl.2016.04.004. Epub 2016 May 5. PMID: 27236632.
9. Nasir SB, Shuaibu IY, Labaran SA, Inusa A. Management of Deep Neck Space Infections in a Tertiary Center in North West Nigeria. *Niger J Surg.* 2019 Jul-Dec;25(2):183-187. doi: 10.4103/njs.NJS\_19\_19. PMID: 31579374; PMCID: PMC6771174.
10. Kataria G, Saxena A, Bhagat S, Singh B, Kaur M, Kaur G. Deep Neck Space Infections: A Study of 76 Cases. *Iran J Otorhinolaryngol.* 2015 Jul;27(81):293-9. PMID: 26788478; PMCID: PMC4710882.
11. Oral and Dental Expert Group. *Therapeutic Guidelines: Oral and Dental Version 3*; Therapeutic Guidelines Ltd.: Melbourne, Australia, 2019
12. Teoh, L.; Cheung, M.C; Dashper, S.; James, R.; McCullough, M.J Oral Antibiotic for Empirical Management of Acute Dentoalveolar Infections—A Systematic Review. *Antibiotics* 2021, 10, 240. <https://doi.org/10.3390/antibiotics10030240>
13. Ellison, S.J. An outcome audit of three day antimicrobial prescribing for the acute dentoalveolar abscess. *Br. Dent. J.* 2011, 211,591–594
14. Heimdahl A., von Konow L., Satoh T., Nord C.E.: Clinical appearance of orofacial infections of odontogenic origin in relation to microbiological findings. *J. Clin. Microbiol.*, 1985; 22: 299–302
15. Sakamoto H., Kato H., Sato T., Sasaki J.: Semiquantitative bacteriology of closed odontogenic abscesses. *Bull. Tokyo Dent. Coll.*, 1998;39: 103–107