

Yanko Roman, Chaka Elena, Levashov Mikhail. Morphofunctional changes in the rat's liver of different ages after L-methionine administration. *Journal of Education, Health and Sport*. 2022;12(1):125-137. eISSN 2391-8306. DOI <http://dx.doi.org/10.12775/JEHS.2022.12.01.010> <https://apcz.umk.pl/JEHS/article/view/JEHS.2022.12.01.010> <https://zenodo.org/record/5851673>

The journal has had 40 points in Ministry of Education and Science of Poland parametric evaluation. Annex to the announcement of the Minister of Education and Science of December 1, 2021. No. 32343. Has a Journal's Unique Identifier: 201159. Scientific disciplines assigned: Physical Culture Sciences (Field of Medical sciences and health sciences); Health Sciences (Field of Medical Sciences and Health Sciences).

Punkty Ministerialne z 2019 - aktualny rok 40 punktów. Załącznik do komunikatu Ministra Edukacji i Nauki z dnia 1 grudnia 2021 r. l.p. 32343. Posiada Unikatowy Identyfikator Czasopisma: 201159. Przepisane dyscypliny naukowe: Nauki o kulturze fizycznej (Dziedzina nauk medycznych i nauk o zdrowiu); Nauki o zdrowiu (Dziedzina nauk medycznych i nauk o zdrowiu).

© The Authors 2022:

This article is published with open access at Licensee Open Journal Systems of Nicolaus Copernicus University in Torun, Poland

Open Access. This article is distributed under the terms of the Creative Commons Attribution Noncommercial License which permits any noncommercial use, distribution, and reproduction in any medium, provided the original author(s) and source are credited. This is an open access article licensed under the terms of the Creative Commons Attribution Non commercial license Share alike. (<http://creativecommons.org/licenses/by-nc-sa/4.0/>) which permits unrestricted, non commercial use, distribution and reproduction in any medium, provided the work is properly cited.

The authors declare that there is no conflict of interests regarding the publication of this paper.

Received: 15.12.2021. Revised: 25.12.2021. Accepted: 14.01.2022.

Morphofunctional changes in the rat's liver of different ages after L-methionine administration

Roman Yanko ^(B,C,E,F), Elena Chaka ^(B,F,G), Mikhail Levashov ^(A,D)

**Bogomoletz Institute of Physiology,
National Academy of Sciences of Ukraine, Department of Clinical Physiology of
Connective Tissue, Kiev, Ukraine**

Authors' contribution / Wkład autorów:

- A. Study design, planning / zaplanowanie badań
- B. Data collection entry / zebranie danych
- C. Data analysis, statistics / dane analiza i statystyki
- D. Data interpretation / interpretacja danych
- E. Preparation of manuscript / przygotowanie artykułu
- F. Literature analysis, search / wyszukiwanie i analiza literatury
- G. Funds collection / zebranie funduszy

Corresponding Author:

Yanko Roman, Bogomoletz Institute of Physiology, Bogomoletz str., 4, Kiev, Ukraine, 01024 (e-mail: biolag@ukr.net)

Roman Yanko - <https://orcid.org/0000-0002-0397-7517>

Elena Chaka - <https://orcid.org/0000-0001-7425-2751>

Mikhail Levashov - <https://orcid.org/0000-0003-1354-2047>

Abstract

Background: Literature data on the effect of methionine on functional activity and, especially, on morphological changes in the liver parenchyma in animals of different ages are sporadic, and research results are often ambiguous.

Aim: The purpose of this work was to study and compare the morphofunctional changes in the liver of rats of different ages on prolonged administration of L-methionine.

Material and Methods: The experiment was performed on 48 male Wistar rats of 3 and 15 months of age. Animals of the experimental group received L-methionine at a dose of 250 mg/kg body weight in addition to the standard diet, daily for 21 days. Histological preparations were prepared from liver tissue by a standard technique. Morphometry was performed on digital images using the computer program «Image J». Succinate dehydrogenase activity and protein concentration were determined in the suspension of hepatocyte mitochondria.

Results: It was revealed that 21-day administration of L-methionine to rats led to hypertrophy of the hepatocyte nucleus, an increase in the nuclear-cytoplasmic ratio, the number of binuclear hepatocytes, and the nucleolus in the cell nucleus. The relative area of the sinusoids network increased by 50% in 3-month-old animals. This indicated a better blood filling of the liver parenchyma. The increase in succinate dehydrogenase activity and protein concentration was revealed in the suspension of hepatocyte mitochondria of the experimental rats. This indicated an increase in the mitochondria energy potential and protein-synthetic activity.

Conclusions: The administration of prophylactic doses of methionine to healthy rats leads to the appearance of pronounced morphological and functional signs of increased activity of hepatocytes. The severity of this effect has a distinct age-dependent character. In young rats, it is more pronounced than in mature rats. The results of the study are important for practical medicine when using methionine for therapeutic and prophylactic purposes.

Key words: methionine; liver.

Introduction

The essential amino acid methionine is one of the hepatoprotectors with a wide range of action on the liver and metabolic processes in other organs and tissues. It plays a central role in the amino acids metabolism, since it serves as a source of formation of other amino acids and peptides that take part in many biochemical reactions [1, 2].

It has been proven that methionine does not allow the accumulation of fat in the liver, cleanses it of toxins and harmful substances. In addition, methionine helps the liver to metabolize fats in the body. Methionine and various drugs based on it are widely used in practical medicine in the treatment of patients with liver diseases such as: hepatitis, hepatosis,

cirrhosis, intoxication, dystrophic changes. L-methionine activates the processes of regeneration of damaged liver tissue [3, 4].

Methionine acquires its full therapeutic potential after it is converted in the body to S-adenosylmethionine (SAME). The liver is the organ in which about 50% of the total methionine in the body is metabolized. It is in the liver methionine is converted into SAME, which is necessary for the methylation of a large number of substrates. In the presence of pathology in the liver, the transformation of methionine into SAME decreases, which has a negative effect not only on it, but also on other organs. Deficiency of methionine in the body, and, as a consequence, a violation of the formation of SAME, can be observed with malnutrition, alcohol abuse, medication, intoxication, etc. [5, 6]. It has been shown that in mice prolonged nutritional deficiency of methionine led to a decrease in SAME levels and the development of steatohepatitis, liver obesity, mitochondrial dysfunction, hepatocellular damage, inflammation, fibrosis, and the development of hepatocellular carcinoma [7, 8]. Therefore, maintaining the homeostasis of methionine is important for the prevention of liver disease [5]. At the same time, the use of high doses of methionine, on the contrary, increases the risk of liver damage due to its accumulation in hepatocytes and the development of homocystenemia.

Literature data on the results of experimental studies of the effect of methionine on the morphofunctional state of the liver parenchyma are often ambiguous [9, 10]. This may be due to differences in the dosage and duration of methionine administration, as well as to the use of animals of different ages in experiments. It is known that the liver, like other organs, reacts differently to the same influences in the process of ontogenesis. Age-related susceptibility of this organ to the action of methionine is no exception. At the same time, until now there is no unanimous opinion about the peculiarities of the effect of this amino acid on histomorphological and biochemical changes in the liver in animals of different ages. Therefore, in order to compare and analyze the age-related reactivity of the liver after the administration of methionine we took rats of different age groups into the experiment.

Purpose of work

The aim of this work was to study and compare morphofunctional changes in the rats liver of different ages after methionine administration.

Material and methods

The study was carried out on 48 male Wistar rats at the age of 3 and 15 months. The rats were divided into 4 groups (12 animals each): I and III – control 3 and 15 month old animals, II and IV – experimental young and adult rats, respectively. The rats of the control

group received 240-250 mg / kg of methionine, which was included in the standard diet. The experimental rats received an additional oral dose of L-methionine at the rate of 250 mg / kg body weight. Thus, the total amount of methionine that the experimental animals received was \approx 500 mg / kg of body weight. Such a dose of methionine can be considered as a prophylactic one, since it does not lead to a significant increase in its content in the body and the occurrence of homocystenemia, but is sufficient to correct a possible deficiency of an amino acid in the body to the values of the physiological norm. Animals of all groups were kept in standardized conditions with a standard diet. The experiment lasted 21 days.

The rats were removed from the experiment by decapitation under ether narcosis. All research protocols corresponded to the provisions of the Council of Europe Convention on Bioethics (1997), the Helsinki Declaration of the World Medical Association (1996), the European Convention for the Protection of Vertebrates, which are used for experimental and other scientific purposes (Strasbourg, 1985), the general ethical principles of animal experiments, adopted by the First National Congress of Ukraine on Bioethics (2001), as well as a committee with biomedical ethics of the Bogomoletz Institute of Physiology, National Academy of Sciences of Ukraine.

We used histological, morphometric, biochemical and statistical research methods. Histological preparations of liver tissue were prepared according to a standard procedure: fixed in Buen's liquid, dehydrated in spirits of increasing concentration and dioxane and poured into paraffin. The obtained preparations were used for morphological and morphometric studies. The sections were stained with Bemer's hematoxylin and eosin, and for the detection of connective tissue elements – by the Van Gyzon method [8]. Microscopic preparations were photographed on a microscope "Nikon Eclipse E100" (Japan) using a digital camera. The morphometry of the preparations digital images was performed using the computer program "Image J".

On histological sections of the liver, the average diameter, the cross-sectional area of hepatocytes, their nucleus and cytoplasm were measured, the nuclear-cytoplasmic ratio was determined, the number of mono- and binuclear cells was counted and the density of hepatocytes per unit area was determined, the number of nucleolus was counted, measured the distance between adjacent nucleus of hepatocytes. The number of hepatocytes was counted in 10 fields of view of the microscope (at 800 times magnification), the number of nucleolus was counted per 100 nucleus of hepatocytes, the diameter and area were measured for each cell with the determination of the average value relative to 100 cells. Using the method of superimposing point morphometric grids, the relative area of the sinusoidal grid and the

relative area of the liver parenchyma were determined. The Vizotto coefficient was calculated – the ratio of the relative area of the sinusoidal grid to the relative area of the liver parenchyma. On sections of the liver the number was counted and the density of placement of connective tissue cells was determined. The ratio of the number of stromal cells to the number of hepatocytes was determined [12, 13].

Mitochondria were isolated from the liver parenchyma by differential centrifugation. In the suspension of hepatocytes mitochondria the activity of succinate dehydrogenase (Stinger and Kearney method) and protein concentration (Lowry method) were determined.

Data analysis

Statistical processing was carried out using variation statistics methods using the computer program Statistica 6.0. The normal distribution of digital arrays was verified using the Pearson criterion. When the distribution was normal, the Student's t-test was used to estimate the difference in the reliability of the difference between the control and experimental groups. Differences were considered significant at $p < 0.05$.

Results

No significant structural differences were found in the liver of control rats of different ages. However, in mature rats, a distinct tendency towards a decrease in the relative area of the parenchyma and the number of nucleous in the hepatocyte nucleus was noted. At the same time, such indicators as the number of binuclear hepatocytes, the ratio of binuclear hepatocytes to mononuclear, as well as the relative area of sinusoids and the Vizotto coefficient were slightly higher in them than in young rats.

The liver parenchyma of rats of both groups, after the end of methionine administration, retained its structure. Hepatocytes were predominantly of medium size with well-defined contours. The nucleus had a rounded shape and was located in the center of the cell. The structural boundaries of the lobules were poorly discernible, which is characteristic of this animal species. Interlobular connective tissue was poorly expressed (Figure).

In the liver of rats treated with L-methionine a slight tendency towards a decrease in the diameter, cross-sectional area of hepatocytes and their cytoplasm was observed. The area of the nucleus of hepatocytes in animals, on the contrary, increased by 7% (at 3 months) and 18% (at 15 months; $p < 0.05$) compared with the control. This led to a significant increase in the nuclear-cytoplasmic ratio by 16% in young animals and by 33% in adult rats. The state of the nucleolus apparatus is an important informational indicator of the functional activity of hepatocytes. In 3- and 15-month-old animals treated with L-methionine, there was a significant increase in the number of nucleolus by 17% and 28%, respectively (Table 1).

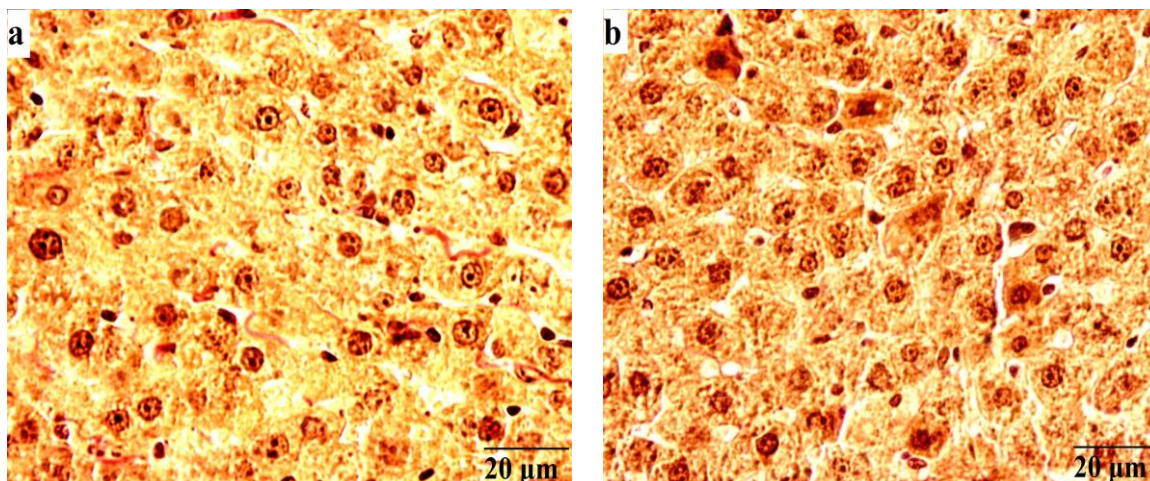


Figure: Microphotograph of the liver in control (a) and experimental (b) rats of 3 months of age. Van Gieson color. x800

Table 1. Morphometric parameters of the liver parenchyma (M ± m; n = 12)

Index	3 month old rats		15 month old rats	
	Control	Experience	Control	Experience
Relative parenchyma area,%	93.8 ± 0.6	90.7 ± 0.8	91.4±1.1	91.0±0.7
Average diameter of the hepatocyte, µm	16.6 ± 0.3	15.2 ± 0.4	15.9±0.6	15.5±0.3
Area, µm ²				
hepatocyte	258.2 ± 12.4	241.2 ± 11.0	260.9±17.9	240.7±8.8
nucleus	32.9 ± 0.9	35.1 ± 1.0	33.2±1.7	39.1±1.6*
cytoplasm	225.3 ± 11.2	206.1 ± 9.8	227.7±15.3	201.6±10.7
Nuclear cytoplasm. ratio	0.146 ± 0.005	0.170 ± 0.004*	0.146±0.005	0.194±0.006*
Number of hepatocytes (for 23000 µm ²), pcs				
general	66.3 ± 2.1	70.5 ± 2.6	66.5±2.8	63.0±2.3
mononuclear	64.6 ± 1.9	67.2 ± 2.5	64.0±2.9	60.1±2.3
binuclear	1.7 ± 0.3	3.3 ± 0.2*	2.5±0.1	2.9±0.1*
The ratio of binuclear / mononuclear hepatocytes	0.026 ± 0.004	0.049 ± 0.003*	0.039±0.004	0.048±0.005*
Density of hepatocytes, pcs./1000 µm ²	2.88 ± 0.09	3.07 ± 0.11	2.89±0.13	2.74±0.22
Number of nucleolus in the hepatocyte nucleus, pcs	1.66 ± 0.06	1.95 ± 0.05*	1.56±0.04	1.99±0.08*
Distance between nucleus of adjacent hepatocytes, µm	9.0 ± 0.1	7.9 ± 0.1*	9.1±0.2	8.4±0.2

Here and in table 2 and 3 * - p < 0.05 – significant differences in compared with the control.

In the liver of experimental animals, the total number and the number of mononuclear hepatocytes remained at the level of control values. At the same time, the number of binuclear hepatocytes significantly increased by 94% (in 3 months old rats) and 16% (in 15 months old

rats) compared to the control. This led to a significant increase in the ratio of binuclear / mononuclear hepatocytes by 88% and 23% in the liver of young and adult rats, respectively (Table 1).

The distance between the nucleus of adjacent hepatocytes in experimental rats was 12% lower (at 3 months; $p < 0.05$) and 9% (at 15 months) compared to the control (Table 1). In our case, this is most likely due to the smaller area of the cell cytoplasm.

Normally, a small amount of connective tissue (CT) is located in the liver tissue of rats in comparison with other organs. The stroma plays a supporting role for parenchymal cells and lines the walls of blood vessels, lymph vessels and bile ducts. An important feature of CT is its ability to grow and replace defects, "voids", that are formed in the parenchyma during massive death of hepatocytes. The liver stroma includes connective tissue cells: fibroblasts, Kupffer cells, Ito cells, phagocytes and Pit cells, which are located mainly in sinusoids. CT also contains thinner branched collagen fibers that form a supporting network-like structure between hepatocytes [14]. When the liver preparations were stained with 2% acid picrofuchsin in combination with Weigert's iron hematoxylin, no significant differences were found between control and experimental animals in the amount and intensity of staining of CT elements (collagen and elastin fibers) in the liver. Most of the CT elements in the liver are localized near the central vein and portal triads (Figure).

In the liver of 3-month-old rats, after the administration of L-methionine, a significant increase (by 50%) in the relative area of the sinusoidal grid was revealed in comparison with the control. This, in turn, led to an increase in the Vizotto coefficient by 52% ($p < 0.05$), which may indicate a better blood filling of the liver parenchyma and the activation of the trophic function of CT in it. As you know, sinusoids form a network of interconnected vessels. The walls of sinusoids include cells of the reticuloendothelial system – endothelial and stellate reticuloendothelial cells (Kupffer cells). Between the wall of the sinusoid, which has numerous holes, and the surface of hepatocytes, there is the Disse space, through which there is a continuous exchange of nutrients and compounds that are synthesized by hepatocytes [14]. In the liver of young animals the total number and density of CT cells were by 11% less than in the control values. The ratio of the number of CT cells to the number of hepatocytes in these rats was significantly lower by 15% than in the control. The studied parameters of CT in the liver of 15-month-old experimental rats did not change (Table 2).

In the suspension of hepatocytes mitochondria of young rats, after the administration of L-methionine, a significant increase in the activity of succinate dehydrogenase by 23% compared with the control was revealed (Table 3). In adult animals this indicator remained at

the control level. Succinate hydrogenase is directly involved in oxygen metabolism and ATP synthesis, and an increase in its activity indicates an increase in the energy potential of cell mitochondria [15].

Table 2. Morphometric parameters of the connective tissue of the liver ($M \pm m$; $n = 12$)

Index	3 month old rats		15 month old rats	
	Control	Experience	Control	Experience
Relative area of sinusoids, %	6.2 ± 0.6	$9.3 \pm 0.8^*$	8.6 ± 1.2	9.0 ± 0.7
Vizotto coefficient	0.066 ± 0.008	$0.10 \pm 0.01^*$	0.094 ± 0.010	0.099 ± 0.008
Number of connective tissue cells (per 23000 μm^2), pcs	22.2 ± 1.5	19.7 ± 0.9	21.3 ± 2.4	20.0 ± 1.2
Connective tissue cell density, pcs./1000 μm^2	0.97 ± 0.06	0.86 ± 0.04	0.93 ± 0.11	0.87 ± 0.06
Relationships. number of connective tissue cells / number of hepatocytes	0.33 ± 0.01	$0.28 \pm 0.01^*$	0.33 ± 0.05	0.32 ± 0.01

Table 3. Succinate dehydrogenase activity and protein concentration in hepatocyte mitochondrial suspension ($M \pm m$; $n = 12$)

Index	3 month old rats		15 month old rats	
	Control	Experience	Control	Experience
Succinate dehydrogenase activity, nM/min /g tissue	97.2 ± 5.3	$119.6 \pm 6.4^*$	95.0 ± 6.3	95.5 ± 6.5
Protein concentration, mg/g	3.9 ± 0.1	$4.5 \pm 0.1^*$	3.7 ± 0.44	$6.4 \pm 0.5^*$

Mitochondria have their own genetic material and systems for the production of their own RNA and proteins [16]. We found that in the suspension of hepatocytes mitochondria of 3 and 15 month old rats, treated with L-methionine, the protein concentration significantly increased by 15% and 73%, respectively, compared with the control (Table 3).

Discussion

Most of the existing literature data are devoted to clinical and experimental studies of the effect of methionine on the state of the liver in a particular pathology and the effectiveness of its use for the correction of existing disorders. At the same time, the question of the use of methionine at the preclinical stages of the development of pathology or in healthy individuals, as a means of pre-adaptation and increasing the body's resistance to the effects of various unfavorable environmental factors, has been little studied. Until now, the question of how

pronounced the effect of using methionine is to increase the functional activity of a healthy liver in patients of different age groups remains open.

The results of our studies indicate that in the liver of healthy young and adult rats that received L-methionine for 21 days (at a dose of 250 mg / kg), there is a tendency to a decrease in the size of hepatocytes and their cytoplasm. But, at the same time, the area of the hepatocytes nucleus, on the contrary, slightly increases, which leads to an increase in the nuclear-cytoplasmic ratio. Nucleus hypertrophy primarily indicates an increase in the functional activity of the cell [17]. To a lesser extent an increase in this indicator may indicate the preparation of the cell for mitosis and an increase in the ploidy of hepatocytes, since the number of tetraploid and octaploid cells increases during the regeneration process [18].

The results of our research showed that the number of binuclear hepatocytes significantly increased in the experimental rats. Most authors believe that an increase in the number of binuclear hepatocytes indicates an increase in the intensity of regeneration of the liver parenchyma at the intracellular level due to polyploidization [19, 20]. The general principle of regeneration is the restoration of the entire total tissue genome. This is achieved either by dividing cells or by increasing genomes in a cell that has not divided.

An increase in the number of nucleolus was observed in the hepatocyte nucleus of animals treated with L-methionine, which may also indicate the activation of the processes of physiological regeneration of hepatocytes at the intracellular level. Since the main functions of the nucleolus include the synthesis of rRNA, with which ribosome subunits are formed, it is believed that hyperplasia of the nucleolus indicates an increase in the protein-synthetic activity of hepatocytes [21].

An increase in the relative area of the sinusoidal grid and the Vizotto coefficient in 3-month-old rats treated with L-methionine suggests an improvement in the blood volume of the liver parenchyma and activation of the trophic function of the connective tissue in it.

An increase in the activity of succinate dehydrogenase and protein concentration in the suspension of hepatocyte mitochondria in experimental rats also indicates an increase in the energy potential of mitochondria and an increase in their protein-synthetic activity [15].

It was revealed that the positive effect on the liver from the additional administration of methionine is more pronounced in young rats than in adults. As you know, with age the body's response to drugs can change. In old and old age, the effect of the use of the drug can both increase and decrease in comparison with young age. In relation to the results of our studies, it can be assumed that the absorption of methionine from the intestine slows down with age. It is also necessary to take into account the fact that the ability to activate

methionine-dependent enzymes in an aging organism may also decrease, and the number of receptors may decrease. Obviously, all this requires an age-dependent correction of the standard doses of the drug, as well as further research in this direction.

The positive effect of the influence of methionine, or its derivatives has been identified by other authors. A number of researchers have found that the administration of methionine (at a dose of 35 mg / kg) for 9 days prevents functional and morphological changes in the liver 5 days after the reproduction of the model of acute toxic hepatitis. This was expressed in the improvement of the integral indicators of animals, the approximation of the indicators of the activity of AST and ALT to the control values and a decrease in the phenomena of cytolysis of the liver tissue [10]. It has been proven that the administration of methionine counteracts changes in enzyme activity and morphological abnormalities in the liver when it is damaged by sodium fluoride [22]. In the study of the animals liver, under conditions of correction of steatosis with hepatoprotector ademetionine, it was found that changes in organ structures are less pronounced than in animals that received a hypercaloric diet without subsequent administration of the drug. The use of this methionine derivative prevents damage to the structural components of the liver lobules, has a positive effect on the morphofunctional state of the organ [23]. Other authors found that subchronic administration of methionine (0.8 mmol / kg, for 21 days) in rat liver caused periportal mononuclear infiltration and rare necrosis of hepatocytes, intracellular edema [9]. It was revealed that a methionine deficiency in food leads to severe steohepatitis, which is accompanied by liver fibrosis [24]. It has been shown that methionine increases plasma cholesterol levels in animals and enhances its synthesis in the liver. Rats that received 3.5 g / kg or more methionine had higher plasma cholesterol concentrations. Hepatocytes incubated in media supplemented with 100 or 200 $\mu\text{mol} / \text{L}$ methionine also had a high level of cholesterol synthesis [25].

Conclusion

Thus, additional administration of prophylactic doses of methionine to healthy rats leads to the appearance of morphological and functional signs of increased activity of hepatocytes. The severity of this effect has a distinct age-dependent character. In young rats, it is more pronounced than in adults. The age dependence of the positive effect of methionine on the activity of hepatocytes should be taken into account not only when correcting clinically pronounced abnormalities in liver function, but also when using methionine at preclinical stages of pathology development and in healthy individuals, as a means of preadaptation and increasing liver resistance to the possible effects of various adverse environmental factors. The results obtained are not only of theoretical importance, but also of interest for practical

medicine in solving the problems of complex treatment and prevention of chronic liver diseases associated with insufficient liver function.

References:

1. Li Z, Wang F, Liang B, et al. Methionine metabolism in chronic liver diseases: an update on molecular mechanism and therapeutic implication. *Sig Transduct Target Ther.* 2020; 5:280. doi: 10.1038/s41392-020-00349-7.
2. Geltink R, Pearce E. The importance of methionine metabolism. *Life.* 2019; 8:e47221. doi: 10.7554/eLife.47221.
3. Best CH, Ridout JH. The lipotropic action of methionine. *J Physiol.* 1940; 97(4):489-94.
4. Chandler TL, White HM. Choline and methionine differentially alter methyl carbon metabolism in bovine neonatal hepatocytes. *PLoS One.* 2017; 12(2):e0171080.
5. Mato JM, Martínez-Chantar ML, Lu SC. S-adenosylmethionine metabolism and liver disease. *Ann Hepatol.* 2013; 12(2):183-89.
6. Lieber CS. S-adenosyl-L-methionine: its role in the treatment of liver disorders. *Am. J. Clin. Nutr.* 2002; 76(5):1183S-1187S.
7. Caballero F, Fernández A, Matías N, et al. Specific contribution of methionine and choline in nutritional nonalcoholic steatohepatitis: impact on mitochondrial S-adenosyl-L-methionine and glutathione. *J Biol Chem.* 2010; 285(24):18528-36. doi: 10.1074/jbc.M109.099333.
8. Latimer MN, Freij KW, Cleveland BM, et al. Physiological and molecular mechanisms of methionine restriction. *Front Endocrinol (Lausanne).* 2018; 9:217. doi:10.3389/fendo.2018.00217.
9. Stojanović M, Todorović D, Šćepanović L, et al. Subchronic methionine load induces oxidative stress and provokes biochemical and histological changes in the rat liver tissue. *Mol Cell Biochem.* 2018; 448(1-2):43-50. doi: 10.1007/s11010-018-3311-2.
10. Gabuniya L, Bakuridze K, Gogolauri M, et al. Vliyanie karvediola, metionina i ikh kombinatsii na nekotoryye funktsional'nyye parametry pecheni i morfologicheskiye izmeneniya v usloviyakh toksicheskogo gepatita. [Influence of carvediol, methionine and their combination on some functional parameters of the liver and morphological changes in the conditions of toxic hepatitis]. *Allergologiya i immunologiya.* 2010; 11(2):106-8. (in Russian).

11. Danilov RK. Rukovodstvo po gistologii. Tom II. [Guide to histology. Volume II.]. St. Petersburg: SpecLith; 2011. (in Russian).
12. Yanko R, Berezovskii V, Chaka E, et al. Morphofunctional characteristic of hepatocytes after exposure to intermittent normobaric hypoxia in normotensive and hypertensive rats. *Regulatory Mechanisms in Biosystems*. 2017; 8(2):265-70. doi: 10.15421/021741.
13. Rudzki Z, Szczudrawa J, Stachura J. Morphometry of normal, regenerating and cancerous hepatocytes. *Folia Histochem Cytobiol*. 1999; 27(3):141-8.
14. Rauterberg J, Voss B, Pott G, et al. Connective tissue components of the normal and fibrotic liver. *Klin Wochenschr*. 1981; 59:767-79. doi:10.1007/BF01724682.
15. Rutter J, Winge DR, Schiffman JD. Succinate dehydrogenase – Assembly, regulation and role in human disease. *Mitochondrion*. 2010; 10(4):393-401. doi: 10.1016/j.mito.2010.03.001.
16. Allen JF. Why chloroplasts and mitochondria retain their own genomes and genetic systems: Colocation for redox regulation of gene expression. *PNAS*. 2015; 112(33):10231-238. doi: 10.1073/pnas.1500012112.
17. Rosioru C, Talu S, Talu M, et al. Morphometric assessments for the healthy rat hepatocytes. *Annals of the Romanian Society for Cell Biology*. 2012; XVII(1):74-9.
18. Duncan AW, Taylor MH, Hickey RD, et al. The ploidy conveyor of mature hepatocytes as a source of genetic variation. *Nature*. 2010;467(7316):707-10. doi: 10.1038/nature09414.
19. Sarkisov DS, Vtyurin BV. Elektronnaya mikroskopiya destruktivnykh i regenerativnykh vnutrikletochnykh protsessov. [Electron microscopy of destructive and regenerative intracellular processes]. Moscow: Medicine; 1967. (In Russian).
20. Romanova LP, Malyshev II. Rol' dvuyadernnykh gepatotsitov v regeneratsii pecheni posle mekhanicheskoy travmy v rannem ontogeneze u krysa [The role of binuclear hepatocytes in liver regeneration after mechanical trauma in early ontogenesis in rats]. *Vestnik Chuvashskogo universiteta*. 2011; 3:398-402. (in Russian).
21. Boisvert F, van Koningsbruggen S, Navascués J, et al. The multifunctional nucleolus. *Molecular Cell Biology*. 2007; 8(7):574-85. doi:10.1038/nrm2184.
22. Stawiarska-Pięta B, Bielec B, Birkner K, et al. The influence of vitamin E and methionine on the activity of enzymes and the morphological picture of liver of rats intoxicated with sodium fluoride. *Food Chem Toxicol*. 2012; 50(3-4):972-8. doi: 10.1016/j.fct.2012.01.014.

23. Pivtorak KV. Submikroskopichnyy stan pechinky pry korektsiyi steatozu hepatoprotektorom aminokyslotnoho pokhodzhennya [Submicroscopic condition of the liver in the correction of steatosis with hepatoprotector of amino acid origin]. Visnyk problem biolohiyi ta medytsyny. 2015; 3(2):310-13. (in Ukraine).

24. Itagaki H, Shimizu K, Morikawa S, et al. Morphological and functional characterization of non-alcoholic fatty liver disease induced by a methionine-choline-deficient diet in C57BL/6 mice. *Int J Clin Exp Pathol.* 2013; 6(12):2683-96.

25. Hirche F, Schröder A, Knoth B, et al. Effect of dietary methionine on plasma and liver cholesterol concentrations in rats and expression of hepatic genes involved in cholesterol metabolism. *Br J Nutr.* 2006; 95(5):879-88.