

Ivasivka K. P., Paltov E. V., Masna Z. Z., Chelpanova I. V. Dynamics of changes in the ultrastructural characteristics of the mucosa and cartilage of the larynx of rats at the end of 35 and 42 days of experimental opioid exposure and after 56 days with opioid withdrawal. *Journal of Education, Health and Sport*. 2021;11(09):841-851. eISSN 2391-8306. DOI <http://dx.doi.org/10.12775/JEHS.2021.11.09.099> <https://apcz.umk.pl/JEHS/article/view/JEHS.2021.11.09.099> <https://zenodo.org/record/5605688>

The journal has had 5 points in Ministry of Science and Higher Education parametric evaluation, § 8.2) and § 12.1.2) 22.02.2019.

© The Authors 2021;

This article is published with open access at Licensee Open Journal Systems of Nicolaus Copernicus University in Torun, Poland

Open Access. This article is distributed under the terms of the Creative Commons Attribution Noncommercial License which permits any noncommercial use, distribution, and reproduction in any medium, provided the original author(s) and source are credited. This is an open access article licensed under the terms of the Creative Commons Attribution Non commercial license Share alike. (<http://creativecommons.org/licenses/by-nc-sa/4.0/>) which permits unrestricted, non commercial use, distribution and reproduction in any medium, provided the work is properly cited.

The authors declare that there is no conflict of interests regarding the publication of this paper.

Received: 25.08.2021. Revised: 12.09.2021. Accepted: 30.09.2021.

UDC: 611: 321.018.3 / 73: 615.212.7.03

Dynamics of changes in the ultrastructural characteristics of the mucosa and cartilage of the larynx of rats at the end of 35 and 42 days of experimental opioid exposure and after 56 days with opioid withdrawal

K. P. Ivasivka, E. V. Paltov, Z. Z. Masna, I. V. Chelpanova

Danylo Halytsky Lviv National Medical University

Ivasivka K.P. Danylo Halytsky Lviv National Medical University, Department of Normal Anatomy, Lviv, Ukraine <https://orcid.org/0000-0003-4372-225X>

Paltov E.V. Danylo Halytsky Lviv National Medical University, Department of Normal Anatomy, Lviv, Ukraine <https://orcid.org/0000-0002-2622-4753>

Masna Z.Z. Danylo Halytsky Lviv National Medical University, Department of Operative Surgery with Topographic Anatomy, Lviv, Ukraine <https://orcid.org/0000-0003-2057-7061>

Chelpanova I.V. Danylo Halytsky Lviv National Medical University, Department of Histology, Cytology and Embryology, Lviv, Ukraine <https://orcid.org/0000-0001-5215-814X>

Abstract

In our work, we studied the ultrastructural organization of rat laryngeal mucosa and cartilage at the end of 35 and 42 days of experimental opioid exposure and at the end of 56 days with opioid withdrawal. As a result of our study at the end of the 35th day at the ultrastructural level revealed hypersecretion of goblet cells, mucus contained impurities of lymphocytes, single neutrophils and erythrocytes. In the enlarged lumens of the hemocapillaries of the lamina propria of the mucous membrane and submucosal base of different parts of the larynx, the adhesion of erythrocytes was noted. At the end of 42 days in

rats, the changes were characterized by moderate damage to cytoplasmic organelles in epitheliocytes. Alternative changes developed in the chondrocytes of elastic and hyaline cartilages. Marked by an increase in the number of active fibroblasts, next to which were numerous fibrils of collagen fibers. The main substance of connective tissue, near dilated vessels, was impregnated with transudate, which was accompanied by the development of perivascular edema. Glycogen grains and vacuoles filled with neutral fats were visualized in the cytoplasm of chondrocytes. At the end of 56 days in rats with two-week withdrawal of the opioid analgesic, we found the development of alternative processes in the epitheliocytes of different parts of the larynx, as well as in chondrocytes, especially in elastic cartilage. Dyscirculatory processes in vessels of own plate of a mucous membrane and a submucous basis of various departments of a larynx were registered. Necrotic changes developed in the columnar epitheliocytes of the submucosal mucosa. Mitochondria swelled, their matrix brightened, cristae collapsed.

The results of the article correspond to the research plan of Danylo Halytskyi Lviv National Medical University and are part of the research topic of the Department of Normal Anatomy "Morphofunctional features of organs in pre - and postnatal periods of ontogenesis, under the influence of opioids, food supplements, reconstructive surgery and obesity" (0120U002129) during 2020 - 2024.

Key words: larynx; rats; opioid; ultrastructural changes; nalbuphin.

Introduction. Opioids are widely used in modern medicine, in particular, in surgery for premedication, in oncology, obstetrics and gynecology - as analgesics, gastroenterology, otorhinolaryngology [1]. Such a wide range the use of narcotic analgesics in medical practice is due pronounced analgesic effect [2, 3]. Nalbuphine is a central, semi-synthetic narcotic analgesic origin, phenanthrene derivative, mixed action (agonist-antagonist) [4, 5], which is widely used in clinical practice.

Aim. The aim of our study was to examine the ultrastructural organization of the mucosa and cartilage of the larynx of rats at the end of 35 and 42 days of experimental opioid exposure and at the end of 56 days with opioid withdrawal.

Materials and methods of research. The material of the study were sexually mature, outbred rats - males in the amount of 48 animals, weighing 120 g, aged 4.5 months. Animals were injected with nalbuphine intramuscularly once daily for 56 days (10-11 am) for 56 days. The dose of nalbuphine was 30 mg / kg during the fifth, 35 mg / kg during the sixth week,

experimental opioid exposure. Thus created the conditions for chronic opioid exposure [6]. The animals were divided into 4 groups. 1st control group, which for 56 days received injections of saline at home in one period of time (10 - 11 o'clock in the morning); Group 2 animals received nalbuphine for 35 days in one time interval (10 - 11 o'clock in the morning) followed by collection of study material (end of the fifth week of experimental opioid exposure); 3rd group of animals received nalbuphine for 42 days in one period of time (10 - 11 hours in the morning) followed by collection of study material (end of the sixth week of experimental opioid exposure), 4-a-within 2 weeks, end of 56 days, was on the withdrawal of the opioid analgesic followed by sampling (end of the eighth week of experimental opioid exposure) used for experimental and other scientific purposes ” [Strasbourg, 1985], “General ethical principles of animal experiments”, adopted by the First National Congress of Bioethics [Kyiv, 2001]. The Commission on Bioethics of Lviv National Medical University named after Danylo Halytsky established that the conducted research meets ethical requirements according to the order of the Ministry of Health of Ukraine № 231 of 01.11.2000 (Minutes № 10 of 26.12.2011).

Before collecting necropsy material, the animal was removed from the experiment with diethyl ether. The mucosa and cartilage of the larynx of rats were used as material for ultrastructural examination. Ultrastructural preparations were prepared according to the generally accepted method [7, 8, 9].

Research results

As a result of the collection of experimental material after 35 days in brothers exposed to an opioid analgesic at a dose of 30 mg / kg at the ultrastructural level, it was found that due to hypersecretion of goblet cells on the surface of the mucosa accumulated excessive mucus with impurities of erythrocytes and lymphocytes. Volumetric granules containing mucinogens were localized in the apical part of goblet cells (Fig. 1), quite often their content was inhomogeneous.

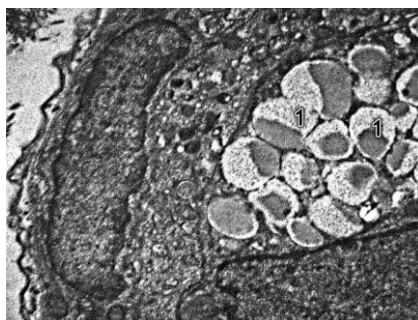


Fig. 1. Goblet cell after 35 days of opioid exposure. Photomicrograph. Coll. x4000.

1 - secretory granules with inhomogeneous electron-dense content in the apical part of goblet cells.

In the enlarged lumens of the hemocapillaries of the lamina propria of the mucous membrane and submucosal base of different parts of the larynx, the adhesion of erythrocytes was noted (Fig. 2).

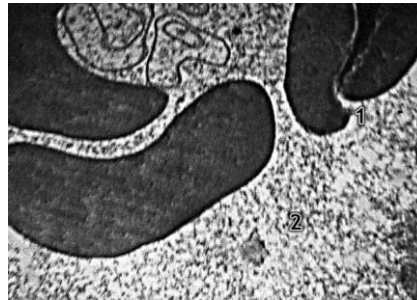

Fig. 2. Hemocapillary after 35 days of opioid exposure. Photomicrograph. Coll. x4000.

1 - bonding of deformed erythrocytes; 2 - increased hemocapillary lumen.

Own plate of the mucous membrane and submucosal base contained polymorphonuclear infiltrates of lymphocytes, neutrophils, macrophages. In some places, inconsistent enlightenment of the main substance of the connective tissue was observed, especially near the hyperemic vessels. The number of fibroblasts, the newly formed fibrils of collagen fibers near which were located chaotically, also increased (Fig. 2). Individual fibrils of collagen fibers were fragmented (Fig. 3). There were inhomogeneously thickened fibrils of collagen fibers. Medium electron density substances accumulated in individual bundles of collagen fibers.

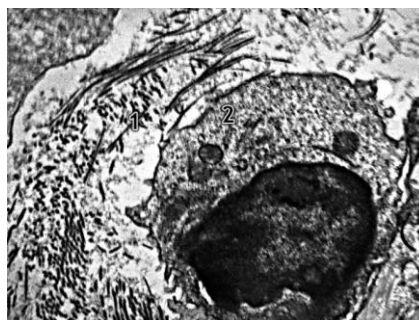


Fig. 3. Fibroblast after 35 days of opioid exposure. Photomicrograph. Coll. x6000.

1 - inhomogeneous arrangement of fibrils of collagen fibers; 2 - fibroblast.

Enlightenment, edema, and vacuolation of the axoplasm were noted in myelin nerve fibers (Fig. 4, 5, 6), and deformation of myelin sheaths was noted in some fibers.

In some chondrocytes of hyaline cartilage necrotic changes developed, accompanied by a sharp reduction of the nucleus, which was filled with distinctly osmophilic condensed chromatin (karyopyknosis). The hyaloplasm of such chondrocytes swelled, lysosomes, small vacuoles with enlightened contents accumulated in it.

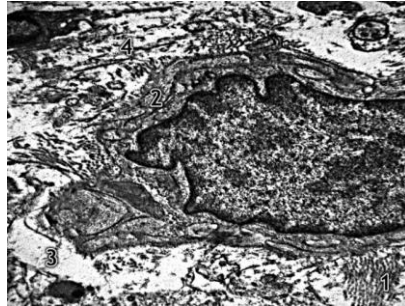

Fig. 4. Fibroblast after 35 days of opioid exposure. Photomicrograph. Coll. x6000.

- 1 - inhomogeneous arrangement of fibrils of collagen fibers;
- 2 - fibroblast;
- 3 - enlightenment of the main substance of connective tissue;
- 4 - fragmentation of fibrils of collagen fibers.

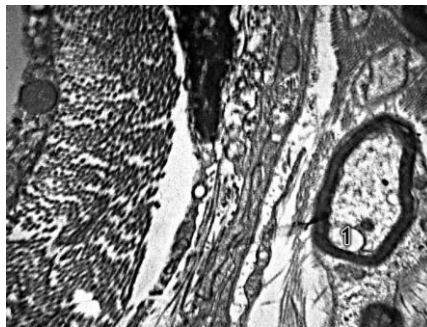


Fig. 5. Myelin nerve fiber after 35 days of opioid exposure. Photomicrograph. Coll. x6000.

- 1 - vacuolation of the axoplasm of myelin nerve fibers.

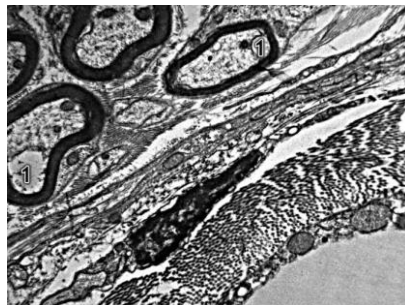


Fig. 6. Myelin nerve fiber after 35 days of opioid exposure. Photomicrograph. Coll. x6000.

- 1 - increase in vacuolation of axoplasm of myelin nerve fibers.

As a result of sampling of experimental material after 42 days in patients exposed to an opioid analgesic at a dose of 35 mg / kg, pronounced ultrastructural changes were detected, characterized by moderate damage to cytoplasmic organelles in epitheliocytes of different parts of the larynx. Alternative changes developed in the chondrocytes of elastic and hyaline cartilages. In addition, there was an increase in the number of active fibroblasts, next to which were numerous fibrils of collagen fibers (Fig. 7, 8).

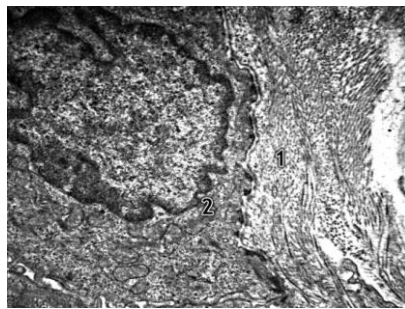


Fig. 7. Fibroblast after 42 days of opioid exposure. Photomicrograph. Coll. x6000.

- 1 - impregnation of the main substance near the fibroblast with transudate;
- 2 - inhomogeneous arrangement of fibrils of collagen fibers.

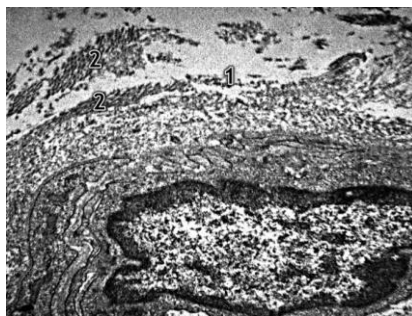


Fig. 8. Fibroblast after 42 days of opioid exposure. Photomicrograph. Coll. x6000.

- 1 - transudate around the fibroblast;
- 2 - inhomogeneous arrangement of fibrils of collagen fibers.

The main connective tissue substance, especially near dilated and erythrocyte-filled vessels, was impregnated with transudate. In such areas, the heterogeneous location and stratification of fibrils of collagen fibers, in places their fragmentation and destruction were noted. Moderate dilation of the tubules of the granular endoplasmic reticulum of fibroblasts was noted (Fig. 9, 10). The number of free ribosomes and polysomes, glycogen grains increased in the cytoplasm of fibroblasts.

Dilation and overflow of erythrocytes of vessels of own plate of a mucous membrane, was followed by development of perivascular hypostasis. There were areas where diapedesis of single erythrocytes outside the hemocapillaries was observed. In such areas, deformed

erythrocytes were localized outside the vessels, surrounded by electron-light masses of transudate (Fig. 11).

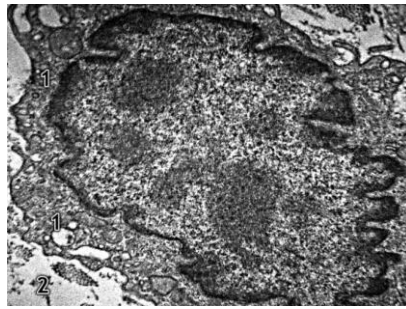


Fig. 9. Fibroblast after 42 days of opioid exposure. Photomicrograph. Coll. x6000.

- 1 - dilation of the tubules of the granular endoplasmic reticulum of the fibroblast;
- 2 - accumulation of transudate in the main substance of the connective tissue.

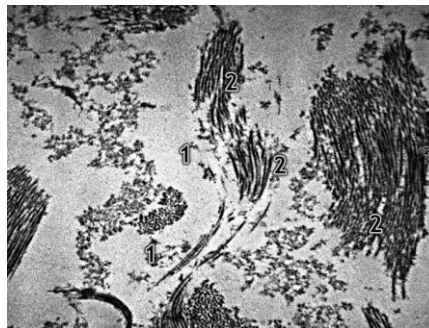


Fig. 10. Fibroblast after 42 days of opioid exposure. Photomicrograph. Coll. x6000.

- 1 - accumulation of transudate in the main substance of the connective tissue;
- 2 - fragmentation and destruction of collagen fiber fibrils.

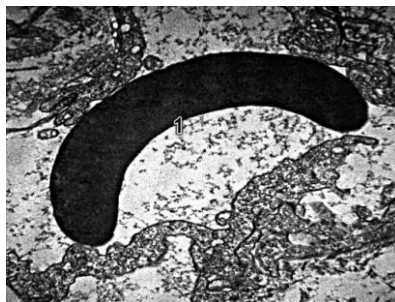


Fig. 11. Erythrocyte after 42 days of opioid exposure. Photomicrograph. Coll. x6000.

- 1 - deformed erythrocyte in the masses of transudate that accumulate in the main substance of the connective tissue.

Moderate polymorphonuclear infiltration of connective tissue by lymphocytes, neutrophils, plasma cells and single macrophages, tissue basophils was noted. The matrix of elastic cartilage was unevenly illuminated. Glycogen grains and vacuoles filled with neutral fats were visualized in the cytoplasm of chondrocytes.

As a result of 56 days of experimental material collection, the development of alternative processes in epitheliocytes of different parts of the larynx, as well as in chondrocytes, especially in elastic cartilage tissue, was revealed at the ultrastructural level in shurs who were during the two-week opioid withdrawal. Dyscirculatory processes in vessels of own plate of a mucous membrane and a submucous basis of various departments of a larynx were registered.

In particular, in the epitheliocytes of the intermediate zone of the epiglottis mucosa due to karyopyknosis, a decrease in the volume of the nuclei, their compaction and condensation of chromatin were noted. Excessive accumulation of numerous vesicles in the cytoplasm with low electron density, dilation of tubules of smooth and granular endoplasmic reticulum, enlightenment of the mitochondrial matrix were noted. Necrotic changes also developed in the columnar epitheliocytes of the subchondral mucosa. As a result of karyorexis, their nuclei disintegrated into individual wells filled with intensely condensed chromatin. Eyelashes on the apical surface of cells were destroyed, in necrotized cells there were only their remnants. Lysosomes and vesicles of various sizes accumulated in the enlightened hyaloplasm. Mitochondria swelled, their matrix brightened, cristae collapsed.

The expressed destructive changes were observed in chondrocytes of elastic cartilages. In particular, in the cytoplasm of chondrocytes volumetric numerous fatty vacuoles accumulated (Fig. 12, 13, 14,). In some chondrocytes, fat vacuoles merged to fill a significant volume of cell cytoplasm. The inhomogeneous arrangement of glycogen granules, their aggregation in peripheral areas of cytoplasm was noted. In some places, fragmentation of the cytoplasmic membrane was noted. The nucleus in such chondrocytes was compacted, reduced, and the karyoplasm was filled with intensely condensed chromatin. The cytoplasmic legs of chondrocytes were destroyed: in places they were clearly thinned, disintegrated, the pericellular matrix around the chondrocytes was clearly clarified.

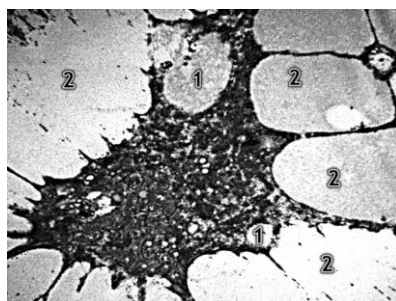


Fig. 12. Chondrocyte after 56 days of opioid exposure. Photomicrograph. Coll. x 6000.

1– volume fatty vacuoles in the cytoplasm of elastic cartilage chondrocyte;

2– pronounced enlightenment of the pericellular matrix.

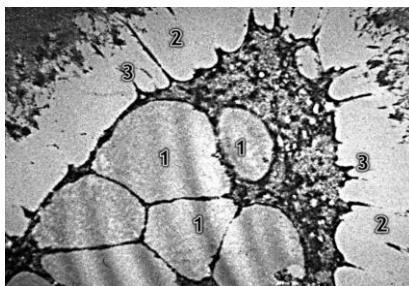


Fig. 13. Chondrocyte after 56 days of opioid exposure. Photomicrograph. Coll. x 6000.

- 1– fatty transformation of chondrocyte cytoplasm;
- 2– pronounced enlightenment of the pericellular matrix;
- 3– shortening and destruction of cytoplasmic processes of chondrocyte.




Fig. 14. Chondrocyte after 56 days of opioid exposure. Photomicrograph. Coll. x 6000.

- 1– shortening and destruction of cytoplasmic processes of chondrocyte;
- 2– fatty transformation of chondrocyte cytoplasm.

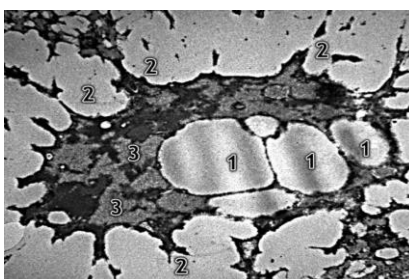


Fig. 15 Chondrocyte after 56 days of opioid exposure. Photomicrograph. Coll. x 6000.

- 1– fatty vacuoles in the cytoplasm of chondrocyte elastic cartilage;
- 2– destruction of cytoplasmic processes of chondrocyte;
- 3– enlightenment of the pericellular matrix.

Active fibroblasts were quite common. An increase in the number and inhomogeneous thickening of collagen fiber fibrils was noted. Dyscirculatory changes in the form of hyperemia and stasis, accompanied by degenerative changes of endothelial cells, development of perivascular edema were registered in the subchondral area. Erythrocyte aggregates and fine-grained masses were localized in the lumen of individual hemocapillaries. Peripheral areas of

endothelial cells contained a significant number of micropinocytic vesicles. The nuclei of endothelial cells decreased in volume, overflowed with condensed chromatin, and in some places dilated perinuclear spaces were observed.

Conclusions:

1. As a result of our research at the end of the 35th day at the ultrastructural level revealed hypersecretion of goblet cells, mucus contained impurities of lymphocytes, single neutrophils and erythrocytes. In the enlarged lumens of the hemocapillaries of the lamina propria of the mucous membrane and submucosal base of different parts of the larynx, the adhesion of erythrocytes was noted.

2. Own plate of the mucous membrane and submucosal base contained polymorphonuclear infiltrates of lymphocytes, neutrophils and macrophages. Individual fibrils of collagen fibers were fragmented. Enlightenment, edema and vacuolation of the axoplasm and deformation of the myelin sheaths were noted in the myelin nerve fibers. Necrotic changes developed in some chondrocytes of hyaline cartilages.

2. At the end of 42 days in shur, the changes were characterized by moderate damage to cytoplasmic organelles in epitheliocytes. Alternative changes developed in the chondrocytes of elastic and hyaline cartilages. Marked by an increase in the number of active fibroblasts, next to which were numerous fibrils of collagen fibers. The main substance of connective tissue, near dilated vessels, was impregnated with transudate, which was accompanied by the development of perivascular edema. Glycogen grains and vacuoles filled with neutral fats were visualized in the cytoplasm of chondrocytes.

3. At the end of 56 days in shurs with two-week withdrawal of the opioid analgesic, we found the development of alternative processes in the epitheliocytes of different parts of the larynx, as well as in chondrocytes, especially in elastic cartilage. Dyscirculatory processes in vessels of own plate of a mucous membrane and a submucous basis of various departments of a larynx were registered. Necrotic changes developed in the columnar epitheliocytes of the submucosal mucosa. Mitochondria swelled, their matrix brightened, cristae collapsed.

4. The expressed destructive changes were observed in chondrocytes of elastic cartilages. In some chondrocytes, fat vacuoles merged to fill a significant volume of cell cytoplasm. The cytoplasmic legs of chondrocytes were destroyed. Erythrocyte aggregates and fine-grained masses were localized in the lumen of individual hemocapillaries. Peripheral areas of endothelial cells contained a significant number of micropinocytic vesicles. The

nuclei of endothelial cells decreased in volume, overflowed with condensed chromatin, and in some places dilated perinuclear spaces were observed.

References

1. Davydovych OV, Kopcha VS, Masliy KO. Pain pharmacotherapy syndrome. Rational pharmacotherapy. 2011; 4 (21): 66–8.
2. Golovko AI, Leontieva LV, Golovko SI. Mechanisms of cellular tolerance to opiates and opioids. Addiction. 2003; 1: 38–48.
3. Gupta RK, Bruehl S, Burns JW, Buvanendran AM, Chont MM, Schuster EM, et al. Relationship Between Endogenous Opioid Function and Opioid Analgesis Side Effects. Reg. Anesth. Pain. Med. 2014; 39 (3): 219–24.
4. Kobelyatsky YuYU. Modern aspects of the use of a mixed agonist-antagonist of opioid receptors nalbuphine in clinical practice. Acute and urgent conditions in the doctor's practice. 2012; 1: 61–4.
5. Voronkov M, Ocheret P, Bondarenko S. Administration of nalbuphine to heroin addicts. Feasibility and short-term effects. Heroin Addict Relat Clin Probl. 2008; 10 (1): 19–24.
6. Onysko RM, Paltov EV, Fik VB, Vilkhova IV, Kryvko Yu.Ya., Yakymiv NA, Fitkalo OS, 2013 declaratory patent for invention №76564.
7. Glauert AM. Fixatson, dehydration and embedding of biologicalspecimens.-In: Practical methods in electron microscopi. Ed. by Glauert A.M.-North-Hollond (American Elsevier), 1975. 207p.
8. Stempac JG, Ward RT. An improved staining method for electron microscopy. J. Cell Biology. 1964; 22: 697-701.
9. Reynolds ES. The use of lead citrate at high pH as an electronopaque stain in tlectron microscopy. J. Cell Biology. 1963; 17: 208-212.